ISSN 1808-1851

COLUNA

Periodicidade: trimestral

Volume 17• Número 3 • Jul/Set 2018

Órgão oficial da

SOCIEDADE BRASILEIRA DE COLUNA

Sociedade Brasileira de Coluna
Sociedade Portuguesa de Patologia da Coluna Vertebral
Asociación Mexicana de Cirujanos de Columna
Capítulo de Columna de la Sociedad Ecuatoriana de Ortopedia y Traumatología
Capítulo de Columna de la Sociedad Colombiana de Ortopedia y Traumatología
Capítulo de Columna de la Sociedad Venezolana de Cirugía Ortopédica y Traumatología
Sociedad Iberolatinoamericana de Columna Vertebral
Sociedade Brasileira de Neurocirurgia
Capítulo de Columna de la Federación Latinoamericana de Sociedades de Neurocirugía
Capítulo de Columna da Sociedad Latinoamericana de Ortopedia y Traumatología
Sociedad Argentina de Patologia de la Columna Vertebral
Federação Mundial de Quiropraxia
Capítulo de Coluna do México – Columna en linea
Associação Paraguaia de Cirurgia de Coluna
Associação Cazaquistanesa de Neurocirurgiões
Associação Russa de Neurocirurgiões de Coluna Vertebral

- LAMINOPLASTY AND CORPECTOMY IN THE TREATMENT OF CERVICAL SPONDYLOTIC MYELOPATHY
- ANALYSIS OF POSTOPERATIVE OUTCOMES OF DEGENERATIVE DISEASES OF THE LUMBOSACRAL JUNCTION
- COMPLICATIONS OF SURGICAL TREATMENT OF LUMBAR STENOSIS IN THE EARLY POSTOPERATIVE PERIOD
- OUTCOMES OF SURGICAL TREATMENT OF LUMBAR DISK HERNIATION USING AN ANNULAR CLOSURE DEVICE
- SURGICAL SITE INFECTIONS IN PATIENTS AFTER POSTERIOR LUMBAR SPINE FUSION
- ADVANTAGES AND WEAKNESSES OF PERCUTANEOUS ENDOSCOPIC LUMBAR DISCECTOMY: ALGORITHM SELECTION
- CERVICAL ENDOSCOPIC DISC SURGERY: PRECISE APPROACH FOR MINIMALLY INVASIVE DECOMPRESSION
- SPINAL CORD STIMULATION FOR FAIL BACK SURGERY SYNDROME: LITERATURE REVIEW AND CLINICAL STUDY
- COMPARISON OF SURGICAL INTERVENTIONS FOR DEGENERATIVE DEFORMITIES AND INSTABILITY OF THE SPINE AMONG ELDERLY PATIENTS
- RELATIONSHIP BETWEEN PARAMETERS OF THE LUMBAR FACET JOINTS IN A LONG-TERM POSTOPERATIVE OUTCOME
- THE IMPORTANCE OF PSYCHOLOGICAL TESTING IN PREDICTING THE EFFECTIVENESS OF LUMBAR SPINE SURGERY
- RENAL CELL CARCINOMA METASTASIS OF THE SPINE: BLEEDING CONTROL METHODS
- ENERGY SUPPLY AND DEMAND IN THE INTERVERTEBRAL DISC
- SURGICAL TREATMENT OF LUMBAR DISC HERNIATION IN PREGNANT WOMEN: REPORT OF TWO CASES AND A SYSTEMATIC REVIEW

4Life Healthcare Innovation

PRODUTO EXCLUSIVO

EUROSPINE



A2L®

CAGE ALIF EM PEEK COM TRAVA DUPLA ANTERIOR E POSTERIOR. EVITA MIGRAÇÃO PRIMÁRIA E SECUNDÁRIA

CARACTERÍSTICAS

O Cage lombar ALIF em PEEK apresenta tamanhos adequados para adaptar-se a altura vertebral, com dupla trava (anterior e posterior). A trava assegura contra o risco de migração primária, secundária e a área de contato gera maior suporte e facilita a osteointegração. Proporciona ao cirurgião acompanhamento da consolidação óssea por ser radiotransparente.

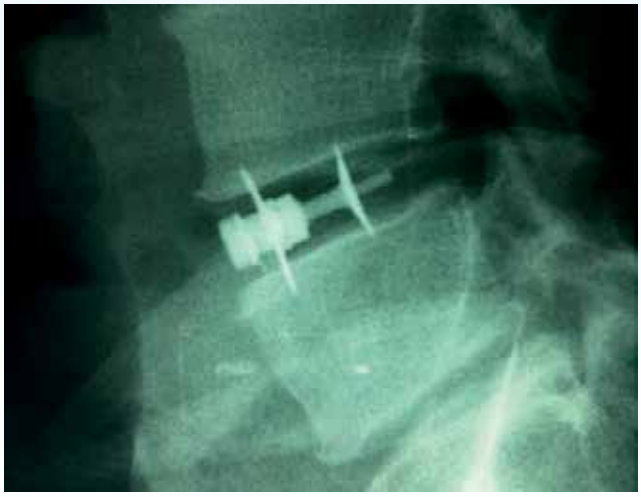

Imagem de colocação de Stand-alone

São Paulo 11 3044 1433
Brasília 61 3577 9999

acesse nosso site:
www.fusao.com

FUSAO Soluções para Medicina

SISTEMA SACROILÍACO / SACROILIAC SYSTEM

SISTEMA SACROILÍACO
VIA POSTERIOR



REGISTRO ANVISA Nº 80078450021

Compatibilidade com o Sistema Pedicular TLS
Compatibility with TLS Pedicular System

INSTRUMENTAIS / INSTRUMENTS



www.ossea.com.br

ÓSSEA
MEDICAL TECHNOLOGY

AOSPINE
LATIN AMERICA

60 YEARS | AO Foundation
Transforming surgery, changing lives

Simpósio Avançado AOSpine Pré-Congresso SBC— Soluções AOSpine em casos complexos & Complicações: Como evitar e tratar

01 de Maio, 2019 . São Paulo, Brasil

Participe do simpósio da AOSpine que acontecerá durante o XVII Congresso Brasileiro de Coluna. O programa é baseado em casos clínicos difíceis e complicações em cada segmento anatômico: **occipitocervical, coluna cervical sub-axial, transição cervicotorácica, coluna toracolumbar e sacral**. Todos os casos foram cuidadosamente selecionados para gerar maior discussão e serão complementados com take home messages. A programação também terá **guest lectures** preparadas pelos palestrantes internacionais.

CO-CHAIRPERSONS



Asdrubal Falavigna
Caxias do Sul



Luiz Vialle
Curitiba

FACULTY INTERNACIONAL

+ FACULTY NACIONAL



Jean Ouellet
Montreal



Richard Bransford
Seattle

Inscreva-se agora: www.cbc2019.com.br

LOCAL:

WTC Events Center
Av. das Nações Unidas, 12551.
Brooklin Novo, São Paulo - SP

Em colaboração com
SBC Sociedade Brasileira de Coluna

AOSpine Contact: Luana Torres | ltorres@aospine.org | T (41) 3016 4491

Estaremos com um espaço AOSpine durante o XVII Congresso Brasileiro de Coluna, de 02 a 04 de Maio de 2019.

Aproveite a oportunidade para fazer ou renovar sua membresia e esclarecer eventuais dúvidas. Esperamos sua visita!



COLUNA/COLUMNA

Coluna/Columna v17, n1 Jan/Mar 2018

ISSN 1808-1851

Indexada nas Bases de Dados SCIELO, SCOPUS e LILACS (Literatura Latino-Americana e do Caribe em Ciências da Saúde)

Filiada à Associação Brasileira de Editores Científicos

Editor Científico

Helton L.A. Defino, Faculdade de Medicina de Ribeirão Preto, Universidade de São Paulo (Ribeirão Preto, SP, Brasil)

Editor Executivo

Sérgio Daher, Hospital das Clínicas da Faculdade de Medicina da UFG (Goiânia, GO, Brasil).

Editores Associados

Alvaro Dawling, Instituto de Ensino e Pesquisa CK, (São Paulo, SP, Brasil); CK Internacional, (Santiago,Chile); Clinica Kennedy, (Santiago/Chile).
Byvaltsev Vadim, Irkutsk Scientific Center of Surgery and Traumatology (Irkutsk Russia)
Eduardo Barros Puertas, Universidade Federal de São Paulo (São Paulo, SP, Brasil)
Ivan Ferrareto, Universidade Federal de São Paulo (Ribeirão Preto, SP, Brasil)
José María Jiménez Avila, Centro Médico Nacional de Occidente. IMSS. TEC de Monterrey campus Guadalajara. Facultad de Medicina (Guadalajara, Jalisco, México)
Kolesov Sergey, Priorov N.N Central Institute of Traumatology and Orthopaedics (Moscow. Russia)
Mauro dos Santos Volpi, Universidade Estadual Paulista Júlio de Mesquita Filho (Botucatu, SP, Brasil)
Osmar Avanzi, Faculdade de Ciências Médicas da Santa Casa de São Paulo (São Paulo, SP, Brasil)
Sérgio Zylbersztejn, Universidade Federal de Ciências da Saúde de Porto Alegre (Porto Alegre, RS, Brasil)
Tarcisio Eloy Pessoa de Barros Filho, Instituto de Ortopedia e Traumatologia do HC/FMUSP (São Paulo, SP, Brasil)

Conselho Editorial

Akshulakov Serik (Astana,Cazaquistão)
Albert Vincent Berthier Brasil, Santa Casa Porto Alegre (Porto Alegre, RS,Brasil)
Aleinikov Viktor, National Center for Neurosurgery (Astana,Cazaquistão)
Andres Edgar Rodriguez Fuentes, Univ. de São Paulo (Ribeirão Preto, SP, Brasil)
Andres Rodriguez Munera, Fundacion Sta Fé de Bogotá (Bogotá, Colombia)
Asdrubal Falavigna, Universidade de Caxias do Sul, (Caxias do Sul, RS, Brasil).
Asdrúbal Silveri, Centro de Deformidades de Columna (Montevidéo, Uruguai)
Bartolomé Marré, Hosp. Trabajador Santiago (Santiago, Chile)
Carlos Eduardo Algaves Soares de Oliveira, Hospital do Servidor (São Paulo, SP, Brasil)
Carlos Henrique Maçaneiro, Univ. da Região Joinville (Joinville, SC, Brasil)
Carlos Henrique Ribeiro, Hospital Quinta D'or (Rio de Janeiro, RJ, Brasil)
Carlos Umberto Pereira, Univ. Federal de Sergipe (Aracaju, SE, Brasil)
Carlos Tello, Sociedad Ibero Latinoamericana de Columna (Buenos Aires, Argentina)
Carlos Villanueva Leal, Vall D'Hebron Hosp. Traumatologia Rehabilitación (Barcelona, Espanha)
Carolina Kolberg, Federación Latino Americana de Quiropráctica (Brasilia, DF, Brasil)
Délio Eulálio Martins, Univ. Federal de São Paulo (São Paulo, SP, Brasil)
Elcio Landim, Univ. Estadual de Campinas (Campinas, SP, Brasil)
Enguer Beraldo Garcia, Santa Casa de Belo Horizonte (Belo Horizonte, MG, Brasil)
Enrique Izquierdo Nuñez, Univ. Complutense de Madrid (Madri, Espanha)
Enrique Jimenez Hakim, Fundacion Santa Fé de Bogotá (Bogotá, Colombia)
Enrique Osorio Fonseca, Univ. El Bosque Bogotá (Bogotá, Colômbia)
Ernesto Bersusky, Hosp. Nacional de Pediatria Juan P. Garrahan (Buenos Aires, Argentina)
Erasmo de Abreu Zardo, Pontifícia Univ. Católica (Porto Alegre, RS, Brasil)
Fernando Antonio Mendes Façanha Filho, Univ. Federal do Ceará (Fortaleza, CE, Brasil)
Fernando Helo Yamhure, Clínica Reina Sofia (Bogota, Colombia)
Francisco Limeira dos Santos Neto, Univ. Federal de Pernambuco (Recife, PE, Brasil)
Francisco Javier Sánchez Pérez-Grueso, Hosp. La Paz (Madri, Espanha)
Gabriel Virgilio Ortiz García, Centro Médico Puerta de Hierro (Zapopan, Jalisco, México)
Geraldo de Sá Carneiro Filho, Hosp. da Restauração (Recife, PE, Brasil)
Gushcha Artem, Research center of Neurology Volokolamskoe (Moscow Russia)
Guy Broch Haro, Issste Hospital Lopez Mateos (México, Distrito Federal)
Herman Michael Dittmar Johnson, Centro Médico Puerta de Hierro (Zapopan, Jalisco, México), Universidad de Guadalajara (Guadalajara, México)
Jorge Felipe Ramirez, Clínica Reina Sofia (Bogotá-Colombia)
Jorge Manuel A. Draper Mineiro, Hosp. Cuf Descobertas (Lisboa, Portugal)
José Castro Guimarães Consciência, Hosp. de Egas Moniz (Lisboa, Portugal)
José Gabriel Rugeles Ortiz, Cecimin Organizacion Sanitas (Bogota, Colombia)
Juan Silva, Univ. Nacional de Asuncion (Assunção, Paraguai)
Karen Weissman (Clínica Fundácion Médica San Cristóbal, Santiago, Chile)
Kerimbayev Talgat, National Center for Neurosurgery (Astana,Cazaquistão)
Luciano Miller Reis Rodrigues, Faculdade de Medicina do ABC (Santo André, SP, Brasil)
Luis Carlos Ramíres, Instituto de Seguros Sociales (Bogotá,Colombia)
Luis Eduardo Munhoz da Rocha, Hosp. Pequeno Príncipe (Curitiba, PR, Brasil)
Luiz Roberto Gomes Vialle, Pontifícia Univ. Católica (Curitiba, PR, Brasil)
Marcelo Gruenberg, Hosp. Italiano de Buenos Aires (Buenos Aires, Argentina)
Marcelo Wajchenberg, Univ. Federal de São Paulo (São Paulo-SP-Brasil)
Marcello H. Nogueira-Barbosa, Univ. de São Paulo (Ribeirão Preto, SP, Brasil)
Marcos Masini, Univ. Planalto Central (Brasília, DF, Brasil)
Mario Augusto Taricco, Univ. de São Paulo (São Paulo, SP, Brasil)
Mario Herrera (Bogotá-Colombia)
Mauricio Pagy de Calais Oliveira, Centro Mineiro de Cirurgia da Coluna (Belo Horizonte, Brasil)
Mihailovsky Michai, Cuvyan Institute of Traumatology and Orthopaedics (Novosibirsk, Russia)
Murilo Tavares Daher, Departamento de Ortopedia da Universidade Federal de Goiás (Goiânia, GO, Brasil)
Néstor Fiore, Hosp. de La Plata (Buenos Aires, Argentina)
Nicolás J. Macchiavello Cornejo, Hospital Clínico de la Universidad de Chile (Santiago, Chile)
Óscar Luís Alves, Hospital Lusíadas Porto e Centro Hospitalar Vila Nova de Gaia/Espinho EPE (Porto, Portugal)
Ptashnikov Dmitriy, Institute of Traumatology and Orthopaedics (St Petersburg, Russia)
Renato Tavares Daher, Centro de Reabilitação e Readptação Dr. Henrique Santillo (Goiânia, Goiás)
Roberto Chapa Sosa, Hosp. de Alta Especialidad Christus Muguerza (Monterrey, Nuevo Leon, México)
Roberto Sakamoto Falcon, Hospital Ortopédico-Lifecenter (Belo Horizonte, MG, Brasil)
Rodrigo Amaral, Instituto de Patologia da Coluna – IPC (Sao Paulo, SP, Brasil)
Ruy Vaz, Hosp. de São João (Porto, Portugal)
Sérgio Afonso Hennemann, Hosp. Mãe de Deus (Porto Alegre, RS, Brasil)
Victor Paul Miramontes, CNR/O-Centro Nacional de Rehabilitación (Cidade do México, México)
Washington Bermúdez Santos, Montevideo Spine Center (Montevideo, Uruguai)
Xavier Soler I Graells, Univ. Federal do Paraná (Curitiba, PR, Brasil)

Correspondentes Estrangeiros

Jack Zigler, Texas Back Institute (Dallas, Texas, USA)
Marek Szpalski, Hôpitaux Iris Sud (Bruxelles, Belgica)
Robert Gunzburg, Belgium and Eeuwfeest Kliniek (Antwerpen, Belgica)
Steven R. Garfin (San Diego, CA, Estados Unidos)

Editor Consultivo

Arthur Tadeu de Assis - São Paulo - SP - Brasil

Editora Gerente

Flávia M. S. Pires - São Paulo - SP - Brasil

Coluna/Columna é uma Publicação Oficial Sociedade Brasileira de Coluna e das Sociedades afiliadas: Asociación Mexicana de Cirujanos de Columna – AMCICO; Associação Paraguaia de Cirurgia de Coluna; Associação Cazaquistanesa de Neurocirurgiões; Associação Russa de Neurocirurgiões de Coluna Vertebral; Capítulo de Columna de la Federación Latinoamericana de Sociedades de Neurocirugía – FLANC; Capítulo de Columna de la Sociedad Ecuatoriana de Ortopedia y Traumatologia - SEOT; Capítulo de Columna de la Sociedad Colombiana de Ortopedia y Traumatología – SCCOT; Capítulo de Columna da Sociedad Latinoamericana de Ortopedia y Traumatología – SLAOT; Capítulo de Columna de la Sociedad Venezolana de Cirugía Ortopédica y Traumatologia – SVCOT; Capítulo de Coluna do México- Columna en linea; Federação Mundial de Quiropraxia (WFC); Sociedad Argentina de Patologia de la Columna Vertebral – SAPCV; Sociedad Iberolatinoamericana de Columna Vertebral – SILACO; Sociedade Brasileira de Neurocirurgia – SBN; ; Sociedade Portuguesa de Patologia da Coluna Vertebral – SPPCV.

Atha Comunicação e Editora: Coordenação editorial, criação, diagramação e produção gráfica
Rua Machado Bittencourt, 190 - 4° andar - conj. 410 - CEP: 04044-903 - São Paulo - SP
Tel/Fax: (11) 5087-9502/5579-5308 - 1atha@uol.com.br

Órgão oficial da Sociedade Brasileira de Coluna

Al. Lorena, 1304, 14°, cj. 1406/07
Jd. Paulista - São Paulo - SP - Brasil
Cep: 01424-001 - Tel.: 11 3088-6615

Secretária Administrativa: Ana Maria Cella - coluna@coluna.com.br

• Periodicidade: Trimestral

Informações: coluna.columna@uol.com.br

Visite o site da Sociedade Brasileira de Coluna
portalsbc.org

Revista disponível eletronicamente
www.revistacoluna.org

Editorial

Dear readers of Coluna / Columna Journal

As the President of the Russian Association of Spine Surgeons, I am very proud to present the best papers from Russian spine specialists, which provide a view of the level of spine surgery in Russia.

The Russian Association of Spine Surgery is a multidisciplinary medical organization dedicated to providing the highest quality, evidenced-based and ethical spine care by promoting education, research and advocacy. RASS has over 400 members from several disciplines, including orthopedic surgery, neurosurgery, research and rehabilitation.

We are delighted to be working with BRICS Spine, which was created in RIO in 2017, and we are planning to develop BRICS Spine II in Moscow in 2019. We look forward to engaging more spine specialists than ever before with our concise reviews of cutting-edge research, commentaries from key opinion leaders and updates from the medical device area.

The publications by the Russian Spine Surgeons in this issue have really developed over the past several years, with the Association having truly become a trusted, independent source of news and views for people working in spine research and clinical evidence-based practice. The writing is top-notch and the physician descriptions are as interesting to read as they are informative. That is why several papers describe the modern (including minimally invasive) approaches to treatment of degenerative spine diseases. We discuss our experience with surgical treatment of spine tumors. Several unusual clinical cases are also described. We look forward to a long and meaningful collaboration with Coluna Columna Journal.

As the thematic platform for international spine surgery collaboration, we suggest focusing on the concept and reality of “Building Bridges.” In this era of increased competition for resources for health care expenditures and the aggressive pursuit of value-based health care decision- and policy-making, it is imperative that we link our spine care communities for the purpose of transmitting information, informing personnel and, ultimately, strengthening ourselves.. Since 2017, major bridges were and are still being built between professional societies focused on spine care.

Professor Artem Gushcha, Dr. Sci.

COLUNA/COLUMNA

VOLUME 17 - Nº 3 - 2018 - Contents/Sumário/Contenido

Original Articles/*Artigos Originais/Artículos Originales*

CERVICAL SPINE/*COLUNA CERVICAL/COLUMNA CERVICAL*

LAMINOPLASTY AND CORPECTOMY IN THE TREATMENT OF CERVICAL SPONDYLOTIC MYELOPATHY.....174
LAMINOPLASTIA E CORPORECTOMIA NO TRATAMENTO DA MIELOPATIA ESPONDICOLÓGICA CERVICAL
LAMINOPLASTIA Y CORPECTOMÍA EN EL TRATAMIENTO DE LA MIELOPATÍA ESPONDILÓTICA CERVICAL
Dreval' Maxim Dmitrievich, Arestov Sergey Olegovich, Petrosyan David Vazgenovich, Kashcheev Alexey Alexeevich, Vershinin Andrey Vyacheslavovich, Poltorako Ekaterina Nikolaevna, Gushcha Artem Olegovich
*http://dx.doi.org/10.1590/S1808-18512018170319325*8

DEGENERATIVE DISC DISEASE/*DOENÇAS DEGENERATIVA INTERVERTEBRAL/ENFERMEDAD DEGENERATIVA*

ANALYSIS OF POSTOPERATIVE OUTCOMES OF DEGENERATIVE DISEASES OF THE LUMBOSACRAL JUNCTION.....180
ANÁLISE DOS RESULTADOS PÓS-OPERATÓRIOS DO DEGENERADOR DA JUNÇÃO LOMBOSSACRAL
ANÁLISIS DE LOS RESULTADOS POSTOPERATORIOS DE LAS ENFERMEDADES DEGENERATIVAS DE LA UNIÓN LUMBOSACRA
Vadim Anatol'evich Byvaltsev, Andrei Andreevich Kalinin, Yuri Yakovlevich Pestryakov, Samuil Semenovich Rabinovith, Marat Amangeldyevich Aliyev, Svetlana Victorovna Shvetsova
*http://dx.doi.org/10.1590/S1808-18512018170319383*8

COMPLICATIONS OF SURGICAL TREATMENT OF LUMBAR STENOSIS IN THE EARLY POSTOPERATIVE PERIOD.....185
COMPLICAÇÕES DO TRATAMENTO CIRÚRGICO DA ESTENOSE LOMBAR NO PERÍODO PÓS-OPERATÓRIO IMEDIATO
COMPLICACIONES DEL TRATAMIENTO QUIRÚRGICO DE LA ESTENOSIS LUMBAR EN EL PERÍODO POSTOPERATORIO TEMPRANO
Igor Vadimovich Basankin, Vladimir Alexeevich Porkhanov, Asker Alievich Afaunov, Alexander Veniaminovich Kuzmenko, Vladimir Konstantinovich Shapovalov
*http://dx.doi.org/10.1590/S1808-18512018170320048*7

OUTCOMES OF SURGICAL TREATMENT OF LUMBAR DISK HERNIATION USING AN ANNULAR CLOSURE DEVICE.....188
DESFECHOS DO TRATAMENTO CIRÚRGICO DA HÉRNIA DE DISCO LOMBAR COM APARELHO DE FECHAMENTO ANULAR
RESULTADOS DEL TRATAMIENTO QUIRÚRGICO DE LA HERNIA DE DISCO LUMBAR UTILIZANDO UN DISPOSITIVO DE CIERRE ANULAR
Sanginov Abdugafur Jabborovich, Krutko Aleksandr Vladimirovich, Baykov Evgenii Sergeevich, Lutsik Anatoliy Andreevich
*http://dx.doi.org/10.1590/S1808-18512018170319383*2

INFECTOLOGY/*INFECTOLOGIA/INFECTOLOGÍA*

SURGICAL SITE INFECTIONS IN PATIENTS AFTER POSTERIOR LUMBAR SPINE FUSION 195
INFECÇÕES NO LOCAL CIRÚRGICO EM PACIENTES APÓS A FUSÃO POSTERIOR DA LOMBAR
INFECCIONES DEL SITIO QUIRÚRGICO EN PACIENTES DESPUÉS DE LA FUSIÓN LUMBAR POSTERIOR
Vadim Anatol'evich Byvaltsev, Ivan Andreevich Stepanov, Vladislav Eduardovich Borisov, Medetbek Djumabekovich Abakirov
*http://dx.doi.org/10.1590/S1808-18512018170319383*9

MINIMALLY INVASIVE SURGERY/*CIRURGIA MINIMAMENTE INVASIVA/CIRUGÍA MINIMAMENTE INVASIVA*

ADVANTAGES AND WEAKNESSES OF PERCUTANEOUS ENDOSCOPIC LUMBAR DISCECTOMY: ALGORITHM SELECTION 200
VANTAGENS E FRAQUEZAS DA DISCECTOMIA LOMBAR ENDOSCÓPICA PERCUTÂNEA: SELEÇÕES DE ALGORITMO
VENTAJAS Y DEBILIDADES DE LA DISCECTOMÍA LUMBAR ENDOSCÓPICA PERCUTÁNEA: SELECCIÓN DE ALGORITMO
Artem Gushcha, Andrey Vershinin, Sergey Arestov, Alexey Kashcheev, Vladimir Tjurnikov, Maksim Dreval, Ekateryna Poltoraco, David Petrosyan
*http://dx.doi.org/10.1590/S1808-18512018170319183*9

CERVICAL ENDOSCOPIC DISC SURGERY: PRECISE APPROACH FOR MINIMALLY INVASIVE DECOMPRESSION.....206
CIRURGIA DO DISCO ENDOSCÓPICO CERVICAL: ABORDAGEM PRECISA PARA DESCOMPRESSÃO MINIMAMENTE INVASIVA
CIRUGÍA DE DISCO CERVICAL ENDOSCÓPICA: ENFOQUE PRECISO PARA LA DESCOMPRESIÓN MÍNIMAMENTE INVASIVA
Artem Gushcha, Sergey Arestov, Andrey Vershinin, Alexey Kashcheev, Vladimir Tjurnikov, Maksim Dreval, Ekateryna Poltoraco, David Petrosyan
*http://dx.doi.org/10.1590/S1808-18512018170319184*0

PAIN/*DOR/DOLOR*

SPINAL CORD STIMULATION FOR FAIL BACK SURGERY SYNDROME: LITERATURE REVIEW AND CLINICAL STUDY.....212
ESTIMULACIÓN DE LA MÉDULA ESPINAL PARA EL SÍNDROME DE CIRUGÍA DE ESPALDA FALLIDA: REVISIÓN DE LA LITERATURA Y ESTUDIO CLÍNICO
ESTIMULAÇÃO DA MEDULA ESPINHAL PARA SÍNDROME DE CIRURGIA DE RETORNO: REVISÃO DA LITERATURA E ESTUDO CLÍNICO
Kashcheev Alexey Alexeevich, Gushcha Artem Olegovich, Tjurnikov Vladimir Mikhaylovich, Arestov Sergey Olegovich, Vershinin Andrey Vyacheslavovich, Dreval' Maxim Dmitrievich, Poltorako Ekaterina Nikolaevna, Petrosyan David Vazgenovich
http://dx.doi.org/10.1590/S1808-185120181703193251

SURGICAL CAR/*CUIDADOS CIRURGICOS/CUIDADO QUIRÚRGICO*

COMPARISON OF SURGICAL INTERVENTIONS FOR DEGENERATIVE DEFORMITIES AND INSTABILITY OF THE SPINE AMONG ELDERLY PATIENTS.....216
A COMPARAÇÃO DE INTERVENÇÕES CIRÚRGICAS PARA PACIENTES IDOSOS COM DEFORMAÇÕES DEGENERATIVAS E INSTABILIDADE DA COLUNA VERTEBRAL
COMPARACIÓN DE INTERVENCIONES QUIRÚRGICAS PARA PACIENTES ANCIANOS CON DEFORMACIONES DEGENERATIVAS E INESTABILIDAD DE LA COLUMNA VERTEBRAL
Dmitrii Mikhaylov, Anton Denisov, Dmitrii Ptashnikov, Sergei Masevnin, Nikita Zaborovskii
http://dx.doi.org/10.1590/S1808-185120181703193268

RELATIONSHIP BETWEEN PARAMETERS OF THE LUMBAR FACET JOINTS IN A LONG-TERM POSTOPERATIVE OUTCOME.....221
RELAÇÃO ENTRE PARÂMETROS DAS LIGAÇÕES DA FACETA LOMBAR EM UM RESULTADO PÓS-OPERATÓRIO DE LONGO PRAZO
RELACIÓN ENTRE PARÁMETROS DE LAS ARTICULACIONES FACETARIAS LUMBARES EN RESULTADO POSTOPERATORIO A LARGO PLAZO
Vadim Anatol'evich Byvaltsev, Andrei Andreevich Kalinin, Alyona Konstantinovna Okoneshnikova, Yuri Yakovlevich Pestryakov, Igor Vadimovich Basankin
http://dx.doi.org/10.1590/S1808-185120181703193840

THE IMPORTANCE OF PSYCHOLOGICAL TESTING IN PREDICTING THE EFFECTIVENESS OF LUMBAR SPINE SURGERY.....227
A IMPORTÂNCIA DO TESTE PSICOLÓGICO NA PREVISÃO DA EFICÁCIA DA CIRURGIA DA COLUNA LOMBAR
LA IMPORTANCIA DE LAS PRUEBAS PSICOLÓGICAS EN LA PREDICCIÓN DE LA EFECTIVIDAD DE LA CIRUGÍA DE LA COLUMNA LUMBAR
Aleksandr V. Krutko, Olga N. Leonova, Eugene A. Cherepanov
http://dx.doi.org/10.1590/S1808-185120181703193836

TUMOR AND MEDICAL ONCOLOGU/*TUMOR E ONCOLOGIA/TUMOR Y ONCOLOGÍA MÉDICA*

RENAL CELL CARCINOMA METASTASIS OF THE SPINE: BLEEDING CONTROL METHODS.....233
METÁSTASE DE CARCINOMA DE CÉLULAS RENAIS DA COLUNA VERTEBRAL: MÉTODOS DE CONTROLE DE SANGRAMENTO
METÁSTASIS ESPINAL DE CARCINOMA DE CÉLULAS RENALES: MÉTODOS DE CONTROL DE SANGRADO
Nikita Zaborovskii, Dmitrii Ptashnikov, Dmitrii Mikaylov, Sergei Masevnin, Oleg Smekalenkov
http://dx.doi.org/10.1590/S1808-185120181703193262

Revision Article/*Artigo de Revisão/Artículo de Revisión*

DEGENERATIVE DISC DISEASE/*DOENÇAS DEGENERATIVA INTERVERTEBRAL/ENFERMEDAD DEGENERATIVA*

ENERGY SUPPLY AND DEMAND IN THE INTERVERTEBRAL DISC.....237
FORNECIMENTO E DEMANDA DE ENERGIA NO DISCO INTERVERTEBRAL
SUMINISTRO DE ENERGÍA Y DEMANDA EN EL DISCO INTERVERTEBRAL
Liudmila Andreevna Bardonova, Omar Sheikh, Irina Olegovna Malova, Vladimir Alexeevich Sorokovikov, Vadim Anatolyevich Byvaltsev
http://dx.doi.org/10.1590/S1808-185120181703193837

SURGICAL TREATMENT OF LUMBAR DISC HERNIATION IN PREGNANT WOMEN: REPORT OF TWO CASES AND A SYSTEMATIC REVIEW.....240
TRATAMENTO CIRÚRGICO DA HÉRNIA DE DISCO LOMBAR EM GESTANTES: RELATO DE DOIS CASOS E REVISÃO SISTEMÁTICA
TRATAMIENTO QUIRÚRGICO DE LA HERNIA DISCAL LUMBAR EN EMBARAZADAS: INFORME DE DOIS CASOS Y REVISIÓN SISTEMÁTICA
Ialeksandr Vladimirovich Krutko, Abdugafur Jabborovich Sanginov, Aleksey Vladimirovich Peleganchuk, Alina Anatolevna Alshevskaya, Andrei Vladimirovich Moskalev, Vadim Anatolevich Byvaltsev
http://dx.doi.org/10.1590/S1808-185120181703193835

ISSN 1808-1851

INSTRUÇÕES AOS AUTORES/NORMAS PARA PUBLICAÇÃO

Revisado em janeiro de 2018

COLUNA/COLUMNA – ISSN 1808-1851 (versão impressa) e ISSN 2177-014X (versão ***on-line***) – é o órgão de publicação científica oficial da Sociedade Brasileira de Coluna – SBC e de associações afiliadas: Asociación Mexicana de Cirujanos de Columna – AMCICO; Asociación Paraguaya de Cirugía de Columna; Capítulo de Columna de la Federación Latinoamericana de Sociedades de Neurocirugía – FLANC; Capítulo de Columna de la Sociedad Ecuatoriana de Ortopedia y Traumatología – SEOT; Capítulo de Columna de la Sociedad Colombiana de Ortopedia y Traumatología – SCCOT; Capítulo de Columna de la Sociedad Latinoamericana de Ortopedia y Traumatología – SLAOT; Capítulo de Columna de la Sociedad Venezolana de Cirugía Ortopédica y Traumatología – SVCOT; Capítulo de Coluna do México – Columna en línea; Federação Mundial de Quiropraxia – WFC; Sociedad Argentina de Patología de la Columna Vertebral – SAPCV; Sociedad Iberolatinoamericana de Columna Vertebral – SILACO; Sociedade Brasileira de Neurocirurgia – SBN; Sociedade Portuguesa de Patologia da Coluna Vertebral – SPPCV. É publicada em duas versões, trimestralmente, em quatro edições ao ano. Sua proposta é divulgar artigos que contribuam para o aperfeiçoamento e o desenvolvimento da prática, da pesquisa e do ensino dos temas relacionados a coluna vertebral no Brasil e na América Latina.

ESCOPO E POLÍTICA

A Revista COLUNA/COLUMNA é uma revista de acesso aberto, que publica contribuições da comunidade científica nacional e internacional, na forma de artigos originais com elevado mérito científico (artigos de revisão, revisões sistemática, artigos de atualização). Seu objetivo é divulgar artigos que contribuam para o aperfeiçoamento e o desenvolvimento da prática, da pesquisa e do ensino dos temas relacionados à Coluna Vertebral, Patologias da Coluna Vertebral, Ortopedia e Traumatologia, Reabilitação e áreas afins.

A Coluna/Columna publica, preferencialmente, artigos originais de interesse internacional, e não apenas os de relevância regional. O Corpo Editorial é composto por membros nacionais e internacionais, que trabalham gratuitamente para aprimorar a qualidade do periódico, visando torná-la atraente não só para a pesquisa regional/nacional mas também para a comunidade científica internacional.

É publicada em duas versões, trimestralmente em 4 edições ao ano (Março, Junho, Setembro e Dezembro). Sua proposta é divulgar artigos que contribuam para o aperfeiçoamento e o desenvolvimento da prática, da pesquisa e do ensino dos temas relacionados à Coluna Vertebral.

Não há taxa para artigos de submissão e avaliação.

PREPARAÇÃO DO MANUSCRITO

Peer Review

O *peer review*, ou revisão por pares, é um dos fatores que sustentam a qualidade de um veículo científico. O corpo editorial da Coluna/Columna é formado, em sua maioria, por professores universitários, que permite um *peer review* criterioso e rigoroso. Todos os manuscritos, após aprovação dos editores, serão analisados por dois ou mais revisores, sendo o anonimato garantido em todo o processo de julgamento (duplo cego). Os artigos que não apresentarem mérito e não se enquadrarem na política editorial da revista serão rejeitados não cabendo recurso. Os comentários dos revisores serão devolvidos aos autores para modificações no texto ou justificativa de sua conservação. Somente após as aprovações finais, os manuscritos serão encaminhados para publicação.

Copyright

As declarações publicadas nos artigos são de inteira responsabilidade dos autores. Entretanto, todo material publicado se torna propriedade da Revista Coluna/Columna, que passa a reservar os direitos autorais. Os autores devem anexar como documento suplementar no sistema Scielo de publicação e submissão *on line*: a) Declaração de Conflito de Interesses; b) Certificado de Aprovação do Trabalho pela Comissão de Ética em Pesquisa da Instituição quando a investigação envolver experimentação em seres humanos ou animais; c) Documentação referente as eventuais fontes de financiamento do trabalho; d) Declaração de que os participantes assinaram documento de Consentimento Livre Informado, quando se tratar de pesquisa clínica com seres humanos; e) Carta de transferência dos direitos autorais assinada por todos os autores e declaração de que é inédito, não tendo sido submetido à publicação em outro periódico ou livro.

APRESENTAÇÃO E SUBMISSÃO DO MANUSCRITO

A Revista Coluna/Columna - é uma publicação trimestral que circula nos meses de janeiro/fevereiro/março, abril/maio/junho, julho/agosto/setembro, outubro/novembro/dezembro, em duas versões uma com os textos em seu idioma original (português, inglês ou espanhol) e outra versão em inglês, com a finalidade de publicar trabalhos originais da especialidade. Os conceitos e declarações contidos nos trabalhos são de total responsabilidade dos autores. Os artigos publicados na revista seguem os requisitos uniformes propostos pelo Comitê Internacional de Editores de Revistas Médicas, disponíveis no endereço eletrônico www.icmje.org.

A revista Coluna/Columna, em apoio às políticas para registro de ensaios clínicos da Organização Mundial de Saúde (OMS) e do *International Committee of Medical Journal Editors* (ICMJE), reconhecendo a importância dessas iniciativas para o registro e divulgação internacional de informação sobre estudos clínicos, em acesso aberto, somente aceitará para publicação a partir de agosto de 2009 os artigos de pesquisas clínicas que tenham recebido um número de identificação em um dos Registros de Ensaios Clínicos validados pelos critérios estabelecidos pela OMS e ICMJE, disponível no endereço: http://clinicaltrials.gov ou no site do Pubmed https://www.ncbi.nlm.nih.gov/pubmed.

Ao relatar experimentos sobre temas humanos e animais, indicar se os procedimentos seguiram as normas do Comitê Ético sobre Experiências Humanas da Instituição, na qual a pesquisa foi realizada ou de acordo com a declaração de Helsinki de 1995 e *Animal Experimentation Ethics,* respectivamente. Os autores devem incluir uma declaração indicando que o protocolo foi aprovado pelo Comitê de Ética da Instituição (Instituição de afiliação de pelo menos um dos autores) com o respectivo número de identificação. Também deve incluir que o Termo de Consentimento Livre e Esclarecido foi assinado por todos os participantes. Essas informações devem ser citadas na seção Material e Métodos do manuscrito.

A revista recebe para publicação artigos para as seguintes seções: Artigos Originais, Artigo de Revisão, Artigo de Atualização e Relato de Caso. Os artigos poderão ser escritos em Português, Espanhol ou Inglês. Os trabalhos deverão ser digitados em espaço duplo, usando, de preferência, o processador de texto Microsoft Word, com 3 cm de margens e a fonte Times New Roman, tamanho 12, não devendo ultrapassar de 20 páginas, incluindo folha de rosto, resumos, texto, agradecimentos, referências e tabelas. Arquivos em formato PDF não serão aceitos.

O artigo enviado deverá ser submetido, acompanhado de:

Folha de rosto: título do trabalho (conciso e informativo), em português, espanhol e inglês; o nome completo de cada autor (sem abreviações); e a instituição (As unidades hierárquicas devem ser apresentadas em ordem decrescente, por exemplo, universidade, faculdade e departamento; a que pertence cada um deles (Os nomes das instituições e programas deverão ser apresentados preferencialmente por extenso e na língua original da instituição ou na versão em inglês quando a escrita não é latina [p.ex. árabe, mandarim, grega]); com indicação numérica e sequencial, utilizando números arábicos sobrescritos. Se houver mais de uma afiliação institucional, indicar apenas a mais relevante; local de realização do trabalho e/ou da pesquisa; nome do autor correspondente com endereço completo, telefone, e-mail. O número ORCID de cada um dos autores deve ser informado na folha de rosto. http://orcid.org/

Resumo e Descritores: resumo, em português, inglês e espanhol com, no máximo 250 palavras. Os Artigos Originais, deverão ser estruturados (Objetivo, Métodos, Resultados, Conclusões) ressaltando os dados mais significativos do trabalho. Para Artigos de Revisão, Atualização ou Relato de Caso o resumo não deverá ser estruturado. Abaixo do resumo, especificar no mínimo três e no máximo seis descritores que definam o assunto do trabalho. Os descritores deverão ser baseados no DECS - Descritores em Ciências da Saúde - disponível no endereço eletrônico http://decs.bvs.br/; ou MeSH (Medical SubjectHeadings) em/ou *MeSH* - www.nlm.nih.gov/mesh/MBrowser.html. com as versões português, inglês e espanhol para cada um dos descritores.

Ademais, nos resumos devem ser incluídos o Nível de Evidência e o Tipo de Estudo, conforme tabela de classificação anexada ao final deste texto.

Apresentação do texto

Introdução: deverá conter o objetivo do trabalho e resumir os fundamentos lógicos do mesmo. Apresentar somente as citações estritamente pertinentes e não incluir dados ou conclusões do trabalho que está sendo relatado.

Métodos: deverá descrever claramente a seleção dos indivíduos que intervieram na pesquisa (pacientes ou animais de laboratório, incluindo os controles). Identificar idade, sexo e outras importantes características do indivíduo. A definição e relevância da raça ou etnia são ambíguas. Os autores devem ser particularmente cuidadosos quando usarem estas categorias. Identificar os métodos, equipamentos (apresentar o nome e endereço do fabricante entre parênteses) e os procedimentos em detalhes suficientes para permitir a reprodução dos resultados por outros pesquisadores. Citar se o estudo foi aprovado pelo Comitê de Ética da Instituição (Instituição de afiliação de pelo menos um dos autores) e informar o respectivo número de identificação. Também deve informar se o Termo de Consentimento Livre e Esclarecido foi assinado por todos os participantes.

Resultados: deverão ser apresentados em uma sequência lógica no texto, nas tabelas e figuras. Não deverão ser repetidos no texto todos os dados das tabelas ou ilustrações, devendo ser enfatizadas ou resumidas somente as observações importantes.

Discussão: deverá enfatizar os novos e mais importantes aspectos do estudo e as conclusões que se seguem. Não deverão ser repetidos os dados apresentados na introdução ou nos resultados. Deverão ser estabelecidas novas hipóteses apenas quando elas estiverem claramente justificadas.

Conclusões: deverão ser vinculadas aos objetivos do estudo evitando-se afirmações não qualificadas e não completamente comprovadas pelos dados. Deverão apresentar argumento conclusivo detalhado dos dados comprobatórios.

Agradecimentos: quando necessário agradecer brevemente as pessoas que tenham colaborado intelectualmente, mas cuja contribuição não justifica coautoria, ou para aquelas que tenham provido apoio material, técnico, assessoria. O autor deve garantir que as pessoas, nomes, concordem em serem assim chamados. O apoio financeiro para a pesquisa e bolsas de estudo deve ser reconhecido nesta seção (agência e número de concessão).

Conflitos de interesse: devem ser reproduzidos objetivamente quando houver, e quando não houver, apresentar a declaração: "Os autores declaram inexistência de conflito de interesses na realização deste trabalho."

Declaração da contribuição de autores: deve ser expressa no final do artigo, com a utilização de dois critérios mínimos de autoria: a) participação ativa na discussão dos resultados; b) revisão e aprovação da versão final do trabalho.

Cada autor contribuiu individual e significantemente para o desenvolvimento deste artigo. AF (0000-0000-0000-0000)*: redação, revisão e realização das cirurgias; GR (0000-0000-0000-0000)*: cirurgias, análise dos dados e redação; FP (0000-0000-0000-000x)*: análise estatística, cirurgias e revisão; MAC (0000-0000-0000-0000)*: análise das lâminas e revisão; MSC (0000-0000-0000-0000)*: redação, revisão e conceito intelectual; ATA (0000-0000-0000-0000)*: cirurgia, redação, análise estatística, conceito intelectual e confecção de todo o projeto de pesquisa. *ORCID (*Open Researcher and Contributor ID*)."

Referências: devem estar rigorosamente de acordo com as instruções: *Uniform Requirements for Manuscripts Submitted to Biomedical Journals*, do International *Committeeof Medical Journal Editors*, atualizada em Outubro de 2007.Ou no site Pubmed https://www.ncbi.nlm.nih.gov/pubmed. Todos os autores e trabalhos citados no texto devem constar nas referências e vice-versa. A numeração das referências deverá ser de acordo com a ordem em que forem mencionadas pela primeira vez no texto, utilizando-se números arábicos, para o texto e para as referências. Citar todos os autores até no máximo seis; se existirem mais, citar os seis primeiros seguidos de et al. Os títulos dos periódicos deverão ser abreviados de acordo com a lista de periódicos do *Index Medicus*. Todas as referências do ano atual ou cinco anos anteriores devem estar em negrito.

Exemplos:

Artigos de periódicos: Caetano MBF, Albertoni WM, Caetano EB. Estudo anatômico das inserções distais do tendão extensor longo do polegar. Acta Ortop Bras. 2004;12(2):118-24.

Hong-Wan N, Ee-Chon T, Qing-Hang Z. Biomechanical effects of C2-C7 intersegmental stability due to laminectomy with unilateral and bilateral facetectomy. Spine. 2004;29(16):1737-45.

Livros: Defino, HLA. Lesões Traumáticas da coluna vertebral. São Paulo: Bevilacqua; 2006.

Capítulos de livros: Tencer AF. Biomechanics of spinal trauma. In: Cotler JM, Simpson JM, An HS, Silveri CP, editors. Surgery of spinal trauma. Philadelphia: Lippincott Williams & Wilkins; 2000. p. 61-112.

Dissertações e Teses: Giglio CA. Caracterização funcional e histológica de modelos experimentais de estudo do trauma raquimedular [tese]. Ribeirão Preto: Universidade de São Paulo; 2000.

Material eletrônico: Autor(es). Título do artigo. Título do periódico abreviado [suporte]. Data de publicação [data de acesso com a expressão "acesso em"]; volume(número):páginas

inicial-finalou[númerodepáginasaproximado].Endereçoeletrônicocomaexpressão"Disponívelem:" Pavezi N, Flores D, Perez CB. Proposição de um conjunto de metadados para descrição de arquivos fotográficos considerando a Nobrade e a Sepiades. Transinf. [Internet]. 2009 [acesso em 2010 nov 8];21(3):197-205. Disponível em: http://revistas.puc-campinas.edu.br/transinfo/search.php?op=search&query=metadados&limit

Figuras: As ilustrações (fotografias, desenhos, gráficos etc) deverão ser citadas como figuras devendo ser numeradas em algarismos arábicos, consecutivamente, de acordo com a ordem em que foram citadas pela primeira vez no texto. As figuras deverão ser enviadas em formato *tif* ou *jpg* com 300 DPI de resolução, em formato grande. As fotos serão publicadas em preto/branco. Para publicações coloridas o custo adicional será de responsabilidade dos autores.

Por favor, note que é de responsabilidade do autor (s) obter permissão do detentor dos direitos autorais para reproduzir figuras (ou tabelas) que tenham sido previamente publicados em outros lugares. Para todos os valores de acesso aberto, os autores devem ter permissão do detentor dos direitos, caso desejem incluir imagens que tenham sido publicados em outros lugares em periódicos de acesso não-aberto. A permissão deve ser indicada na legenda da figura, e a fonte original deve incluída na lista de referências.

Tabelas: As tabelas devem ser numeradas por ordem de aparecimento no texto com números arábicos. Cada tabela deve ter um título e, se necessário, uma legenda explicativa. Os quadros e tabelas deverão ser enviados através dos arquivos originais (p.ex. Excel) e não como imagem. Tabelas e quadros que ocupem mais de uma página devem ser evitados. Não usar elementos de imagem, caixas de texto, ou tabulações.

Abreviaturas e siglas: devem ser precedidas do nome completo quando citadas pela primeira vez no texto. Nas figuras e tabelas devem conter seu significado abaixo da figura ou tabela.

Vídeos: O envio de vídeo é opcional, e irá acompanhar a versão *on line* do artigo. Deve ser encaminhado junto com o artigo em arquivo separado e acompanhado de legenda. Os vídeos devem ser enviados em MP4.

ENVIO DO MANUSCRITO

O periódico Coluna/Columna adota o Sistema SciELO de Publicação e Submissão online disponível em http://submission.scielo.br/index.php/coluna/index. Os autores deverão seguir as instruções de cadastro e inclusão de artigo no próprio sistema.

A responsabilidade por conceitos emitidos nos artigos é da inteira responsabilidade de seus autores.
Permitida a reprodução total ou parcial dos artigos, desde que mencionado a fonte.
Todo o conteúdo do periódico, exceto onde identificado, está licenciado sob uma Licença *Creative Commons* Atribuição-tipo CC-BY.

Níveis de evidência de perguntas de pesquisa primária[a]

(Este quadro foi adotado de material publicado pelo Centro de Medicina baseada em Evidência, Oxford, Reino Unido. Para obter mais informações, visite www.cebm.net.)

Tipos de estudo

Nível	Estudos terapêuticos - Investigação dos resultados do tratamento	Estudos prognósticos – Investigação do efeito de característica de um paciente sobre o desfecho da doença	Estudos diagnósticos – Investigação de um exame para diagnóstico	Análises econômicas e de decisão – Desenvolvimento de modelo econômico ou de decisão
I	• Estudo clínico randomizado de alta qualidade com ou sem diferença estatisticamente significante, mas com intervalos de confiança estreitos • Revisão sistemática[b] de ECRC (Estudos clínicos randomizados e controlados) de Nível 1 (e resultados do estudo foram homogêneos[c])	• Estudo prospectivo de alta qualidade[d] (todos os pacientes foram inscritos no mesmo estágio da doença, com > 80% dos pacientes inscritos) • Revisão sistemática [b] de Estudos de Nível I	• Teste de critérios diagnósticos desenvolvidos anteriormente em pacientes consecutivos (com padrão de referência "ouro" aplicado) • Revisão sistemática [b] de Estudos de Nível I	• Custos e alternativas lógicos; valores obtidos de muitos estudos; com análises de sensibilidade de múltiplas vias • Revisão sistemática [b] de Estudos de Nível I
II	• ECRC de menor qualidade (por exemplo, < 80% de acompanhamento, sem mascaramento do código de randomização ou randomização inadequada) • Estudo[e] prospectivo comparativo[d] • Revisão sistemática[b] de Estudos de Nível II ou Nível I com resultados discrepantes	• Estudo retrospectivo [f] • Controles não tratados de um ECRC • Estudo prospectivo de menor qualidade (por exemplo, pacientes inscritos em diferentes estágios da doença ou <80% de acompanhamento) • Revisão sistemática[b] de Estudos de Nível II	• Desenvolvimento de critérios diagnósticos em pacientes consecutivos (com padrão de referência "ouro" aplicado) • Revisão sistemática[b] de Estudos de Nível II	• Custos e alternativas lógicos; valores obtidos de muitos estudos; com análises de sensibilidade de múltiplas vias • Revisão sistemática[b] de Estudos de Nível II
III	• Estudo de caso-controle[g] • Estudo retrospectivo[f] comparativo[e] • Revisão sistemática[b] de Estudos de Nível III	• Estudo de caso-controle[g]	• Estudo de pacientes não-consecutivos; sem padrão de referência "ouro" aplicado uniformemente • Revisão[b] sistemática de Estudos de Nível III • Estudo de caso-controle • Padrão de referência ruim	• Análises baseadas em alternativas e custos limitados; e estimativas ruins • Revisão sistemática[b] de Estudos de Nível III
IV	Série de casos[h]	Série de casos	• Estudo de caso-controle • Padrão de referência ruim	• Análises sem análises de sensibilidade
V	Opinião do especialista	Opinião do especialista	Opinião do especialista	Opinião do especialista

[a]Avaliação completa da qualidade de cada estudo requer aquilatação de todos os aspectos do desenho do estudo.

[b]Combinação de resultados de dois ou mais estudos anteriores.

[c]Estudos proporcionaram resultados coerentes.

[d]Estudo iniciou antes de o primeiro paciente ser inscrito.

[e]Pacientes tratados de um modo (por exemplo, artroplastia cimentada de quadril) comparada com um grupo de pacientes tratados de outra maneira (por exemplo, artroplastia não-cimentada de quadril) na mesma instituição.

[f]O estudo iniciou depois da inscrição do primeiro paciente.

[g]Os pacientes identificados para o estudo com base em seu desfecho clínicos, chamados de "casos", por exemplo falha da artroplastia total, são comparados com os pacientes que não tiveram desfechos, chamados "controles", por exemplo, artroplastia total do quadril bem-sucedida.

[h]Pacientes tratados de uma maneira sem grupo de comparação de pacientes tratados de outro modo.

• A responsabilidade por conceitos emitidos nos artigos é da inteira responsabilidade de seus autores. • Permitida a reprodução total ou parcial dos artigos, desde que mencionado a fonte. • Todo o conteúdo do periódico, exceto onde identificado, está licenciado sob uma Licença Creative Commons Atribuição-tipo CC-BY.

LAMINOPLASTY AND CORPECTOMY IN THE TREATMENT OF CERVICAL SPONDYLOTIC MYELOPATHY

LAMINOPLASTIA E CORPORECTOMIA NO TRATAMENTO DA MIELOPATIA ESPONDICOLÓGICA CERVICAL

LAMINOPLASTIA Y CORPECTOMÍA EN EL TRATAMIENTO DE LA MIELOPATÍA ESPONDILÓTICA CERVICAL

DREVAL' MAXIM DMITRIEVICH[1], ARESTOV SERGEY OLEGOVICH[1], PETROSYAN DAVID VAZGENOVICH[1], KASHCHEEV ALEXEY ALEXEEVICH[1], VERSHININ ANDREY VYACHESLAVOVICH[1], POLTORAKO EKATERINA NIKOLAEVNA[1], GUSHCHA ARTEM OLEGOVICH[1]

1. Federal State Research Institution Research Center of Neurology, Department of Neurosurgery, Moscow, Russia.

ABSTRACT

Introduction: Cervical Spondylotic myelopathy (CSM) is a disabling manifestation of extended cervical stenosis characterized by pronounced neurological dysfunction. Decompressive interventions contribute to significant regression of symptoms and, in some cases, complete recovery can be achieved. Objective: To explore the potential of laminoplasty in patients with extended cervical spondylotic stenoses complicated by myelopathy, and to develop approaches for surgical intervention in these patients. Methods: Fifty-six patients were included in the study. Laminoplasty was performed in 34 patients. Corpectomy was performed in 22 patients who made up the comparison group. The frequency and initial severity of concomitant non-neurological disorders in both groups were comparable. Results: Indications for laminoplasty were determined. They include: symptoms of spondylotic myelopathy, three or more levels of compression, preservation of lordosis, absence of signs of segmental instability, inability to perform anterior decompression, and age over 55 years. The presence of signs of segmental instability, kyphotic deformation, and history of mental disorders may be considered as contraindications for this surgery. Conclusions: Due to a number of advantages, laminoplasty is the treatment of choice for extended cervical spondylotic stenosis. Adequate selection of patients based on the evaluation of clinical symptoms, extension of stenosis, neurological signs and neuroimaging features enable excellent results to be achieved. ***Level of Evidence: II. Type of Study: Prospective comparative study.***

Keywords: Myelitis; Laminoplasty; Spinal fusion; Spinal stenosis.

RESUMO

*Introdução: A mielopatia espondilótica cervical (MSC) é uma manifestação incapacitante de estenose cervical extensa, caracterizada por disfunção neurológica pronunciada. As intervenções descompressivas contribuem para a regressão significativa dos sintomas e, em alguns casos, a recuperação completa pode ser alcançada. Objetivo: Explorar o potencial da laminoplastia em pacientes com estenoses espondilóticas cervicais extensas complicadas por mielopatia e desenvolver abordagens para intervenção cirúrgica nesses pacientes. Métodos: 56 pacientes foram incluídos no estudo. A laminoplastia foi realizada em 34 pacientes. A corpectomia foi realizada em 22 pacientes, que compuseram o grupo de comparação. A frequência e a gravidade inicial dos distúrbios não neurológicos concomitantes em ambos os grupos foram comparáveis. Resultados: As indicações para laminoplastia foram determinadas. Eles incluem: sintomas de mielopatia espondilótica, três ou mais níveis de compressão, preservação da lordose, ausência de sinais de instabilidade segmentar, incapacidade de realizar descompressão anterior e idade superior a 55 anos. A presença de sinais de instabilidade segmentar, deformação cifótica e história de transtornos mentais podem ser considerados como contraindicações para essa cirurgia. Conclusões: Devido a uma série de vantagens, a laminoplastia é o tratamento de escolha para estenose espondilótica cervical estendida. A seleção adequada dos pacientes, com base na avaliação dos sintomas clínicos, extensão da estenose, sinais neurológicos e características de neuroimagem, possibilitam alcançar excelentes resultados. **Nível de Evidência: II . Tipo de Estudo: Estudo Comparativo prospectivo.***

Descritores: *Mielite; Laminoplastia; Fusão vertebral; Estenose espinal.*

RESUMEN

Introducción: La mielopatía espondilótica cervical (MSC) es una manifestación incapacitante de estenosis cervical extendida caracterizada por una fuerte disfunción neurológica. Las intervenciones de descompresión contribuyen a la regresión significativa de los síntomas y, en algunos casos, se puede lograr una recuperación completa. Objetivo: Explorar el potencial de la laminoplastia en pacientes con estenosis espondilótica cervical extendida complicada por mielopatía y desarrollar enfoques para la intervención quirúrgica en estos pacientes. Métodos: Cincuenta y seis pacientes fueron incluidos en el estudio. Laminoplastia se realizó en 34 pacientes. Corpectomía se realizó en 22 pacientes que componen el grupo de comparación. La frecuencia y la gravedad inicial de los trastornos no neurológicos concomitantes en ambos grupos fueron comparables. Resultados: Se determinaron las indicaciones para laminoplastia. Estas incluyen: síntomas de mielopatía espondilótica, tres o más niveles de compresión, preservación de la lordosis, ausencia de signos de inestabilidad segmentaria, incapacidad

Study conducted at Research Center of Neurology. 125367, Volokolamskoe sh., d. 80, Moscow, Russia.
Correspondence: Dreval' Maksim D. Department of Neurosurgery, Research Center of Neurology. 125367, Volokolamskoe sh., d. 80, Moscow, Russia. neurodreval@gmail.com

CC BY

http://dx.doi.org/10.1590/S1808-185120181703193258

Received on 03/21/2018 accepted on 07/25/2018

para realizar descompresión anterior y edad mayor de 55 años. La presencia de signos de inestabilidad segmentaria, deformación cifótica y antecedentes de trastornos mentales puede considerarse una contraindicación para esta cirugía. Conclusiones: Debido a una serie de ventajas, la laminoplastia es el tratamiento de elección para la estenosis espondilótica cervical extendida. La adecuada selección de pacientes basada en la evaluación de los síntomas clínicos, la extensión de la estenosis, los signos neurológicos y las características de neuroimágenes hacen posible obtener excelentes resultados. ***Nivel de Evidencia: II Tipo de Estudio: Estudio comparativo prospectivo.***

Descriptores: *Mielitis; Laminoplastia; Fusión vertebral; Estenosis espinal.*

INTRODUCTION

The treatment of degenerative spine diseases is urgent nowadays. This group of pathologies has many clinical manifestations and forms, and the average age of this group of patients is becoming steadily lower. Various manifestations of degenerative spine disease affect the working population aged 25-45 years. In developed countries 30% of the population is affected by back pain and about 70% of population visits a neurologist due to back pain at least once in their lifetime.[1] According to Watkins et al., the lumbar spine is affected in the majority of cases (62%), the cervical spine is involved less often (36%), the degenerative disease of the thoracic spine is comparatively rare (2%).[2]

Despite the high frequency of degenerative disease detection in cervical spine, defining its treatment tactics is still quite disputable.[3-5] A major question of surgical treatment of a single-level spine pathology is usually the choice of an implant, except in cases of lateral intervertebral disc hernias, which can be managed by an anterior uncoforaminotomy or endoscopic interlaminotomy. Even more questions arise in cases of extended cervical stenosis complicated by spondylogenic cervical myelopathy. The majority of the population aged >55 years have x-ray signs of cervical spinal canal stenosis, and a third of them have corresponding clinical and neurological manifestations.[3] The decision to carry out surgery is often postponed until the formation of a persistent neurological impairment, due to the remissive nature of this disease. In a study of 120 patients, Clarke and Robinson analyzed the dynamics of its clinical progression: 50% of patients were stable and had no evident progression, 25% had progression tendency with remission periods, 20% had neurological impairment with no remissions, and 5% had rapid progression.[6] As Lees and Turner showed in 1963, patients who suffer from a spinal cord compression for more than ten years become disabled in the majority of cases.[7]

When it comes to choosing surgical treatment for extended cervical stenosis, surgeons are guided by the following rules: maximum decompression of the spinal cord and nerve roots with maximum preservation or reconstruction of the vertebral column, minimization of postoperative complications, and the shortest possible hospitalization time.[8-11]

There are several surgical techniques for managing this pathology, most of which are performed via the anterior and posterior approaches. Despite their great popularity among neurosurgeons and orthopedists, anterior surgical approaches have several disadvantages (risk of recurrent laryngeal nerve and esophagus injury, pseudoarthrosis formation, adjacent level disease etc.).[12,13] Laminectomy is probably the oldest surgical technique for managing the degenerative disease of cervical spine, and was originally used to treat cervical spine stenosis. In the mid-1980s, a series of articles appeared describing negative outcomes of laminectomy - axial pain, formation of kyphotic deformation, etc.[10,14-16]

Laminoplasty is one of the posterior approaches used for spinal cord decompression in cases of cervical spondylosis, ossification of the posterior longitudinal ligament, intervertebral disc herniation, primary spinal stenosis, or a combination of the above. Cervical laminoplasty was initially described by Oyama in 1973.[17] Since then, the original technique has undergone a number of improvements. There are about twenty different modifications of laminoplasty. Since its start, laminoplasty has been actively implemented and has defined its niche in the surgical treatment of cervical spondylotic myelopathy (CSM), although it has not received proper attention in various industrialized and developing countries. The mastery and popularization of laminoplasty techniques, and their active introduction into the practice of cervical stenosis treatment, will significantly increase the efficiency of surgery and reduce intraoperative trauma.[9-12,14]

Objective: To assess the possibilities of laminoplasty surgery techniques and develop surgery tactics in patients with extended spondylogenic cervical stenosis complicated by myelopathy.

METHODS

This study included 56 patients with CSM. Laminoplasty was performed in 34 patients who were recruited between the end of 2011 and 2015. The median age was 59.4 ± 12.8 years, and the ratio of women and men was 9:25. Of the total, 28 patients had three levels of stenosis, four patients had four, and two patients had five. In the control group, 22 patients underwent corpectomy; these operations were performed between 2010 and 2011, the average age of the patients was 43.8 ± 16.4 years, and the ratio of women and men was 7:15. The frequency of comorbidities and their severity in the two groups were comparable ($p>0.05$).

The clinical characteristics of the patients included in the study are shown in Table 1.

The collection of medical anamnesis and the neurological examination were performed independently by two specialists - a neurosurgeon and a neurologist. Assessment of the patients' clinical status was carried out using the following scales and questionnaires:

1. Modified scale of the Japanese Orthopedic Association (JOA score).
2. Scale of cervical myelopathy according to Nurick (Nurick grade).
3. Scale of evaluation of proprioceptive sensitivity (Doita, Sakai).[18]
4. Visual analogue pain scale (VAS) in the postoperative period.

We used MRI (magnetic induction of at least 1.5 T) as a basic examination for all patients. Where necessary, neurophysiological methods (somatosensory evoked potential - SSEP, and transcranial magnetic stimulation - TMS) were used.

The study was approved by the local ethics committee of the FGBNU Scientific Center of Neurology, Moscow. Patients signed an informed consent form before being recruited into the study.

Statistical data were evaluated using the PASW Statistics 18 software. The significance level (p) was assumed to be 0.05 for all the comparisons performed.

Table 1. Clinical presentations of cervical spondylotic myelopathy.

Symptoms	Laminoplasty (n = 34)		Corpectomy (n = 22)	
	n	%	n	%
Upper paraparesis	11	31.9%	8	36%
Tetraparesis	17	49.3%	13	59%
Sensory disorders	24	70.5 %	18	81%
Bowel and bladder disorders	2	5.8 %	1	4,5%
Reflex abnormalities	29	84.1	21	94,5%
Gait disorders	17	49.3	11	49,5%
Muscle atrophy	20	58.0 %	16	72%
Combination of clinical symptoms	34	100%	22	100%

Surgical technique and stages

All operations were performed under general endotracheal anesthesia.

The initial stages of the operation are shown in Figure 1A. The importance of cutaneous incision and subperiosteal dissection (skeletization, Figure 1B, 1C) should be emphasized; these must be performed strictly by the middle line, which enables the muscle tissue to be preserved and minimizes blood loss, as well as reducing the further axial pain in the neck.

The next step is to perform a bilateral foraminotomy at the C4-C5 level. Foraminotomy is an addition to the main stage, and serves to prevent paresis of the muscles innervated by the roots of C5. In the lateral part of the C4-C5 arches, minimal bone resection is followed by a flavectomy and visualization of the roots of C5. Less than 25% of the facet joints is resected. The root ganglion can be visualized and revised by a hook at less than 20% joint resection. This nerve root decompression was sufficient, in our study, to achieve a good result (Figure 2A, 2B, 2C, 2D).

The next stage of the operation is to saw the vertebral arcs. This manipulation and the subsequent lifting of the posterior support complex is the most dangerous stage in terms of potential damage to the dura mater, as it involves mobilization of the dural sac, and risk of bleeding from the spasmodic lateral veins, etc. During the preoperative modeling, the sides of through and partial cuts of the vertebral arches are determined, depending on the neurological symptoms and localization of maximum compression, which are usually concordant. In cases where there is a discrepancy between the symptoms and radiological data, through-cuts are performed on the side with the most severe symptoms, and one- or multi-level foraminotomy is also performed on the side of stenosis (Figure 3A, 3B). In other cases, MRI and CT data are followed.

Bilateral sawing allows the arches to be lifted, increasing the angle to 30 or more degrees. The mobility of the complex is examined by dragging the spinous processes; in sites where the arch is not completely resected, palpation reveals an obstacle, usually occurring in the area of "tile" joint overlay. After bone perforation towards the cut lumen, a hemostatic gauze must be applied.

The step of raising and fixing the arches carries an increased risk of damaging the dura mater. It is very important to prevent an inner cortical layer fracture on the partial cut side when lifting the posterior complex (Figures 4A, 4B, 4C).

For the final fixation of the support complex, standard microplates for maxillofacial surgery and cranioplasty are used (Figures 5A, 5B, 5C). For a reliable fixation, screws with a depth of 6 mm are used. The thickness of the plate differs from 0.6 to 10 mm (a smaller plate thickness is not recommended because of the risk of fracture). In our experience, implementation of two or more screws in the joint and arch fixation reliably fixes the plate and practically excludes its fracture, if all the requirements are met in the postoperative period.

After assessing the mobility of the arch-spinous complex, the surgeon proceeds to modeling the microplate. The plate is modeled intraoperatively and individually for each patient. A plate that has been modeled more than three times is not recommended for installation due to metal fatigue. The modeled plate is initially fixed to the arcuate joint, then fixation is performed for the mobilized arch. It is important to fix the arch without using excessive force, i.e., it is not recommended fixing the arch in the position of maximum ascent angle (Figure 6A, 6B).

RESULTS

For the patients of the laminoplasty group, when assessing the severity of myelopathy using JOA scale in the preoperative period,

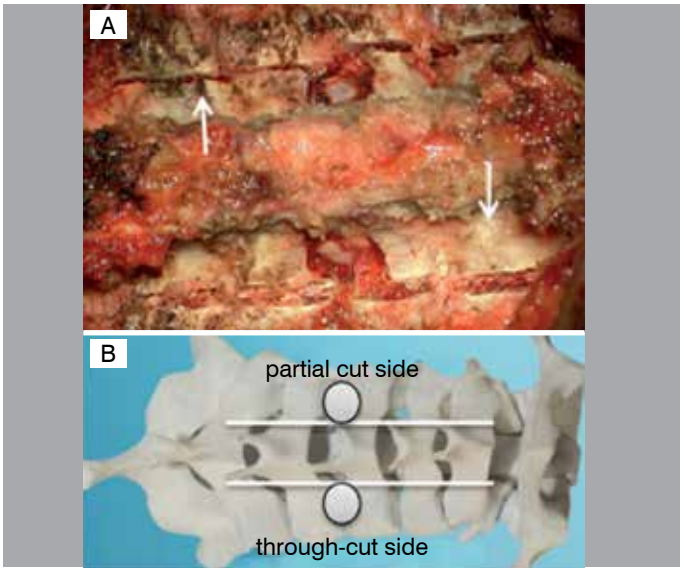

Figure 3. Sawn vertebral arches. A.Cutting of the vertebral arches at the level of stenosis; B. the plan of vertebral arch sawing.

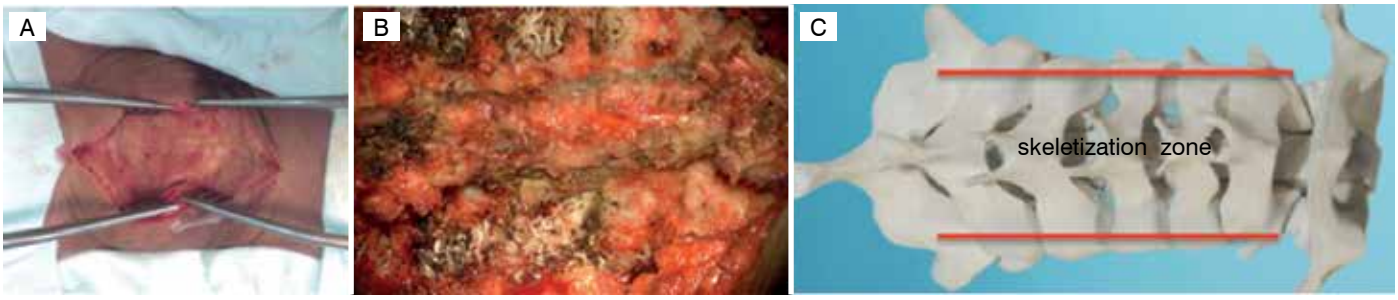

Figure 1. Initial stages of surgery. A. Skin Incision along the middle, bloodless line; B. the skeletization stage is completed; the medial edges of the vertebral arches and lateral parts of the arcuate joints are fully visualized; C. skeletization zone of the arcuate joints .



Figure 2. Foraminotomy. A. Use of a boron with a diamond nozzle; B. foraminotomy is carried out using a hook; the root is explored; C. bilateral foraminotomy is performed; D. zone of foraminal decompression.

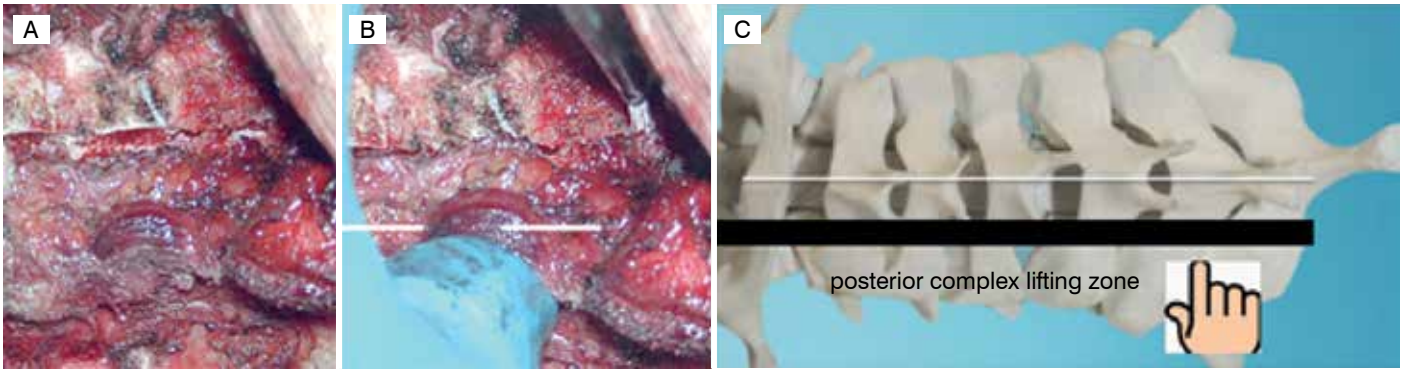

Figure 4. Raising/bringing the arches to the fixation position. A. Spinous processes: the bilateral arches are sawn; B. assessment of mobilization by abduction of the spinous process; C. zone of resection and elevation of the complex.



Figure 5. Fixation of the support complex. A. Modeled intraoperative plate; B. self-drilling screws, 6 and 5 mm; C. a demountable screwdriver with two tips, one of which is a drill bit.

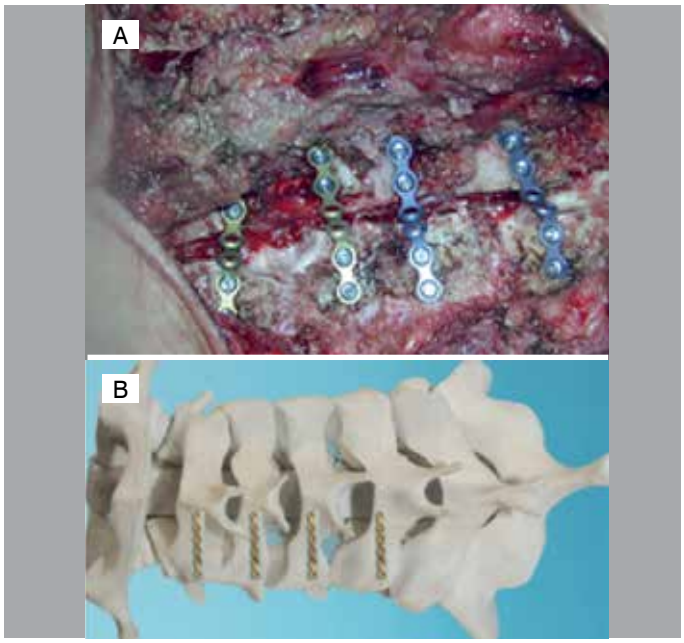

Figure 6. The final appearance of the wound. A. Laminoplasty on 4 levels; B. Vertebral arches fixed by implanted microplates.

the average result was 8.27 ± 2.1 points, which corresponds to severe myelopathy. The average score on the JOA scale 18-24 months after surgery was 11.18 ± 1.6. This shows a transition of myelopathy severity to the moderate level in this group. The average recovery rate was 28.2% ± 11.3% in patients who had had clinical manifestations of more than 18 months, and 46.2% ± 19.2% in patients with symptoms for less than 18 months ($p < 0.05$).

In the patients of the corpectomy group, the mean JOA score for myelopathy was 10 ± 2.4 in the preoperative period (moderate severity). The average JOA score 18-24 months after the operation was 15 ± 1.2. The average recovery rate was 44.7 ± 16.4% in patients with symptoms lasting more than 18 months and 58.8 ± 18.1% in patients with symptoms lasting less than 18 months.

Subgroups of patients with different preoperative clinical status and disease durations were compared, to assess the prognosis of neurological deficit recovery. The clinical presentation was assessed 24 months after laminoplasty and corpectomy. Patients were divided into two subgroups, depending on the duration of the disease: > 2 years and <2 years (Table 2).

We analyzed the patients' status using the Nurick scale before and after laminoplasty, to evaluate the result of the operation in terms patient transition from one level of myelopathy severity to another (Table 3).

Table 4 shows the dynamics of proprioception and tactile sensitivity (Doita, Sakai scale) 6 months after laminoplasty. As the table shows, a number of patients had either a decrease in severity or normalization in terms of proprioception and tactile perception impairment. It is important to note that the patients we observed for more than 6 months did not experience any further significant improvement; these parameters should therefore be evaluated in the first 6 months.

This study demonstrates maximum efficacy of laminoplasty at moderate and severe stages of proprioception deterioration.

Table 2. Assessment of recovery according to the JOA scale in patients with myelopathy depending on the duration of the disease.

Index on JOA scale before laminoplasty		Index on JOA scale after laminoplasty		Recovery factor (Kr)	
History > 2 years	History < 2 years	History > 2 years	History < 2 years	History > 2 years	History < 2 years
8.27±1.4	11.3±1.2	11.18 ±2.4	13.8 ±1.5	28.2 ±11.3	46.2 ±19.2
10±2.4	12.4±1.5	14.7±0.6	15.4 ±1.5	44.7±16.4	58.8±18.1

Table 3. Pre- and postoperative neurological evaluation of the patients of the laminoplasty group.

Nurick grade before laminoplasty		Nurick grade after laminoplasty
Grade 1	3 patients (8.8%)	6 patients (17.7%): + 3 patients from grade 2
Grade 2	7 patients (20.6%)	9 patients (26.5%): + 5 patients from grade 3, transition of 3 patients to grade 1
Grade 3	18 patients (52.9%)	16 patients (47%): + 3 patients from grade 4, transition of 5 patients to grade 2
Grade 4	4 patients (11.8%)	1 patient (2.9%): + 1 patient from grade 5, transition of 3 patients to grade 3, transition of 1 patient to grade 5
Grade 5	2 patients (5.9%)	2 patients (5.9%): +1 patient from grade 4, transition of 1 patient to grade 4

The incidence of complications was almost identical in two groups of patients, as shown in Table 5.

The final assessment criterion was the severity of the neck pain by VAS. As Table 6 shows, in the corpectomy group, cervical axial pains in the early postoperative period were slightly milder compared to laminoplasty group, which is explained by a more rigid fixation performed by the anterior approach. Residual pain in the neck after laminoplasty is associated with intraoperative damage to the posterior neck muscles and extensive bone resection (innervation of the periosteum); restriction of the movements in the cervical spine for 1.5-2 months after the operation is another reason, in our opinion.

DISCUSSION

In the present study, we conducted the first systematic comparison of laminoplasty and corpectomy results in surgical treatment of CSM in Russia.

Table 4. Pre- and postoperative evaluation of proprioception and light touch sensation (Doita, Sakai scale)[18] in the laminoplasty group.

	Proprioception (n = 34)		Light touch (n = 34)	
	before surgery	6 months after surgery	before surgery	6 months after surgery
Grade 0 (normal)	3 patients (8.8%)	9 patients (26.5%): +6 patients from grade 1	2 patients (5.9%)	8 patients (23.5%): +6 patients from grade 1
Grade 1	18 patients (52.9%)	16 patients (47%): +4 patients from grade 2, transition of 6 patients to grade 0	14 patients (41.2%)	13 patients (38%): +5 patients from stage 2, transition of 6 patients to grade 0
Grade 2	9 patients (26.5%)	6 patients (17.7%): +1 patient from grade 3, transition of 4 patients to grade 1	15 patients (44%)	11 patients (32%): +1 patient from grade 3, transition of 5 patients to grade 1
Grade 3	4 patients (11.8%)	3 patients (8.8%): transition of 1 patient to grade 2	3 patients (8.8%)	2 patients (5.8%): transition of 1 patient to grade 2

Table 5. Early and delayed complications.

Complications	Laminoplasty (n = 34)	Corpectomy (n = 22)	Outcome
Transient C5 palsy	3 (8.8%)	0 (0%)	Full regress until discharge
Revision intervention	2 (5.9%)	2 (9.1%)	Postoperative hematoma, failure of decompression
Kyphotic deformation	1 (2.9%)	2 (9.1%)	kinesiotherapy, rehabilitation
Severe proprioception deterioration	1 (2.9%)	1 (4.5%)	Active postoperative rehabilitation, unchanged
Adjacent level syndrome	1 (2.9%)	3 (13.6%)	Surveillance, rehabilitation

Table 6. Dynamics of cervicalgia (VAS score).

Cervicalgia before laminoplasty	Cervicalgia after laminoplasty		Cervicalgia before corpectomy	Cervicalgia after corpectomy	
2.0±1.7	6–12 months	>24 months	1.9±1.3	6–12 months	>24 months
	4.0±2.4	4.0±2.9		2.9±1.5	3.7±1.8

Comparative analysis shows high efficiency of both methods. In the laminoplasty group, there was a clear tendency for a significant neurological improvement in patients with moderate or severe manifestations of the disease. Improvement of the overall neurological status after surgery achieved in both groups was similar, as was the severity of the pain syndrome in a later (over 2 years) postoperative period. The length of stay for laminoplasty was from 5 to 20 days (7.0 ± 2.9), which is 2.5 days more than for corpectomy.

According to our experience and the literature data, indications for laminoplasty are as follows: clinical symptoms of spondylogenic myelopathy, the presence of three or more levels of compression, lordosis preservation, absence of segmental instability signs, inability to perform an anterior decompression, and age over 55 years. Contraindications are: signs of segmental instability, kyphotic deformity, untreatable comorbidities, presence of functional disorders of the nervous system, a mental illness in the anamnesis.[19-21]

The most common complication of laminoplasty is paresis of the muscles innervated by C5 roots (8.8%). To prevent this, we introduced the practice of bilateral C4-C5 foraminotomy. Laminoplasty can be performed to save the support function of the vertebral column after removal of extensive cervical tumors. It is acceptable to use laminoplasty in cases of dorsal one-level stenosis.

It appears that a long history of the disease and a severe neurological deficit (the last stage of Nurick scale and <8 on the JOA scale) are also contraindications for laminoplasty with simultaneous C4-C5 foraminotomy. On the other hand, laminoplasty can be a complement to cervical spine operations performed from the posterior approach (removal of intra- or extramedullary tumors, DREZ operations, as well as a single-level isolated posterior stenosis).

Thus, our study shows the efficacy of laminoplasty with simultaneous foraminotomy in the surgical treatment of patients with CSM. We clarified the indications for implementation of decompressive--plastic surgery in this category of patients, and the obtained data can be used in the clinical practice of central and regional neurosurgical hospitals.

CONCLUSIONS

Both laminoplasty and corpectomy with consecutive stabilization are effective in surgical treatment of CSM. Significant neurological improvement is achieved in patients with moderate or severe manifestations of the disease. Severity of the pain syndrome in a later postoperative period is similar after laminoplasty and corpectomy surgery. Laminoplasty technique is preferred where there are clinical symptoms of spondylogenic myelopathy, presence of three or more levels of compression, preservation of lordosis, absence of segmental instability signs or kyphotic deformity, and inability to perform an anterior decompression. Laminoplasty can also be used in cases of dorsal one-level stenosis.

Bilateral C4-C5 foraminotomy is suggested to prevent C5-roots paresis after laminoplasty. But laminoplasty with simultaneous C4-C5 foraminotomy should not be performed in cases of long history of the disease and severe neurological deficit.

Outcomes of the data show a decreased risk of surgery complications compared to the anterior approaches. Meanwhile, axial pain in the early postoperative period is slightly stronger than in the corpectomy group, due to the less rigid fixation.

Improvements in proprioception and tactile sensitivity should be evaluated within the first 6 months after laminoplasty surgery. Our evidence suggests that laminoplasty is most effective at moderate and severe stages of proprioception deterioration.

Adequate selection of patients, based on the evaluation of clinical symptoms, extension of stenosis, neurological signs, and neuroimaging features enable excellent results to be achieved.

All authors declare no potential conflict of interest related to this article.

CONTRIBUTION OF THE AUTHORS: Each author made significant individual contributions to this manuscript. MD (0000-0002-7839-309X)*, SA (0000-0003-4809-4117)* and DP (0000-0001-9588-7721)* were the main contributors in the drafting of the manuscript. MD, SA and DP performed the surgery, followed up patients and gathered clinical data. MD, SA and DP evaluated the data from the statistical analysis. AG (0000-0003-3451-5750)*, AK (0000-0001-7681-3073)*, AV (0000-0002-8006-1334)* and EP (0000-0001-9208-2987)* performed the literature search and review of the manuscript, and contributed to the intellectual concept of the study. *ORCID (Open Researcher and Contributor ID).

REFERENCES

1. Belova AN. Neyroreabilitatsiya: rukovodstvo dlya vrachey. 2-e izd. [Neurorehabilitation: guide for doctors. 2nd edition]. Moscow: Antidor. 2002. (In Russ.)
2. Uotkins RG. [Predicting the outcomes of surgical treatment in patients with chronic disability due to pain in the lumbar spine]. Vestnik travmatologii i ortopedii im. NN Priorova. 2002;3:58-65. (In Russ.)
3. Matz PG, Anderson PA, Holly LT, Groff MW, Heary RF, Kaiser MG et al. The natural history of cervical spondylotic myelopathy. J Neurosurg Spine. 2009;11(2):104-11.
4. Dreval' MD, Gushcha Ao. [Surgical treatment of cervical spondylotic myelopathy using the method of laminoplasty: a review of the literature]. Hirurgiya pozvonochnika. 2015;12:44-50. (In Russ.)
5. Yusupov, MN. [Comparative analysis of structural and functional manifestations of cervical spondylotic myelopathy before and after decompressive operations]. Avtoreferat dis.... kand. med. nauk. Saint-Petersburg; 2011:6-24. (In Russ.)
6. Clarke E, Robinson PK. Cervical myelopathy: a complication of cervical spondylosis. Brain. 1956;79(3):483-510.
7. Lees F, Turner JW. Natural History and Prognosis of Cervical Spondylosis. Br Med J. 1963;2(5373):1607-10.
8. Bohm PE, Fehlings MG, Kopjar B, Tetreault LA, Vaccaro AR, Anderson KK et al. Psychometric properties of the 30-m walking test in patients with degenerative cervical myelopathy: results from two prospective multicenter cohort studies. Spine J. 2017;17(2):211-17.
9. Chung JY, Kim SK, Jung ST, Lee KB. Clinical adjacent-segment pathology after anterior cervical discectomy and fusion: results after a minimum of 10-year follow-up. The Spine Journal. 2014;14(10):2290-8.
10. Heller JG, Edwards CC, Murakami H, Rodts GE. Laminoplasty versus laminectomy and fusion for multilevel cervical myelopathy: an independent matched cohort analysis. Spine (Phila Pa 1976). 2001;26(12):1330-6.
11. Guscha AO, Dreval MD, Kireeva NS, Korepina OS, Arestov SO, Petrosyan DV et al. Laminoplasty and corporectomy in the treatment of spondylotic cervical myelopathy. Annals of clinical and experimental neurology. 2017;11(4):34-41. (In Russ.)
12. Hale JJ, Gruson KI, Spivak JM. Laminoplasty: a review of its role in compressive cervical myelopathy. Spine J. 2006;6(6 Suppl):289S-98.
13. Klement MR, Kleeman LT, Blizzard DJ, Gallizzi MA, Eure M, Brown CR. C5 palsy after cervical laminectomy and fusion: does width of laminectomy matter? Spine J. 2016;16(4):462-7.
14. Haddas R, Ju KL, Patel S, Arakal RG, Boah A, Belanger TA. Effect of Cervical Decompression Surgery on Gait in Adult Cervical Spondylotic Myelopathy Patients. The Spine Journal. 2017;17(10):S135.
15. Hirabayashi K, Watanabe K, Wakano K, Suzuki N, Satomi K, Ishii Y. Expansive open-door laminoplasty for cervical spinal stenotic myelopathy. Spine (Phila Pa 1976). 1983;8(7):693-9.
16. Lesoin F, Bouasakao N, Cama A, Servato R, Jomin M. [Role of surgical decompression by the anterior approach in myeloradiculopathies caused by cervical arthrosis. Apropos of 850 cases]. Sem Hop. 1983;59(39):2669-77. (In French)
17. Oyama M, Hattori S, Moriwaki N. A new method of cervical laminectomy. Chubu Nippon Seikeisaigaigeka. Gakkai Zasshi (Central Jpn J Orthop Traumatol). 1973;16:792-4.
18. Doita M, Sakai H, Harada T, Nishida K, Miyamoto H, Kaneko T et al. The influence of proprioceptive impairment on hand function in patients with cervical myelopathy. Spine (Phila Pa 1976). 2006;31(14):1580-4.
19. Derenda M, Kowalina I. [Cervical laminoplasty - review of surgical techniques, indications, methods of efficacy evaluation, and complications]. Neurol Neurochir Pol. 2006;40(5):422-32. (In Polish)
20. Li Q, Kong Q, Zhang L, Sun T, Li T, Gong Q et al. [Discussion of surgical indications for posterior expansive open-door laminoplasty extended to C1 level.] Zhongguo Xiu Fu Chong Jian Wai Ke Za Zhi. 2013;27(10):1214-20. (In Chin).
21. Yoshida M, Tamaki T, Kawakami M, Hayashi N, Ando M. Indication and clinical results of laminoplasty for cervical myelopathy caused by disc herniation with developmental canal stenosis. Spine (Phila Pa 1976). 1998;23(22):2391-7.

ANALYSIS OF POSTOPERATIVE OUTCOMES OF DEGENERATIVE DISEASES OF THE LUMBOSACRAL JUNCTION

ANÁLISE DOS RESULTADOS PÓS-OPERATÓRIOS DO DEGENERADOR DA JUNÇÃO LOMBOSSACRAL

ANÁLISIS DE LOS RESULTADOS POSTOPERATORIOS DE LAS ENFERMEDADES DEGENERATIVAS DE LA UNIÓN LUMBOSACRA

Vadim Anatol'evich Byvaltsev[1,2,3,4], Andrei Andreevich Kalinin[1,2], Yuri Yakovlevich Pestryakov[1], Samuil Semenovich Rabinovith[5], Marat Amangeldyevich Aliyev[1], Svetlana Victorovna Shvetsova[6]

1. Irkutsk State Medical University, Irkutsk, Russia.
2. Railway Clinical Hospital, Irkutsk, Russia.
3. Irkutsk Research Center Surgery and Traumatology, Irkutsk, Russia.
4. Irkutsk state medical academy of postgraduate education, Irkutsk, Russia.
5. Novosibirsk scientific research Institute of traumatology and orthopedics named after Y. L. Tsivyan, Novosibirsk, Russia.
6. Irkutsk state agrarian university named after A.A. Ezhevsky, Irkutsk, Russia.

ABSTRACT

Objective: The article presents an analysis of the clinical efficacy and causes of unsatisfactory outcomes of surgical treatment in patients with degenerative diseases of the lumbosacral junction of the spine. Methods: Patients were allocated to one of three groups, depending on the method of surgical intervention on the lumbosacral junction: 1) (n=352) – operated by the method of microsurgical discectomy; 2) (n=83) – operated with the use of artificial IVD prostheses; 3) (n=183) – operated with the use of interbody fusion and posterior rigid stabilization. To investigate the causes of unsatisfactory outcomes, a correlation analysis was conducted of long-term clinical outcomes with preoperative instrumental parameters in the operated segment, surgical tactics used, and the development of complications. Results: It is determined that long-term "good" clinical outcomes are associated with individual preoperative parameters of the lumbosacral junction of the spine - linear displacement, sagittal angulation, height of the interbody space, degree of IVD degeneration by ADC. Conclusion: In degenerative diseases of the lumbosacral junction of the spine, the detailed analysis of long-term clinical outcomes enable the identification of the causes that affect the development of unsatisfactory outcomes, which are individual morphostructural changes in the lower lumbar segment: the amplitude of the segmental angle, the angle of the lumbar lordosis, the degree of linear displacement of the vertebrae, the height of the interbody space, and ADC. Complex clinical and instrumental analysis enabled us to determine possible surgical tactics. ***Level of Evidence II; Prognostic Studies— Investigating the Effect of a Patient Characteristic on the Disease Outcome.***

Keywords: Intervertebral disc; Zygapophyseal joint; Chronic Disease; Discectomy; Spinal fusion; Arthroplasty.

RESUMO

Objetivo: O artigo apresenta a análise da eficácia clínica e as causas dos resultados insatisfatórios no tratamento cirúrgico de pacientes com doenças degenerativas da articulação lombossacral da coluna vertebral. Métodos: Dependendo do método da intervenção cirúrgica na junção lombossacral, três grupos de pacientes foram alocados: 1) (n = 352) - operado pelo método de discectomia microcirúrgica; 2) (n = 83) - operado com a utilização de próteses artificiais IVD; 3) (n = 183) - operado com a utilização de fusão intercorporal e estabilização rígida posterior. Para investigar as causas de resultados insatisfatórios, foi realizada uma análise de correlação do desfecho clínico a longo prazo com parâmetros instrumentais pré-operatórios no segmento operado, táticas cirúrgicas e desenvolvimento de complicações. Resultados: Determinou-se que o resultado clínico "bom" a longo prazo está associado a parâmetros pré-operatórios individuais da junção lombossacral da coluna - deslocamento linear, angulação sagital, altura do espaço inter-corpo, grau de degeneração IVD por ADC. Conclusão: Nas doenças degenerativas da junção lombossacral da coluna vertebral, a análise detalhada do curso clínico a longo prazo, que é uma alteração morfoestrutural individual no segmento lombar inferior - a amplitude do ângulo segmentar, o ângulo de lordose lombar, o grau de deslocamento linear das vértebras, a altura do espaço de corpo intermédio, ADC, análise clínica e instrumental complexo - permitiu determinar possíveis táticas cirúrgicas. ***Nível de Evidência II; Estudos prognósticos – Investigação do efeito de característica de um paciente sobre o desfecho da doença.***

Descritores: *Disco intervertebral; Articulação zigapofisária; Doença crônica; Discotomia; Fusão Vertebral Artroplastia.*

RESUMEN

Objetivo: El artículo presenta el análisis de la eficacia clínica y causas de los resultados insatisfactorios de tratamiento quirúrgico de los pacientes con enfermedades degenerativas de la unión lumbosacra de la columna vertebral. Métodos: Dependiendo del método de la intervención quirúrgica sobre la unión lumbosacra, se asignaron tres grupos de pacientes: 1) (n = 352) - operado por el método de la discectomía microquirúrgica; 2) (n = 83) - operado con el uso de prótesis IVD artificiales; 3) (n = 183) - operado con el uso de fusión intersomática y estabilización rígida posterior. Para investigar las causas de los resultados insatisfactorios, un análisis de correlación de

Study conducted at the Irkutsk State Medical University, Irkutsk, Russia.
Correspondence: Irkutsk, PO, Russia. Box number 62. 664082. byval75vadim@yandex.ru

CC BY

http://dx.doi.org/10.1590/S1808-185120181703193838

Received on 04/04/2018, accepted on 07/25/2018

los resultados clínicos a largo plazo con parámetros instrumentales preoperatorios en el segmento operado, tácticas y complicaciones quirúrgicas se llevó a cabo. Resultados: Se determina que a largo plazo "buenos" resultados clínicos están asociados con parámetros individuales preoperatorios de la unión lumbosacra de la columna vertebral - desplazamiento lineal, angulación sagital, altura del espacio intersomático, grado de degeneración IVD por ADC. Conclusión: En enfermedades degenerativas de la unión lumbosacra de la columna vertebral, el análisis detallado de los resultados clínicos a largo plazo hace posible la identificación de las causas que afectan al desarrollo de los resultados insatisfactorios, que son cambios individuales morfoestructurales en el segmento lumbar inferior - la amplitud del ángulo segmentario, el ángulo de la lordosis lumbar, el grado del desplazamiento lineal de las vértebras, la altura del espacio intersomático y ADC. El complejo análisis clínico e instrumental nos permitió determinar posibles tácticas quirúrgicas. ***Nivel de Evidencia II; Estudios pronósticos - Investigación del efecto de características de un paciente sobre el desenlace de la enfermedad.***

Descriptores: Disco intervertebral; Articulación cigapofisaria; Enfermedad crónica; Discectomía; Fusión vertebral; Artroplastia.

INTRODUCTION

The dominant causes of the pain syndrome in the lumbar spine are associated with degeneration of the intervertebral discs (IVD), facet joints (FJ), or a combination of these facotrs.[1,2] Different puncture,[3,4] decompressive[5,6] and decompressive-stabilizing surgical procedures[7,8] are used to treat different stages of the formation of degenerative disease of the vertebral segment.

The most important practice in spinal surgery is interventions in the transitional zones of the spine, in particular in the lumbosacral spine.[9] In connection with biomechanical, anatomical and physiological features, this segment receives the greatest axial load and in the overwhelming majority of cases, is prone to degeneration.[10] Complications of surgical interventions in patients with degenerative diseases of the lumbosacral junction of the spine are verified up to 57% of cases.[11]

The outcomes of decompressive and decompressive-stabilizing surgical interventions of various authors differ significantly; on one hand, this is due to a lack of objective criteria for their use, and on the other hand, to a large number of structurally different implants.[12,13] This circumstance stimulates the development of approaches to predicting the degenerative process and determining the objective clinical and morphostructural parameters of the vertebral segment for performing personalized surgical tactics.[14,15]

Currently, the specialized literature presents little data on the clinical efficacy of various surgical techniques in isolated interventions in the lumbosacral spine.

The purpose of this study was to analyze the clinical efficacy and causes of unsatisfactory outcomes of surgical treatment of patients with degenerative diseases of the lumbosacral junction of the spine.

METHODS

The study was approved by the ethics committee of the Irkutsk State Medical University; each of the patients included in the study gave written informed consent – protocol No. 1 by January 13, 2010.

During the period from January 2007 to December 2012, 1342 decompressive and decompressive-stabilizing surgical interventions were performed in the lumbar spine at the Center for Neurosurgery of the "Railway Clinical Hospital" at the Irkutsk-Passenger Railway station of the Russian Railways. The study included 619 patients who underwent surgical interventions on the lumbosacral spine after a complex clinical and instrumental study. In all cases, the list of diagnostic procedures included the study of neurological and orthopedic status, spondylography, magnetic resonance imaging (MRI), multispiral computed tomography (MSCT), and electroneuromyography (ENMG) of the lower limbs.

The surgical interventions were performed in the presence of neurological signs of disco-radicular conflict and possible combination with reflex pain syndromes caused by hernias of the IVD, hypertrophy of the yellow ligament, and FJ arthrosis.

In 352 cases, microsurgical removal of the hernia of the IVD was performed by the Caspar method (group I), in 83 - discectomy through extraperitoneal pararectal access with implantation of the "M-6" disc prosthesis (Spinal Kinetics, USA) (group II), in 184 - unilateral facetectomy with or without contralateral foraminotomy, transforaminal spondylodesis using a "Capstone" cage (Medtronic, USA), and open transpedicular stabilization applying the "Conmet" system (Russia) through the median access; in a number of cases, reconstruction of the spinal canal was performed through the paramedian access in the volume of facetectomy with or without contralateral foraminotomy, and interbody fusion applying the "T-pal" cage (Synthesys, Switzerland) using the TLIF technique with combined transpedicular fixation. All patients were operated by the same surgical team, using original instrumentation.

After the operation, the follow-up catamnesis was a minimum of 24 months and a maximum of 48 months, with a median of 36 months. We studied anthropometric data (sex, age, body mass index), clinical parameters (the level of pain syndrome according to the visual analogue scale, patients' quality of life according to the Oswestry Disability Index (ODI) questionnaire, satisfaction with the results of the surgical treatment according to the Macnab scale), and instrumental parameters (for lumbar spondylography (height of interbody space, amplitude of segmental angle, angle of lumbar lordosis and degree of linear displacement of the vertebrae), according to MRI data (the degree of degenerative changes in IVD according to Pfirmann C. and FJ according to Fujiwara A., the quantitative characteristic of the degree of degeneration using the apparent diffusion coefficient (ADC)), and the presence of complications.

The data for ADC were obtained using a Siemens Magnetom Essenza MRI 1.5 T tomograph. The following set of parameters for the DW-MRI option with the SE-echo-planar image (EPI) was used: matrix 160 × 128, TR - 7500, TE - 83, NEX - 6, section thickness - 4 mm, FOV - 30 × 30. The following b values were used: b = 400 and 800 cm / mm2, the scan time was 6 minutes and 30 seconds. The DC was calculated on a T2-WI using the OsiriX Lite program, and the resulting values were transferred to the functional DWI maps. The DC was calculated on a T2-WI using the OsiriX Lite program, and the values obtained were transferred to the functional DWI maps.

Statistical processing of the results of the research was carried out on a personal computer using Microsoft Excel and Statistica-8 data processing software. To assess the significance of differences in sample populations, the criteria of nonparametric statistics were used and $p < 0.05$ was taken as the lower confidence limit. The data are represented by the median and interquartile range in the form of Me (25; 75).

RESULTS

General information about the studied patients

General characteristics of the study groups by sex, age and constitutional characteristics are presented in Table 1. When studying the data, it was found that among the operated patients, males were prevalent in the young and middle aged groups (25-50 years).

In the retrospective analysis of neurological symptoms prior to the surgical treatment of degenerative diseases of the lumbosacral junction of the spine, it was established that in all study groups, the radicular symptomatology with various degrees of neurological deficit was verified.

A study of the presence of anomalies of the lumbosacral junction of the spine using instrumental data in patients of the study groups revealed their absence in a higher number of respondents in all groups of operated patients, respectively: 81.5%, 95% and 69%.

The main types of pathomorphological substrate, according to the results of neuroimaging exams in degenerative diseases of the

lumbosacral junction of the spine in the patients under study, are shown in Table 2. In the analysis, it was found that in most of the operated patients (> 50%) the combined pathology of the IVDs and FJs was verified.

Analysis of clinical outcomes

Characteristics of the parameters of the patients under study by the level of pain syndrome, the index of movement limitation in the lumbar spine, and the degree of patient satisfaction with the performed operation are shown in Table 3.

Analysis of postoperative complications

Complications, identified in the retrospective analysis, depending on the time of their verification and the type of surgical intervention, are shown in Table 4.

A detailed analysis of complications was carried out, based on the choice of the method of surgical treatment. In all study groups, due to strict adherence to the protocol for the prevention of vascular complications (elastic bandaging of the lower limbs, anticoagulant therapy), no venous thrombosis or pulmonary embolism were detected.

In all patients groups with surgical interventions on the lumbosacral spine, various complications typical for surgical intervention and method of access were revealed. Thus, in the group of patients operated on by the method of microsurgical removal of herniated IVD, long-term adverse effects in the form of recurrent hernias of IVD and development of segmental instability were prevalent. In the group of patients operated on by the method of dynamic fixation, the lowest level of postoperative complications was revealed; mainly damage to the main vessels during access, infection of the postoperative wound, and the phenomena of heterotopic ossification. In the group of patients operated on by the method of rigid stabilization, complications related to degeneration of the adjacent segment, development of pseudoarthrosis, and instability of the fixation structure were determined.

Table 1. Distribution of patients by sex, age, and constitutional characteristics.

Criteria	Group I (n = 352)	Group II (n = 83)	Group III (n = 184)
age, yrs	30 (27;48)	29 (26;44)	32 (29;49)
Males (n, %)	214 (61%)	52 (63%)	119 (65%)
BMI (kg/^{2})	24,2 (22,3;25,9)	23,8 (22,1;26,2)	24,9 (23,3;25,8)

Note: BMI - body weight index.

Table 2. Type of dominant degenerative morphostructural changes based on MRI results in patients of the study groups.

Type of pathology	Morphological sign	Group I (n = 352)	Group II (n = 83)	Group III (n = 184)
Degeneration IVD	protrusion	34 (9,5 %)	49 (59 %)	31 (17 %)
	extrusion	197 (56%)	25 (30%)	74 (40%)
	sequestration	121 (34%)	9 (11%)	7 (4%)
	retrolisthesis	76 (22%)	17 (20%)	11 (6%)
Degeneration FJ	spondylarthrosis without spinal stenosis	162 (46%)	47 (57%)	35 (19%)
	spondylarthrosis with spinal stenosis	24 (7%)	-	84 (45%)
	spondylolisthesis I degree	4 (1%)	1 (1%)	29 (16%)

Table 3. Distribution of the patients under study by clinical outcomes of surgical treatment.

Criterion		Group I (n = 352)	Group II (n = 83)	Group III (n = 184)
VAS (lumbar spine) before surgery, mm		76 (64;80)	76 (64;82)	75 (62;82)
VAS (lumbar spine) in 24 months, mm		18.5 (11;31)	10.5 (6;14)	22 (16;30)
VAS (lower limbs) before surgery, mm		79 (67;83)	79.5 (66;87)	84 (67;89)
VAS (lower limbs) in 24 months, mm		14.5 (8;26)	8 (4;12)	18 (12;25)
ODI before surgery, score		76 (66;80)	78 (66;82)	74 (60;80)
ODI in 24 months, score		18.5 (14;22)	10 (8;14)	17 (14;20)
Macnab in 24 months	Excellent, n, %	34 (10)	41 (50)	26 (14)
	Good, n, %	187 (53)	36 (43)	88 (48)
	Satisfactory, n, %	113 (32)	6 (7)	53 (29)
	Unsatisfactory, n, %	18 (5)	-	17 (9)

Note: VAS – Visual Analogue Scale for pain. ODI – Functional state according to the Oswestry scale. Macnab – scale of subjective evaluation of treatment outcome.

Table. 4. Characteristics of the detected complications in the subgroups of the retrospective study.

Criterion	Group I (n = 352)	Group II (n = 83)	Group III (n = 184)
Intraoperative, n, %	14 (3.97%)	3 (3.6%)	8 (4.3%)
Trauma DM	3	-	3 (1.63%)
Damage to root	4	-	3 (1.63%)
Tool breakage	2	-	2 (1.08%)
Level error	2	-	-
Conversion of method	3	-	-
Damage to the main vessels	-	3 (3.6 %)	-
General Surgical, n, %	5 (1.42%)	4 (4.81%)	9 (4.89%)
Formation of postoperative hematoma	3	1	5
Infection of a postoperative wound	2	3	4
Venous thrombosis, PE	-	-	-
Specific, n, %	52 (14.77 %)	3 (3.6 %)	25 (13.6 %)
Spondylodisitis	1	-	-
Deterioration of neurologic symptoms	15	1	8
Recurrent hernia IVD	12	-	-
Formation of a herniated disc adjacent segment	3	-	9
Segmental instability	21	-	-
Pseudoarthrosis	-	-	7
Instability of the fixing structure	-	-	1
Heterotopic ossification	-	2	-

Note: DM - dura mater; PE - pulmonary embolism.

Analysis of clinical-biomechanical parameters of the affected vertebral-motor segments of patients, and their relationship with the outcome of surgical treatment

The leading clinical characteristics that have a direct relationship with the clinical postoperative outcome and the level of quality of life were the degree of pain syndrome according to VAS, and functional state (ODI). A correlation analysis of the above clinical components and parameters was performed, characterizing the state of the lumbosacral junction of the spine: amplitude of the segmental angle, angle of the lumbar lordosis, degree of linear displacement of the vertebrae, height of the interbody space, and ADC. A significant positive nonparametric correlation was revealed between the values for long-term outcomes of surgical treatment by VAS and ODI with the parameters studied ($R > 0.5$, $p < 0.05$).

In order to conduct a detailed analysis of the effect of the clinical and instrumental parameters on the clinical outcome, and study the possibility of optimizing the tactics of treating patients with degenerative diseases of the lumbosacral junction of the spine, the results of the study were divided by postoperative outcomes, as follows:

- "good", characterized by a complete or near-complete return to the previous levels (before the onset of the disease or before the last exacerbation) of social and physical activity (possible limitation of large physical exertion);
- "unsatisfactory", household and social activity is not fully restored, no effect after the surgery or deterioration of the state.

A comparison of the clinical and instrumental data of patients in the study groups is shown in Table 5.

Table 5. Comparative analysis of clinical data depending on the postoperative outcome of the study patients groups.

Criterion	Group I (n = 352)		Group II (n = 83)		Group III (n = 184)	
	"good" outcomes (n = 298)	"unsatisfactory" outcomes (n = 64)	"good" outcomes (n = 79)	"unsatisfactory" outcomes (n = 4)	"good" outcomes (n = 101)	"unsatisfactory" outcomes (n = 83)
ODI 36 months	12 (10;16)	26 (20;28) *	8 (6;10)	12 (10;14) *	14 (12;18)	30 (24;36) *
VAS lumbar spine 36 months	11.5 (9;13)	22.5 (19;30) *	6 (4;8)	13 (10;18) *	12 (10;16)	32 (20;34) *
VAS lower limbs 36 months	6.5 (4;9)	25.5 (18;35) *	2 (2;4)	10 (6;16) *	10 (6;12)	28 (20;36) *
LT before surgery	2 (1;2)	4 (3;6) *	2 (1;4)	6 (5;7) *	7 (4;11)	3 (2;3) *
LT after surgery	2 (1;3)	7 (6;8) *	1 (1;2)	2 (1;2)	2 (1;3)	5 (4;7) *
SA before surgery	4 (3;5)	6 (6;7) *	4 (3;5)	7 (6;11) *	7 (6;7)	3 (2;3) *
SA after surgery	3 (3;4)	8 (6;8) *	4 (4;5)	3 (3;5)	4 (2;6)	3 (3;4)
General lordosis before surgery	32 (28;34)	30 (26;32)	30 (28;36)	30 (26;38)	32 (28;36)	32 (23;38)
General lordosis after surgery	34 (26;36)	28 (24;34)	54 (48;64)	34 (32;36) *	52 (44;66)	37 (32;38) *
Disc height before surgery	12 (11;14)	8 (7;10) *	10 (9;13)	6 (5;9) *	6 (5;8)	10 (9;12) *
Disc height after surgery	10 (10;12)	6 (5;7) *	12 (10;12)	10 (10;12)	12 (10;14)	11 (10;13)
ADC	1720 (1600;1830)	1300 (1190;1480) *	1540 (1280;1760)	1050 (800;1150) *	1180 (980;1230)	1320 (1240;1520) *

Note: LD – linear translation; SA – sagittal angulation; ADC – apparent coefficient diffusion; * - the reliability of differences between the groups studied at the same stages of the study.

The analysis found that

In the group of patients operated on using the technique of microsurgical removal of the hernia of IVD, "good" outcomes are associated with the following preoperative parameters of the lumbosacral junction of the spine: LT - no more than 2 mm., sagittal volume of movements - no more than 6^0, lowering the height of the interbody space no more than 1/3 of the overlying, I and II degree of IVD degeneration by ADC.

In the group of patients operated on using the technique of dynamic fixation, "good" outcomes are associated with the following preoperative parameters of the lumbosacral junction of the spine: LD - no more than 4 mm., sagittal volume of movements - no more than 6^0, lowering the height of the interbody space no more than 2/3 of the overlying, II and IV degree of IVD degeneration by ADC.

In the group of patients operated on using the technique of rigid stabilization, "good" outcomes are associated with the following preoperative parameters of the lumbosacral junction of the spine: LT - more than 4 mm., sagittal volume of movements - more than 6^0, lowering the height of the interbody space more than 2/3 of the overlying, IV and V degree of IVD degeneration by ADC.

DISCUSSION

The different degrees of degenerative changes in the lumbar segments is an indication for the use of a variety of surgical technologies.[3] In each clinical situation, it is necessary to determine the optimal indications for performing an operative intervention. The promotion of minimally invasive methods for treating degenerative diseases led to the widespread introduction of microsurgical (subtotal) discectomy. The long-term outcomes of using the above-mentioned method testify to its lack of clinical effectiveness.[16,17]

Currently, the most common method of surgical treatment of degenerative diseases of the lumbar spine is interbody fusion and rigid stabilization, whereby successful clinical outcomes do not correlate with radiographic outcomes.[2,7] Rigid stabilization leads to biomechanical stress of adjacent segments with their accelerated degeneration, contributing to the formation of bone block failure, development of infectious complications, postoperative pain syndrome, instability of fixation elements, and resorption of bone tissue around the implants.[1,2,18]

The study of technical capabilities aimed at reducing the unsatisfactory outcomes of rigid stabilization is associated with protection of adjacent segments from biomechanical overload, a reduction in the risk of breakage of the fixing structure, and elimination of pathological mobility, with preservation of the physiological volume of movements in the operated segment.[2,19] It is determined that the posterior dynamic stabilization allows the physiological volume of movements in the lumbar spine to be restored, and reduces the degeneration of the adjacent segment.[12,20] In modern specialized literature there are data on positive clinical postoperative outcomes, but the biomechanical effects of using various stabilizing structures are contradictory.[12,18]

Dynamic fixation using artificial IVD is aimed at restoring spatial relationships and biomechanics in the operated segments of the spine, if there are no significant morphostructural changes in its support elements. In connection with this, a detailed preoperative examination of patients is necessary, taking into account modern neuroimaging methods of examination.[21,22]

When analyzing the specialized literature, we did not observe any fundamental differences in the clinical outcomes of VAS and ODI in each of the surgical correction groups.[3,7,8] At the same time, in this study, lower indicators for the level of pain in the lumbar and lower limbs and quality of life by ODI were determined in a group of patients operated with the application of artificial IVD M-6.

The study confirmed the presence of the most common complications after microsurgical discectomy - recurrence of hernias of the IVD and segmental instability;[6,17] after total arthroplasty - damage to the main vessels and heterotopic ossification,[23,24] after rigid stabilization - degeneration of adjacent segments, pseudoarthrosis, and postoperative scar process.[7,8]

Determination of prognostic factors and the relationship of long-term postoperative outcomes with clinical and instrumental preoperative changes in the area of planned surgical intervention is currently relevant.

The complex study of various morphostructural factors determined by instrumental data, and which influence the long-term clinical outcome, make it possible to manage and monitor the long-term postoperative outcome in patients with degenerative diseases of the lumbosacral junction of the spine.

CONCLUSION

Lesions of the lumbosacral spine constitute a complex group of degenerative diseases, and determining the best surgical conduct requires a comprehensive clinical and instrumental analysis.

In spite of the overall clinical effectiveness of surgical interventions, the detailing of long-term outcomes enabled us to identify the causes that influence the development of unsatisfactory outcomes; which are the individual morphostructural features of the lower lumbar VMS - the amplitude of the segmental angle, the lumbar lordosis angle, the degree of linear displacement of the vertebrae, the height of the interbody space, and the ADC.

The development of a detailed algorithm of tactics and a multicenter study of its implementation, are current trends in spinal surgery that will improve the outcomes of surgical treatment of patients with degenerative diseases of the lumbosacral junction of the spine.

All authors declare no potential conflict of interest related to this article.

CONTRIBUTION OF THE AUTHORS: Each author made significant individual contributions to this manuscript. VAB (0000-0003-4349-7101)* and SSR (0000-0002-2796-5692)* were the main contributors in the drafting of the manuscript. AAK (0000-0001-9039-9147)* and YYP (0000-0003-2633-7149) performed the surgery, followed up the patients and gathered clinical data. MAA (0000-0002-7676-1127)* evaluated the data from the statistical analysis. SVS (0000-0002-6634-1727)*, AAK and VAB performed the literature search and review of the manuscript, and contributed to the intellectual concept of the study. *ORCID (Open Researcher and Contributor ID).

REFERENCES

1. Kalinin AA, Byvaltsev VA. Relationship between vertebral metric parameters and outcome of surgical treatment of degenerative spondylolisthesis with multilevel lumbar intervertebral disc lesions. Spine surgery. 2015;4:56–62. [In Russian].
2. Krutko AV. Comparative analysis of the results of posterior interbody fusion (PLIF) and transforaminal interbody fusion (TLIF) in combination with transpedicular fixation. Herald of traumatology and orthopedist. them. N.N. Priorov. 2012;1:12–21. [In Russian]
3. Feng F, Xu Q, Yan F, Xie Y, Deng Z, Hu C et al. Comparison of 7 Surgical Interventions for Lumbar Disc Herniation: A Network Meta-analysis. Pain Physician. 2017;20(6):E863-71.
4. Song H, Hu W, Liu Z, Hao Y, Zhang X. Percutaneous endoscopic interlaminar discectomy of L5-S1 disc herniation: a comparison between intermittent endoscopy technique and full endoscopy technique. J Orthop Surg Res. 2017;12(1):162.
5. Faldini C, Perna F, Chehrassan M, Borghi R, Stefanini N, Traina F. Surgical tricks for open lumbar discectomy. Eur Spine J. 2017;26(Suppl 3):425-6.
6. Teli M, Lovi A, Brayda-Bruno M, Zagra A, Corriero A, Giudici F et al. Higher risk of dural tears and recurrent herniation with lumbar micro-endoscopic discectomy. Eur Spine J. 2010;19(3):443-50.
7. Byvaltsev VA, Kalinin AA, Belykh EG, Sorokovikov VA, Shepelev VV. Optimization of segmental lumbar spine instability treatment using minimally invasive spinal fusion technique. Questions of neurosurgery. 2015;3:45–54. [In Russian]
8. Hoff EK, Strube P, Pumberger M, Zahn RK, Putzier M. ALIF and total disc replacement versus 2-level circumferential fusion with TLIF: a prospective, randomized, clinical and radiological trial. Eur Spine J. 2016;25(5):1558-66.
9. Kolesov SV, Kolbovsky DA, Kazmin AI, Morozova NS. Application of nitinol rods in surgical treatment of dehenerative spine diseases with fixation of the lumb-cross transition. Spine surg. 2016;13(1):41–9. [In Russian]
10. Bydon M, Xu R, Santiago-Dieppa D, Macki M, Sciubba DM, Wolinsky JP et al. Adjacent-segment disease in 511 cases of posterolateral instrumented lumbar arthrodesis: floating fusion versus distal construct including the sacrum. J Neurosurg Spine. 2014;20(4):380–6.
11. Hashem S, Abdelbar A, Ibrahim H, Alaa-Eldin Habib M, Abdel-Monem A, Hamdy H. Review of device and operator related complications of transpedicular screw fixation for the thoracic and lumbar regions. Egypt J Neurol Psychiat Neurosurg. 2012;49(4):393–8.
12. Kaner T, Sasani M, Oktenoglu T, Cosar M, Ozer AF. Utilizing dynamic rods with dynamic screws in the surgical treatment of chronic instability: a prospective clinical study. Turk Neurosurg. 2009;19(4):319–26.
13. Sköld C, Tropp H, Berg S. Five-year follow-up of total disc replacement compared to fusion: a randomized controlled trial. Eur Spine J. 2013;22(10):2288–95.
14. Konovalov NA, Shevelev IN, Kornienko VN, Nazarenko AG. Clinical and diagnostic evaluation of the severity of degenerative lesion of the lumbosacral spine. Annals of clinical and experimental neurology. 2009;3(3):16–21. [In Russian]
15. Belykh E, Krutko AV, Baykov ES, Giers MB, Preul MC, Byvaltsev VA. Preoperative estimation of disc herniation recurrence after microdiscectomy: predictive value of a multivariate model based on radiographic parameters. Spine J. 2017;17(3):390-400.
16. Caspar W, Campbell B, Barbier DD, Kretschmmer R, Gotfried Y. The Caspar microsurgical discectomy and comparison with a conventional standard lumbar disc procedure. Neurosurgery. 1991;28(1):78–86.
17. Castro-Menéndez M, Bravo-Ricoy JA, Casal-Moro R, Hernández-Blanco M, Jorge-Barreiro FJ. Midterm outcome after microendoscopic decompressive laminotomy for lumbar spinal stenosis: 4-year prospective study. Neurosurgery. 2009;65(1):100-10.
18. Ozer F, Yaldiz C, Ozkal B, Guvenc Y, Senturk S, Erbulut D et al. Comparison of the Rigid Rod System with Modular Plate with the Finite Element Analysis in Short-Segment Posterior Stabilization in the Lower Lumbar Region. Turk Neurosurg. 2017;27(4):610–6.
19. Imada AO, Huynh TR, Drazin D. Minimally Invasive Versus Open Laminectomy/Discectomy, Transforaminal Lumbar, and Posterior Lumbar Interbody Fusions: A Systematic Review. Cureus. 2017;9(7):e1488.
20. Bothmann M, Kast E, Boldt GJ, Oberle J. Dynesys fixation for lumbar spine degeneration. Neurosurg Rev. 2008;31(2):189–96.
21. Belykh EG, Kalinin AA, Patel AA, Miller EJ, Bohl MA, Stepanov IA et al. Apparent diffusion coefficient maps in the assessment of surgical patients with lumbar spine degeneration. PLoS ONE. 2017;12(8): e0183697.
22. Yu HJ, Bahri S, Gardner V, Muftuler LT. In vivo quantification of lumbar disc degeneration: assessment of ADC value using a degenerative scoring system based on Pfirrmann framework. Eur Spine J. 2015;24(11):2442-8.
23. Kim J, Kim Y, Jeong WK, Song SY, Cho OK. Heterotopic ossification developing in surgical incisions of the abdomen: analysis of its incidence and possible factors associated with its development. J Comput Assist Tomogr. 2008;32(6):872–6.
24. Le Huec JC, Mathews H, Basso Y, Aunoble S, Hoste D. Clinical results of Maverick lumbar total disc replacement: two-year prospective follow-up. Orthop Clin North Am. 2005;3(6):315–22.

COMPLICATIONS OF SURGICAL TREATMENT OF LUMBAR STENOSIS IN THE EARLY POSTOPERATIVE PERIOD

COMPLICAÇÕES DO TRATAMENTO CIRÚRGICO DA ESTENOSE LOMBAR NO PERÍODO PÓS-OPERATÓRIO IMEDIATO

COMPLICACIONES DEL TRATAMIENTO QUIRÚRGICO DE LA ESTENOSIS LUMBAR EN EL PERÍODO POSTOPERATORIO TEMPRANO

Igor Vadimovich Basankin[1,2], Vladimir Alexeevich Porkhanov[1,2], Asker Alievich Afaunov[1,2], Alexander Veniaminovich Kuzmenko[1], Vladimir Konstantinovich Shapovalov [1]

1. Research Institute Krasnodar Regional Hospital 1, Krasnodar, Russia .
2. Kuban State Medical University, Krasnodar, Russia.

ABSTRACT

Objective: To analyze the structure of degenerative lumbar stenosis surgical treatment complications and to analyze their effect on the results and indications for revision operations. Methods: Between 2009 and 2013, 513 patients with lumbar stenosis of degenerative etiology were surgically treated. There were 205 men, 308 women, aged 23 to 74 years. The main clinical manifestations were persistent compression radiculopathy, chronic pain in the back and lower limbs, and difficulty walking. The intensity of the pain was assessed by the VAS. At the time of hospitalization, VAS was 55-90 points. Results: Of the 513 operated patients, 65 (12.67%) had complications in the early postoperative period (up to three months after the operation); intraoperative complications occurred in 26 (5.1%) patients; intraoperative dura mater injury occurred in 24 (4.67%); pulmonary embolism (PE) occurred in 2 (0.39%) patients; 39 patients had early postoperative complications; acute radiculopathy occurred in 22 patients (4.28%); and 17 patients (3.31%) had surgical wound complications. Conclusions: Liquorrhea, postoperative hematomas and acute radiculopathy had no negative effect on the results of treatment in any of the cases. In the early postoperative period, 4 (0.77%) deaths were recorded intraoperatively and in 2 (0.39%) cases, intraoperative PE occurred. Two cases (0.39%) resulted in sepsis and multiple organ failure. In eight (1.55%) patients, the results of the treatment were unsatisfactory: in 4 (0.77%) cases due to death, and in a further 4 (0.77%) due to elimination of the system by the spinal column as a result of suppuration. ***Level of Evidence IV; Therapeutic studies – Investing the results of treatment.***

Keywords: Spinal stenosis; Postoperative period/complications; Suppuration.

RESUMO

Objetivo: Analisar a estrutura das complicações do tratamento cirúrgico da estenose lombar degenerativa e analisar seu efeito nos resultados e indicações para operações de revisão. Métodos: Nos anos de 2009-2013, 513 pacientes com estenose lombar de etiologia degenerativa foram tratados cirurgicamente. Havia 205 homens, 308 mulheres com idades entre 23 e 74 anos. As principais manifestações clínicas foram radiculopatia por compressão persistente, dor crônica nas costas e membros inferiores, dificuldade para andar. A intensidade da dor foi avaliada pela EAV. No momento da hospitalização, a EVA foi de 55 a 90 pontos. Resultados: Entre os 513 pacientes operados, 65 (12,67%) tiveram complicações do pós-operatório imediato (até três meses após a operação ocorreram complicações intraoperatórias em 26 (5,1%) pacientes. A lesão intra operatória da dura-máter ocorreu em 24 (4,67%); embolia pulmonar (EP) ocorreu em dois (0,39%) pacientes, 39 pacientes com complicações pós-operatórias precoces, radiculopatia aguda em 22 pacientes (4,28%) e 17 pacientes (3,31%) com complicações da ferida. Os hematomas pós-operatórios e a radiculopatia aguda tiveram efeito negativo sobre os resultados do tratamento em nenhum caso. No período pós-operatório imediato, 4 (0,77%) dos óbitos foram registrados no período intra operatório e em dois (0,39%) casos o PE intra operatório. Em dois casos (0,39%) foram motivo de sepse e falência múltipla de órgãos, sendo que em oito (1,55%) pacientes foram encontrados resultados insatisfatórios: em quatro (0,77%) devido à morte – e em quatro devido à remoção dos sistemas da coluna por causa de supuração. ***Nível de Evidência IV; Estudos terapêuticos – investigação dos resultados do tratamento.***

Descritores: *Estenose espinal; Período pós-operatório/complicações; Supuração.*

RESUMEN

Objetivo: Analizar la estructura de las complicaciones del tratamiento quirúrgico de la estenosis lumbar degenerativa y analizar su efecto sobre los resultados y las indicaciones para las operaciones de revisión. Métodos: En 2009-2013 513 pacientes con estenosis lumbar de etiología degenerativa fueron tratados quirúrgicamente. Hubo 205 hombres, 308 mujeres, de 23 a 74 años. Las principales manifestaciones clínicas fueron radiculopatía por compresión persistente, dolor crónico en la espalda y las extremidades inferiores, y dificultades para caminar. La intensidad del dolor fue evaluada por EVA. En el momento de la hospitalización, la EVA tenía 55-90 puntos. Resultados: Entre los 513 pacientes operados, 65 (12,67%) tuvieron complicaciones en el período postoperatorio temprano (hasta tres meses después de la operación); hubo complicaciones intraoperatorias en 26 (5,1%) pacientes; lesión duramadre intraoperatoria ocurrió en 24 (4,67%); embolia pulmonar (EP) se presentó en dos pacientes (0,39%); hubo 39 pacientes con complicaciones postoperatorias tempranas; en 22 (4,28%)

Study conducted at the Krasnodar Regional Hospital 1, Krasnodar, Russia.
Correspondence: Krasnodar, Russia. 1 may str. 167. 350086. basankin@rambler.ru

http://dx.doi.org/10.1590/S1808-185120181703200487

Received on 05/23/2018 accepted on 08/27/2018

radiculopatía aguda y en 17 (3,31%) complicaciones en la herida. Conclusiones: Liquorrea, hematomas postoperatorios y la radiculopatía aguda no tuvieron efecto negativo en los resultados del tratamiento en ninguno dos casos. En el período postoperatorio temprano se registraron cuatro (0,77%) muertes intraoperatorias y en dos (0,39%) casos se trató de una PE intraoperatoria. Dos casos (0,39%) resultaron en sepsis y falla orgánica múltiple. Se observaron resultados de tratamiento insatisfactorios en ocho (1,55%) pacientes: en 4 (0,77%) - debido a la muerte, y en cuatro (0,77%) - debido a eliminación del sistema por la espina dorsal debido a supuración. ***Nivel de evidencia IV; Estudios terapéuticos – Investigación de los resultados del tratamiento.***

Descriptores: *Estenosis Espinal; Periodo Posoperatorio/complicaciones; Supuración.*

INTRODUCTION

Lumbar stenosis of degenerative etiology is one of the most common causes of progressive functional deadaptation of the spine. According to the literature,[1-6] lumbar stenosis occurs in 6 to15% of patients with chronic back pain. The averaged number of annual operations for lumbar stenosis in Western Europe is 114-132 per 1,000,000 people.[4] There are various surgical approaches aimed at eliminating degenerative spinal stenosis, but the choice of technique is still a matter of debate.[3,5] Dorsal root decompression in combination with transpedicular fixation and interbody spondylodesis, performed via posterior or posterolateral access to the intervertebral discs (PLIF or TLIF), has recently become widespread.

The effectiveness of surgical treatment for certain forms of degenerative lumbar stenosis is beyond doubt. However, the complications of such operations are as high as 20%.[2,7] Complications in the early postoperative period include a worsening of the vertebrogenic algic syndrome, postoperative liquorrhea, and suppuration of the operating wound. Complications in the later postoperative period include instability of fixation structures, late suppuration, and progression of dystrophic processes to adjacent vertebral motor segments.[8,9] In some cases, these complications can be easily eliminated and do not affect the results of the treatment. In others, the complications may necessitate revision surgery, with a negative impact on the results, and even mortality. The aim of this study was to analyze the structure of degenerative lumbar stenosis surgical treatment complications, their effect on the results, and indications for revision operations.

METHODS

Between 2009 and 2013, 513 patients with lumbar stenosis of degenerative etiology were surgically treated. The protocol of acceptance in the Ethics Committee n. 27. An Informed Consent Form was signed by all the participants. There were 205 men and 308 women, with ages from 23 to 74 years. All patients had had the disease more than 5 years. The main clinical manifestations at the time of treatment in the clinic were persistent compression radiculopathy, chronic pain in the back and lower limbs, and difficulty walking. The intensity of the pain was assessed by the VAS. At the time of hospitalization, the VAS was 55-90 points. The functional deadaptation was scored using the Oswestry Low Back Pain Disability Questionnaire (ODI).[2] In all patients, the diagnosis was confirmed by MRI and/or CT. In all cases, there were combined morphological causes of narrowing of the vertebral, lateral and foraminal canals. The concomitant somatic pathology, which required preclinical preoperative preparation, was recorded in 95 (18.6%) patients.

RESULTS

The immediate treatment within three months after operations were studied in 493 (96.1%) patients. Elimination of the clinical manifestations of radiculopathy and back pain (VAS 0-5 points) was completely achieved in 229 (46.45%) patients. Another 178 (36.1%) patients noted the absence of manifestations of radicular syndromes while continuing to have low back pain on physical exertion (VAS to 20 points). A significant reduction in radicular pain and low back pain (VAS 20-35 points) was achieved in 86 (17.44%) patients. Life indicators of these patients improved significantly, and the pain was scored according to the Oswestry Low Back Pain Disability Questionnaire (with scores improving by an average of 48 points). Of the 513 operated patients, 65 (12.67%) had complications in the early postoperative period (up to three months after the operation).

There are 26 complications, 2 PE and 24 dura mater injurys. Among the 24 injurys of the dura mater, which we took as 100% (24 wounds), 11 of 24 (45.83%) patients had dura mater injury during TLIF or PLIF. These injuries occurred in cases where there was epidural fibrosis that, in our opinion, was a consequence of previous surgery (6 cases), or of an extended period of vertebral disc-radicular conflict (five cases). In 13 (54.16%) patients, the intraoperative dura mater injuries could be explained by technical difficulties associated with decompression at a critical value of combined degenerative stenosis.

If the injuries were in the visual inspection area, the defect was sutured. If the injuries were out of sight, they were sealed using Bioglue. Liquorrhea was successfully eliminated in 14 (58.33%) cases out of 24 (100%). In 10 (41.67%) patients, it was not possible to completely eliminate the liquorrhea. In these situations, patients were prescribed antibacterial therapy. Drainage tubes were left in for up to 4-5 days after surgery, and the small holes left after their removal were closed tightly as by suturing. In 7 cases, this technique successfully prevented seepage of cerebrospinal fluid. In 3 patients, cerebral spinal fluid continued to seep through the drainage holes. In these patients, lumbar cerebral drainage was inserted for four to six days and the wound was re-sutured. Thus, in all ten patients, the liquorrhea was eliminated in the early postoperative period. Intraoperative massive pulmonary embolism occurred in 2 (0.39%) patients during the completion of the final stage of four-segment TLIF, resulting in the deaths of the patients. It should be noted that fatal intraoperative PE was recorded in patients who did not have high risk factors against a background of standard preventive therapy.

There were 39 patients with early postoperative complications. Acute radiculopathy occurred in 22 patients (4.28%). These 22 cases of postoperative radiculopathy were taken as 100%. In 19 (86.36%) patients, it was eliminated with conservative therapy combined with physiotherapy and exercise therapy. The conservative treatment was ineffective in 3 patients (13.60%). CT and/or MRI revealed the cause of acute radicular syndrome: in 2 (9%) cases it was caused by incorrectly implanted screws; in one (4.54%) case, the osteophytic articular facet was not completely removed. Revision decompressive operations were performed, eliminating the radiculopathy. The complications had no effect on the results.

In 17 patients (3.31%), there were wound complications. In three patients (0.58%) a hematoma formed at the surgical site, necessitating a revision surgery. Suppuration of the surgical wound in the early postoperative period occurred in 14 (2.72%) patients. Stepwise surgery, step-by-step included necroctomy, active drainage of the wound with vacuum dressings, and replacement and subsequent application of secondary sutures. In 2 (0.38%) patients, wound suppuration occurred in the early postoperative period following the TLIF, which was performed in three and four spinal segments, causing sepsis, bilateral pneumonia and multiple organ failure. Early suppuration was stopped and the metal construction was saved in 10 (71.42%) out of the 14 (100%) cases. In 4 (28.58%) cases, removal of metal construction was required, and in 2 (14.28%) cases, the metal construction was removed as a result of generalization of wound infection.

DISCUSSION

The most dangerous intraoperative complications in the early postoperative period leading to lethal outcomes were PE and suppuration of the postoperative wound, followed by generalization of wound infection leading to sepsis. Complications in the early postoperative period leading to unsatisfactory treatment results were suppuration of the operating wound, with early destabilization of the metal fixators and their removal. Other complications (liquorrhea, acute radiculopathy, postoperative hematomas, and early suppuration without destabilization of the spinal system) did not adversely affect the results of treatment, although in some cases, they served as indications for revision operations.

CONCLUSION

Liquorrhea, postoperative hematomas and acute radiculopathy had no negative effect on the results of treatment in any of the cases. In the early postoperative period, four (0.77%) deaths were recorded intraoperatively. Two (0.39%) cases were due to an intraoperative PE. Two cases (0.39%) were due to sepsis and multiple organ failure. Unsatisfactory treatment results were observed in eight (1.55%) patients: in 4 (0.77%) due to death, in 4 (0.77%) due to removal of the spinal system as a result of suppuration.

All authors declare no potential conflict of interest related to this article.

CONTRIBUTION OF THE AUTHORS: Each author made significant individual contributions to this manuscript. IVB (0000-0003-3549-0794)* and VAP (0000-0003-2732-2133)* were the main contributors to the drafting of the manuscript. IVB, AAA (0000-0001-7976-860X)*, AVK (0000-0002-2741-7338)*, VKS (0000-0003-4556-251X)* performed the surgery, followed up the patients, and gathered clinical data. VKS evaluated the data from the statistical analysis. AAA, AVK and VAP performed the literature search and review of the manuscript, and contributed to the intellectual concept of the study. *ORCID (Open Researcher and Contributor ID).

REFERENCES

1. Airaksinen O, Brox JI, Cedraschi C, Hildebrandt J, Klaber-Moffett J, Kovacs F et. al. Chapter 4. European guidelines for the management of chronic nonspecific low back pain. Eur Spine J. 2006;15(Suppl. 2):S192-300.
2. Mirza SK, Deyo RA. Systematic review of randomized trials comparing lumbar fusion surgery to nonoperative care for treatment of chronic back pain. Spine (Phila Pa 1976). 2007;32(7):816-23.
3. Breivik, Collett B, Ventafridda V, Cohen R, Gallacher D. Survey of chronic pain in Europe: prevalence, impact on daily life, and treatment. Eur J Pain. 2006;10(4):287– 333.
4. Byvaltsev V, Krutko A, Shepelev V et.al. Results of staged surgical treatment of patients with tandem-stenosis of the cervical and lumbosacral spine. Hirurgia Pozvonochnika. 2017;14(2):50–62. (In Russian)
5. Brodke D, Annis P, Lawrence B, Woodbury AM, Daubs MD. Reoperation and revision rates of 3 surgical treatment methods for lumbar stenosis associated with degenerative scoliosis and spondylolisthesis. Spine (Phila Pa 1976). 2013;38(26):2287-94.
6. Afaunov A, Basankin I. Kuzmenko A, Shapovalov V. Complications of surgical treatment of degenerative lumbar stenosis. Hirurgia Pozvonochnika. 2016;13(4):66-72.
7. Prodan AI, Perepechay OA, Kolesnichenko VA, Balan SI, Chernyshev AG. Complications of surgical treatment for lumber spinal stenosis. Hirurgia Pozvonochnika. 2009;(1):31–7.
8. Handy AV, Shanko GG. Neuro-orthopedic and Orthopedic neurological syndromes in children and adolescents. Minsk: Harvest, 1998.
9. Kleinstueck FS, Diederich CJ, Nau WH, Puttlitz CM, Smith JA, Bradford DS et. al. Acute biomechanical and histological effects of intradiscal electrothermal therapy on human lumbar discs. Spine (Phila Pa 1976). 2001;26(20):2198–207.

OUTCOMES OF SURGICAL TREATMENT OF LUMBAR DISK HERNIATION USING AN ANNULAR CLOSURE DEVICE

DESFECHOS DO TRATAMENTO CIRÚRGICO DA HÉRNIA DE DISCO LOMBAR COM APARELHO DE FECHAMENTO ANULAR

RESULTADOS DEL TRATAMIENTO QUIRÚRGICO DE LA HERNIA DE DISCO LUMBAR UTILIZANDO UN DISPOSITIVO DE CIERRE ANULAR

Sanginov Abdugafur Jabborovich[1], Krutko Aleksandr Vladimirovich[1], Baykov Evgenii Sergeevich[1], Lutsik Anatoliy Andreevich[2]

1. Novosibirsk Research Institute of Traumatology and Orthopaedics (NRITO) n.a. Ya.L. Tsivyan, Novosibirsk, Russia.
2. Novokuznetsk State Institute of Advanced Medical Education, Novokuznetsk, Russia.

ABSTRACT

Objective: The aim of the study was to investigate the clinical and radiological results of using the annular closure device in patients with lumbar disc herniation (LDH). Methods: The study involved 120 patients with LDH operated on by limited discectomy and annular closure using the Barricaid device. A literature review was conducted to evaluate the effectiveness of the annuloplasty. Results: All patients showed postoperative regression of the radicular pain syndrome and were mobilized on the day of surgery. The correlation between the removed nucleus pulposus and changes in DHI was studied by linear regression. The results revealed that disc height loss is directly correlated with the volume of removed nucleus pulposus ($p < 0.05$). Modic changes were present in 22 (22%) patients. Endplate changes (resorption and erosion) were present in 25 patients (20.7%). We found that these changes in MR and CT images have no effect on the clinical presentation of the disease. No intraoperative complications, such as severe hemorrhage requiring blood transfusion, or injury to the dura mater or nerve roots, were observed in our case series. Postoperative complications occurred in 3 (2.5%) patients. The reoperation rate was 4.2%. Conclusions: The use of the Barricaid annular closure device in 120 patients with lumbar disc herniation and high risk of recurrent herniation showed good clinical and radiographic outcomes. The reoperation rate in our study was 2.5%; disc reherniation at the operated level was observed in 1.7% of patients. This is a good outcome compared to the data reported for patients having a high risk of disc reherniation. ***Level of Evidence IV; Case series.***

Keywords: Intervertebral disc displacement; Annulus fibrosus; Diskectomy; Bone plate.

RESUMO

Objetivo: O objetivo do estudo foi estudar os resultados clínicos e radiológicos do uso do dispositivo de fechamento anular em pacientes com hérnia discal lombar (HDL). Métodos: O estudo envolveu 120 pacientes com LDH operados por discectomia limitada e fechamento anular usando o dispositivo Barricaid. Uma revisão da literatura foi realizada para avaliar a eficácia da anuloplastia. Resultados: Todos os pacientes apresentaram regressão pós-operatória da síndrome da dor radicular e foram mobilizados no dia da cirurgia. A correlação entre o núcleo pulposo removido e as alterações no DHI foi estudada por regressão linear. Revelou-se que a perda de altura discal está diretamente correlacionada com o volume do núcleo pulposo removido ($p < 0,05$). Alterações modicadas reveladas em 22 (22%) pacientes. As alterações no endplate foram reveladas em 25 pacientes (20,7%). Descobrimos que essas mudanças nas imagens de RM e TC não têm efeito sobre a apresentação clínica da doença. Não foram observadas complicações intraoperatórias, como hemorragia grave que necessitou de transfusão sanguínea, lesão da dura-máter ou raízes nervosas, em nossa casuística. Complicações pós-operatórias foram reveladas em 3 (2,5%) pacientes. A taxa de reoperação foi de 4,2%. Conclusão: O uso do dispositivo de fechamento anular Barricaid em 120 pacientes com hérnia discal lombar e alto risco de hérnia recorrente mostrou bons resultados clínicos e radiográficos. A taxa de reoperação em nosso estudo foi de 2,5%; reinteriato discal no nível operado foi observado em 1,7% dos pacientes. É um bom resultado comparado aos dados relatados para pacientes com alto risco de reintervenção com disco. ***Nível de evidência IV; Série de casos.***

Descritores: *Deslocamento do Disco Intervertebral, Anel Fibroso, Discotomia, Placas Ósseas.*

RESUMEN

Objetivo: El objetivo del estudio fue estudiar los resultados clínicos y radiológicos del uso del dispositivo de cierre anular en pacientes con hernia de disco lumbar (LDH). Métodos: El estudio involucró a 120 pacientes con LDH operados por discectomía limitada y cierre anular usando el dispositivo Barricaid. Se realizó una revisión de la literatura para evaluar la efectividad de la anuloplastia. Resultados: Todos los pacientes mostraron regresión postoperatoria del síndrome de dolor radicular y se movilizaron el día de la cirugía. La correlación entre el núcleo pulposo retirado y los cambios en DHI se estudiaron mediante regresión lineal. Los resultados revelaron que la pérdida de altura del disco se correlaciona directamente con el volumen del núcleo pulposo retirado ($p < 0,05$). Cambios módicos revelados en 22 (22%) pacientes. Los cambios de placa terminal (resorción y erosión) se revelaron en 25 pacientes (20,7%). Descubrimos que estos cambios en las imágenes de RM y TC no tienen ningún efecto sobre la presentación clínica de la enfermedad. En nuestra serie de casos no se

Study conducted at the Novosibirsk Research Institute of Traumatology and Orthopaedics (NRITO) n.a. Ya.L. Tsivyan, Novosibirsk, Russia.
Correspondence: Aleksandr V. Krutko. Neurosurgery Department of NRITO, Frunze str., 17, Novosibirsk, 630091, Russia. ortho-ped@mail.ru

CC BY

http://dx.doi.org/10.1590/S1808-185120181703193832

Coluna/*Columna.* 2018;17(3):188-94

Received on 04/04/2018, accepted on 07/25/2018

observaron complicaciones intraoperatorias, como hemorragia severa que requiriera transfusión de sangre, lesión de la duramadre o raíces nerviosas. Las complicaciones postoperatorias se revelaron en 3 (2,5%) pacientes. La tasa de reoperación fue del 4,2%. Conclusiones: El uso del dispositivo de cierre anular Barricaid en 120 pacientes con hernia de disco lumbar y alto riesgo de hernia recurrente mostró buenos resultados clínicos y radiográficos. La tasa de reoperación en nuestro estudio fue del 2.5%; la hernia recurrente del disco en el nivel operado se observó en el 1,7% de pacientes. Es un buen resultado en comparación con los datos informados para pacientes que tienen un alto riesgo de hernia recurrente del disco. ***Nivel de evidencia IV; Serie de casos.***

Descriptores: *Desplazamiento del Disco Intervertebral; Anillo Fibroso; Discectomía; Placas Óseas.*

INTRODUCTION

Microdiscectomy is the most common elective surgery performed in patients with degenerative lumbar spine disorders. Although the good success rate of discectomy is widely recognized, 10–30% of patients still experience low back pain and/or leg pain after the surgery.[1] Patient satisfaction one year after the surgery is approximately 75%, while 20% of patients are reoperated during the first 3 years.[2-5] Disc height loss and recurrent disc herniation are the key reasons for the relapsing pain syndrome and, therefore, reoperation.[6-9]

According to the published data, the overall risk of lumbar disc reherniation is 2–18%.[3,6,10-14] There is convincing evidence that the recurrence rate depends on the size of the annular defect and the volume of nucleus pulposus removed. The risk of recurrence is ~1% in patients with a small or fissure-like annular defect and 18–27% in patients with larger defects.[15] Therefore, for larger defects, several questions regarding the surgical tactics arise. The question of the degree of aggressiveness of the discectomy when treating patients with lumbar disc herniation remains unresolved. Each technique has its own advantages and disadvantages. Aggressive discectomy results in loss of disc height, increased load on the facet joints followed by facet joint hypertrophy, development of segmental instability, and degenerative stenosis.[16] Limited discectomy leaves most of the nucleus pulposus remaining, which creates a potential source of reherniation.

The annular closure device (ACD) following limited microdiscectomy is a modern and promising procedure in spine surgery. The concept of ACD is based on a number of favorable factors: preserving the disc height, preventing recurrent herniation due to the barrier function, reducing lumbodynia due to conservative microdiscectomy, and slowing down the degenerative cascade of both the intervertebral disc and facet joints of the segment.[9]

The device used to close the annular defect, the Barricaid® implant, was designed by Intrinsic Therapeutics (Woburn, MA, USA) to prevent recurrent disc herniation following limited microdiscectomy. The amount of data on the effectiveness of using Barricaid in large patient cohorts accumulated thus far is insufficient. In 2009, an RCT involving over 500 patients was started; however, it is not yet complete, and the results have not been reported to the global research community. Thus, prospective studies to evaluate the effectiveness of using the ACD are relevant.

METHODS

Study design and patient selection

We have planned and conducted a single-center prospective study to assess the effectiveness of ACD. The inclusion criteria were posterolateral herniation at L3-L4, L4-L5, L5-S1 levels, and intervertebral disc height in the posterior regions assessed by lateral radiography of the lumbar spine ≥ 5 mm. The exclusion criteria were: spondylolisthesis, segmental instability, spinal stenosis, lumbar scoliosis, earlier surgical interventions at the operated level, osteoporosis (T-score < –2.0), abnormalities and non-degenerative lesions of lumbar spine, and decompensated concurrent diseases. The final decision on implantation was made intraoperatively once the annular defect had been visualized and its size quantified. The study involved 120 patients with lumbar disc herniation operated on by limited microdiscectomy and annular closure using the Barricaid device. In one patient, surgical management involving implantation of the Barricaid device was performed at two levels (L4-L5, L5-S1). Hence, we analyzed 121 cases in which the Barricaid implant was used.

All patients were operated on at Neurosurgical Department no. 2 of the Ya.L.Tsivyan Research Center of Traumatology and Orthopedics in 2012–2017 (inclusive).

All patients underwent clinical neurologic examination and radiography. Pain intensity and the disability index were evaluated using the Visual Analogue Scale (VAS) and the Oswestry scale. Indications for surgery were disc herniation confirmed by neuroimaging (CT/MRI) and the presence of relevant clinical manifestations resistant to conservative treatment for 6 weeks.

Radiographic Measures

The combination of instrumented examination methods included X-ray of the lumbar spine in two projections with functional tests (flexion, extension), and CT and MRI of the lumbar spine. The radiographic data were used to evaluate lumbar lordosis, sagittal plane segmental motion, and the disc height index.[17] This parameter was measured in the lateral radiograph as a ratio between the heights of the intervertebral disc and the body of the superjacent vertebra. MRI of the lumbar spine allowed us to visualize the substrate, in order to determine the type of herniation, its location, the Pfirrmann disc degeneration grade,[18] facet joint degeneration according to Grogan's classification,[19] and Modic changes in the endplates of the adjacent vertebral bodies. All patients underwent preoperative lumbar spine CT to evaluate the bone tissue, reveal erosive changes in the endplates of the adjacent vertebral bodies, and determine the presence of intervertebral disk vacuum phenomenon. Implant position and the condition of bone tissue around the implant anchor and mesh were analyzed using the CT data during the follow-up.

Surgical technique

Surgery was performed under general anesthesia. The patients were positioned on the operating table in a knee-chest position. After cleansing the skin at the surgical site with antiseptic solution, the skin was incised along spinous processes at the level of surgery to isolate spinous processes and the interarch space at the herniation site. Next, we conducted interlaminectomy, revision of the spinal canal, detection of disc herniation, and transection of the posterior longitudinal ligament. Disc herniation and free fragments of the posterior disc portions were removed. The size of the annular defect was measured using templates. The annular closure device was implanted under control of an electronic image converter, according to the size of the annular defect. Hemostasis was achieved and the wound was closed layerwise. The volume of the removed disc herniation was measured in all cases. The patients were mobilized on the day of surgery.

The study was conducted according to good clinical practice, which ensures that the design, implementation, and communication of data are reliable, that the patients' rights are protected, and that confidentiality of the subject's data is maintained. The study was approved by the local ethics committee of the Ya.L.Tsivyan Research Center of Traumatology and Orthopedics (protocol No. 083/17). All patients provided written informed consent, which included their consent for the use of their data in the analyses, and its presentation.

Data collection

The key patient characteristics (sex, age, body mass index, and smoking status) were collected at the preoperative stage. The clinical data (neurological status, VAS pain intensity score, and the Oswestry disability index preoperative, immediately after surgery, during the follow-up, and during the postoperative period) were accumulated. The following parameters related to the surgery were collected: duration of surgery, blood loss volume, size of annular defect, volume of the removed disc herniation, and complications.

Data collection: time points

The outcomes of surgical treatment were evaluated 3, 6, 12, 24, 36, 48, and 60 months after surgery. The VAS score of pain intensity in the spine and leg, the Oswestry disability index, and the neurological status were assessed at all follow-up points; radiography of the lumbosacral spine was also performed. MRI and MSCT of the lumbar spine were performed 6 and 12 months after surgery and once a year thereafter.

Statistical methods

We used an R Statistical Package (http://www.r-project.org) for the calculations. Descriptive statistics were reported as absolute frequencies or as median values with IQR. Depending on the type of data to be processed, we used the Mann-Whitney U test, Pearson's chi-squared test, or the Exact Fisher Test and non-parametric Kruskal-Wallis analysis of variance by rank and median multiple comparisons.

All the reported p values were based on two-tailed tests for significance, and p values < 0.05 were considered statistically significant. We used the software programs STATISTICA 7.0 (StatSoft, Tulsa, OK, USA) and RStudio version 0.99.484 (Free Software Foundation, Inc., Boston, USA) with R packages version 3.2.2 (The R Foundation for Statistical Computing, Vienna, Austria) for the analyses.

RESULTS

Table 1 shows the general characteristics of the patients. Patients aged 17–63 years were enrolled, with males predominating (53.3%). Lumbar disc herniation mainly presented as radicular pain. Neurological disorders presenting as hypoesthesia and weakness in the innervation zone of a compressed spinal nerve root were observed in 33.3% of patients. Surgery was performed at three lower lumbar levels, mostly at the L5-S1 level (51.7%).

Clinical outcomes

All patients showed postoperative regression of the radicular pain syndrome and were mobilized on the day of surgery. The VAS scores showing pain intensity in leg and back preoperatively, at discharge, and after 3, 6, 12, 24, 36, 48, and 60 months, are shown in Figure 1 a, b.

The disability index was evaluated using the Oswestry questionnaire. A reliable reduction in the Oswestry disability index (improvement in the quality of life) was observed at all follow-up points. (Figure 2)

Radiological results

The herniation type (protrusion, extrusion, or sequestration) was determined from the MR scans, according to the nomenclature proposed by the North American Spine Society in 2001.[20] Protrusion (47.5%) was the most common type, while extrusion and sequestration were observed in 25.8 and 26.7% of cases, respectively.

The disc height index (DHI) was calculated using the formula: DHI = a/A, where a and A is the height of the intervertebral disc and the superjacent vertebra, respectively.[17] Assessment of the dynamics of changes in the disc height index showed no significant reduction in this parameter at the follow-up points (p=0.541). (Figure 3) Analysis of the height index of the disc within one year of surgery showed that this parameter mostly decreased in the first three months (loss 6.59 ± 0.72%). In the second quarter and half-year after the operation, the losses were 3.56 ± 0.56% and 4.01 ± 0.64%, respectively.

Intervertebral disc collapse after most of the nucleus pulposus had

Table 1. General characteristics of the patients.

Evaluation parameters	Value	%
Number of patients, 120; number of operated levels, 121		
Sex		
males (%)	64	53.3
females (%)	56	46.7
Age, years	37.6	-
BMI	26.6	-
Smoking status		
Positive (%)	63	52.5
Negative (%)	57	47.5
Number of bed days	7.8	-
Surgery duration, min	57.1	-
Volume of blood loss, ml	79.7	-
Symptoms of the disease		
Pain	80	66.7
Pain + hypoesthesia and/or leg weakness	40	33.3
Operated level (%)		
L3-L4	6	4.96
L4-L5	52	42.98
L5-S1	63	52.07
Herniation side (%)		
right-sided	52	42.98
left-sided	69	57.02
Herniation type (%)		
protrusion	60	49.59
extrusion	29	23.97
sequestration	32	26.45
Annular defect area, mm^2	47.3	-
Disc volume, cm^3	11.7	-
Volume of the removed disc herniation (% of the total disc volume)	1.5	12.8
Follow-up period, months	18.9	-

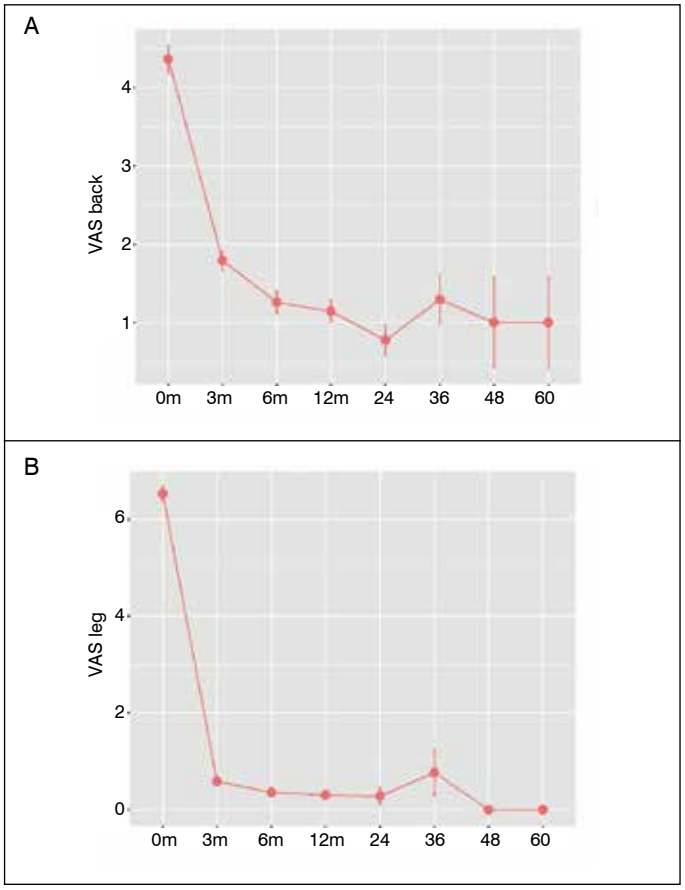

Figure 1. The dynamics of changes in VAS score: A – VAS back (p=0.023); B – VAS leg (p=0.001).

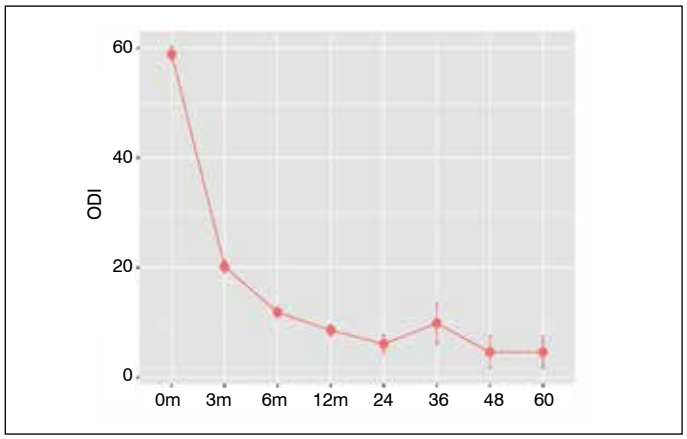

Figure 2. The dynamics of changes in the Oswestry disability index (ODI). p=0.001.

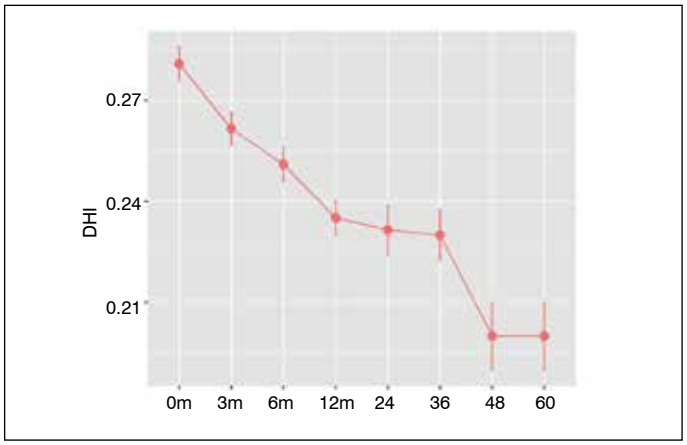

Figure 3. Disc height loss after operation (3-60 months), (DHI-disc height index).

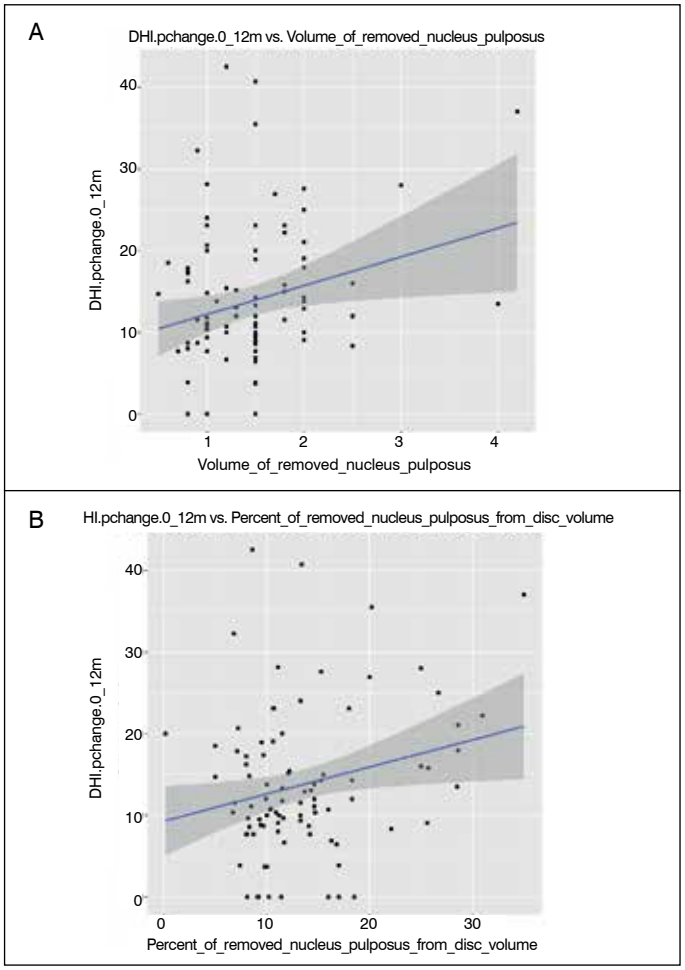

Figure 4. The difference in preoperative DHI and DHI 12 months after the surgery (%) as a function of the volume of the removed nucleus pulposus; left image: Volume of the removed nucleus pulposus (cm3); right image: Percentage of the removed nucleus pulposus with respect to total disc volume.

been removed was one of the reasons for the unfavorable outcome of microdiscectomy. The correlation between the removed nucleus pulposus and changes in DHI was studied by linear regression.

We studied the difference (%) between the DHI 12 months after the surgery and the preoperative DHI and it revealed that disc height loss directly correlated with the volume of removed nucleus pulposus. In both cases, p was <0.05. (Figure 4)

Retrolisthesis at the operated level was revealed in 29 (24.2%) patients. Assessment of the VAS scores for back and leg pain severity and ODI showed no intergroup difference (p>0.05) in disc height loss in patients with and without retrolisthesis at postoperative follow-up points of six-12 months.

Endplate changes

Preoperative lumbar spine MRI showed Modic changes in endplates in 20 (16.7%) patients. Of the 100 patients with no Modic changes prior to surgery, 22 (22%) patients presented these changes postoperatively. Table 2 shows the type and time of emergence of Modic changes.

Preoperative CT images showed erosive changes and resorption foci of endplates of the superjacent and subjacent vertebra in 12 (10%) and five (4.2%) patients, respectively. The area affected by these changes increased postoperatively. Resorption foci of the superjacent vertebra (around the polyethylene terephthalate mesh) were revealed in 20 patients at different follow-up points, while resorption foci of the subjacent vertebra were detected in five patients. Resorption foci around the polyethylene terephthalate mesh emerged in patients in whom the mesh end was contacting the body of an adjacent vertebra as a result of disc height loss.

Assessment of the dynamics of changes in the disc height index in patients with bone resorption around the mesh showed a reduction in this parameter during follow-up (p=0.542) (figure 5).

As a result of the loss of disk height, the mesh with the endplate of adjacent vertebra has come into contact, leading to the appearance of a resorption area.

We found by non-parametric 2-way ANOVA that these changes in MR/CT images have no effect on clinical presentation of the disease. (Table 3)

Table 2. Modic changes.

Period / Modic	Preoperative period	Follow-up period (months)					
		6	12	24	36	48	60
I	13	4*	1	3	-	1	-
II	6	5	3	2	2	-	-
III	1	-	0	1	-	-	-
Total	20	9	4	6	2	1	-

*the number of patients with Modic changes detected for the first time.

Recurrent disc herniation

Ipsilateral and contralateral disc reherniation at the operated level was revealed in one patient each (0.8%). Both patients underwent reoperation. (Table 4) No contralateral disc herniation was revealed in the remaining cases.

Two (1.7%) patients developed disc reherniation without signs of compression of neural structures. Lumbar spine MRI 12 and 18 months after the surgery revealed ipsilateral reherniation at the

operated level. However, the patients did not complain of pain in the lumbar spine and lower extremities during examination. These patients were followed up.

Complications and reoperations

There are risks of complications associated with using the Barricaid annular closure device. Its implantation requires sufficiently large interlaminar and intracanal spaces for impaction, which is ensured by sufficiently high traction of the nerve root and the dural sac and may cause injury to these structures. As with any other implant, there is a risk of implant migration, subsidence, and mechanical damage, and also of an allergic response to it.

No intraoperative complications, such as severe hemorrhage requiring blood transfusion, or injury to the dura mater or nerve roots, were observed in our case series. Postoperative complications were revealed in three (2.5%) patients. One patient had an epidural hematoma requiring revision surgery. One patient exhibited aggravation of neurological symptoms: increased severity of hypoesthesia of the affected area, which completely subsided within three months. One patient developed post-catheterization thrombophlebitis of the subcutaneous vein of the left forearm; conservative treatment was carried out according to the angiosurgeon's recommendations.

Reoperation rate was 4.2%. (Table 5)

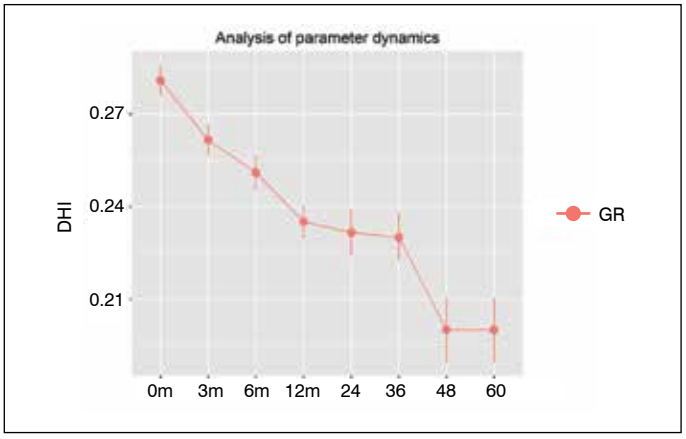

Figure 5. Dynamics of changes in the disc height index in patients with foci of resorption around the Mesh.

Table 3. Modic changes, bone resorption and VAS & ODI scores.

	VAS back	VAS leg	ODI
Patients with Modic changes	2 (1.5:2.65)	1.75 (1.5:2.31)	22.08 (17.58:30)
Patients without Modic changes	2.33 (1.82:3)	1.8 (1.5:3)	25 (21.17:34.42)
p value	0.095	0.287	0.119
Patients with bone resorption	5 (2:6)	7 (6:8)	60 (52:62)
Patients without bone resorption	4 (4:6)	6 (5:7.25)	57 (48.67:68.5)
p value	0.831	0.223	0.728

The Barricaid annular closure device was removed and posterior interbody fusion using transpedicular fixation was performed in 4 cases. Three (2.5%) patients in our series were reoperated because of segmental instability. These patients had preoperative segmental instability that has not been evaluated, although the radiographic data showed no instability. However, the pain syndrome can significantly limit the applicability of this method. In one patient, removal of the implant (ipsilateral disc reherniation at the operated level) was technically challenging, since the implant was tightly fused with the vertebral body. Neurological deficit in this patient worsened continuously: the leg weakness was aggravated. Control examination after 3 months showed regression of neurological deficit to reach the preoperative level. In other patients, implant removal was not associated with any difficulties.

DISCUSSION

The use of the Barricaid annular closure device aims to reduce the rate of recurrent herniation due to its barrier function, to reduce lumbodynia by maintaining the disc height because of limited discectomy, and to slow down the degenerative cascade of both the intervertebral disc and facet joints of the spinal motion segment.

We studied the results of using the annular closure device in patients with lumbar disc herniation with a high risk of recurrent herniation. The risk of reherniation was considered high if a patient had an annular defect and had undergone limited microdiscectomy (sequestrectomy). In their review, Watters et al. demonstrated that the high rate of lumbar disc reherniation depended on the volume of the disc being removed (8.7% upon limited discectomy and 3.3% upon aggressive discectomy), but this is compensated for by a reduction in frequency of recurrent non-herniation back and leg pain (11 and 28% upon limited and aggressive discectomy, respectively).[21] Carragee et al. conducted a prospective study (I-1 level of evidence) in 180 patients with the median follow-up period of 6 years and revealed that the degree of annular defect after discectomy and herniation type is correlated with the reherniation rate.[15] McGirt et al. found that the risk of disc reherniation increases in patients with annular defects wider than 6 mm and a smaller volume of disc removed.[2, 22]

As we have mentioned earlier, there are few publications reporting the outcomes of using the Barricaid annular closure device; the results of randomized trials are not available. The existing studies were performed in small patient samples with the maximum follow-up period of 24 months.

We performed searches in the Scopus, Pubmed, and Google Scholar search engines using the keywords "Barricaid", "ACD", and "annular closure device". Table 5 lists the publications on the outcomes of using this device.

Lequin et al. performed a prospective study of 45 patients (follow-up period, 12 months) who had undergone limited discectomy and annular closure with the Barricaid device at the L4–L5 and L5–S1 levels. They reported a statistically significant decrease in pain intensity and improvement in quality of life. Revision surgery was needed in three cases: to manage ipsilateral disc reherniation in one patient; to the contralateral disc reherniation in another

Table 4. Reoperation rate, reason and treatment tactics.

no.	Reason for reoperation	Number of patients	%	Period of reoperation (months)	Treatment tactics
1	Disc herniation at the operated level on contralateral side	1	0.8	6	Reoperation and removal of disc herniation
2	Segmental instability of the operated disc	3	2.5	2, 6, 18	Reoperation, removal of the Barricaid annular closure device, and rigid fixation of the segment
3	Ipsilateral disc reherniation at the operated level	1	0.8	30	Reoperation, removal of disc herniation, removal of the Barricaid annular closure device, and rigid fixation of the segment
4	Epidural hematoma	1	0.8	Early postoperative period	Reoperation, removal of hematoma, and decompression
	Total	6	5		

Table 5. Review of the literature devoted to the Barricaid annular closure device.

	Authors	Year	Journal	Design	Number of patients	Follow-up (months)	Reherniation, symp (%)	Reherniation, asymp (%)	Reoperation (%)
1	Lequin et al.	2012	Korean J spine	Prospective, multi-center study	45	24	2.4	2.8	2.4
2	Trummer et al.	2013	Clinical Neurology and Neurosurgery	Prospective, multi-center study	63	12	NA	NA	NA
3	Parker et al.	2013	Journal of Neurological Surgery	A Multicenter Prospective Cohort Study	30	24	0	0	0
4	Bouma et al.	2013	Eur Spine J	Prospective	75	24	1.4	5.1	1.3
5	Hahn et al.	2014	Korean J Neurotrauma	Case report	3	12	0	0	0
6	Ledic et al.	2015	Journal of Neurological Surgery	Prospective	75	24	1.5	NA	4.2
7	Barth et al.	2016	Journal of Clinical Neuroscience	Retrospective	45	18	2.2	NA	8.9
8	Parker et al.	2016	Journal of Spinal Disorders & Techniques	A multi-center prospective cohort study	30	24	0	NA	0
9	Krutko et al.	2016	International Journal of Surgery Case Reports	Case report	-	-	-	-	-
10	Lange et al.	2017	Acta Neurochir	Case report	-	-	-	-	-
11	Klassen et al.	2017	Journal of Pain Research	Post hoc analysis of a randomized controlled trial	272	3	NA	NA	1.9
12	Adisa Kuesumovich et al.	2017	Cureus	Retrospective	171	15	4.1	2.9	9.4

patient; and to treat coarse cicatricial epidural lesions in the third patient.[23] We observed no cicatricial changes requiring reoperation in our series. In their study with 2-year follow-up period, Parker et al. compared the outcomes of the conventional microdiscectomy and microdiscectomy using the Barricaid annular closure device. No disc reherniation was revealed in the group of patients who had undergone annular closure, while 6.5% of patients in the discectomy group had disc reherniation requiring revision surgery.[24] Different authors reported that the short-term outcomes of limited discectomy followed by annular closure using the Barricaid device were comparable to those of the conventional discectomy.[7,25] As reported by Lequin et al., the rate of symptomatic and asymptomatic reherniation following the use of the Barricaid annular closure device was 1.4 and 1.5%, respectively.[23] Bouma et al. conducted a prospective study of the effectiveness of the Barricaid annular closure device following limited microdiscectomy in 75 patients. After 12 months, 1.4% of patients developed disc reherniation requiring reoperation and 1.5% of patients had asymptomatic reherniation. After 24 months, asymptomatic reherniation was present in 5.1% of patients.[26] In our study, asymptomatic reherniation was found in two cases (1.7%). Recurrent disc prolapses without clinical symptoms may be present in as many as 13% of discectomy patients two years after surgery.[27]

Trummer et al. demonstrated that annular closure slows down facet joint degeneration.[28] We assessed the changes in degeneration of facet joints and the intervertebral disc and revealed no statistically significant worsening of degeneration during the follow-up period. Hence, the use of annular closure following discectomy allows the shape and function of facet joints and the intervertebral disc to be maintained.

Application of the annular closure device has a positive effect on the spinal motion segment by maintaining the intervertebral disc height. According to the published data, the height of the intervertebral disc may decrease as much as by 25% compared to the preoperative height,[2,6,8,9] which can be observed in clinical manifestations. Lequin et al. reported that intervertebral disc height after surgical removal of disc herniation followed by annular closure decreased by only 7% from the baseline level.[23] We also revealed no statistically significant disc height loss, indicating that the Barricaid annular closure device can reliably protect the intervertebral disc injured during limited discectomy.

The emergence of resorption foci of bone tissue around the implant is one of the negative radiographic outcomes after implanting the Barricaid device. We revealed that these foci mainly occur at the sites where the end of the implant mesh or anchor contacts the endplate of an adjacent vertebra. In their retrospective study, Barth et al.[29] assessed the discal and non-discal changes after closure of annular defect in 45 patients. The control group consisted of 40 patients who had undergone sequestrectomy alone (group S). The inclusion criteria were identical; the follow-up period ranged between 18 and 27 months. Those authors revealed that disc reherniation in the sequestrectomy group was reliably higher (12.5 and 2.2%); patients in the S group more often had an annular defect confirmed by MRI. Postoperative Modic changes were observed in one patient in each group. The rate of vertebral endplate changes presenting as small cysts, erosion, and bone tissue resorption was reliably higher in patients with implanted annular closure devices (52.4 and 10.3%). These changes were mostly detected around the polyethylene terephthalate Mesh. No correlation between the clinical treatment outcomes and the MRI data were revealed in this study.

Lange et al. reported a case of low-grade infectious process around the Barricaid annular closure device five years following the surgery. Lumbar spine MSCT revealed bone tissue resorption around the implant. Bacteriological examination showed *propionibacterium acnes* colonization.[30]

The study by Kursumovich et al.[31] is one of the most recent publications devoted to the Barricaid device. Those authors performed a retrospective analysis of the outcomes of microdiscectomy and annular closure in 171 patients. The mean follow-up period was 15 months. Disc reherniation was revealed in 4.1% of cases; asymptomatic disc reherniation was observed in 2.9% of patients. Fifteen (8.8%) patients had either partial or complete detachment of the polymer mesh from the titanium anchor. Only two of these patients were reoperated. We observed no mesh detachment in our cases. The mesh was turned towards the spinal canal in two patients (1.7%), but it still was attached to the titanium anchor. These changes were detected three and 18 months postoperatively, respectively. The patients presented with no recurrent disc herniation and/or pain syndrome. Penetration of the implant mesh into the adjacent vertebral endplate was observed in nine cases (7.4 %).

Our study has a number of limitations: its design involved neither randomization nor a control group; the follow-up periods ranged from two to 60 months; the interventions were performed by different surgeons; and no independent evaluation of the radiographic and MRI data was carried out. These facts may have potentially biased the study results.

CONCLUSIONS

The use of Barricaid annular closure device in 120 patients with lumbar disc herniation and high risk of recurrent herniation showed good clinical and radiographic outcomes. The disc height was maintained; no reliable decrease in this parameter was observed at follow-up points. The reoperation rate in our study was 2.5%; disc reherniation at the operated level was observed in 1.7% of patients. This is a good outcome compared to data reported for patients with a high risk of disc reherniation. Disc reherniation or bone tissue resorption around the implant requiring revision surgery is possible. Large randomized trials are needed to evaluate whether wide the application of this annular closure device is feasible.

All authors declare no potential conflict of interest related to this article.

CONTRIBUTION OF THE AUTHORS: Each author made significant individual contributions to this manuscript. SAJ (0000-0002-4744-4077)* and KAV (0000-0002-2570-3066)* were the main contributors in the drafting of the manuscript. BES (0000-0002-4430-700X)*, SAJ and KAV performed the surgery, followed up patients, and gathered clinical data. SAJ and LAA (0000-0003-0620-3119)* evaluated the data from the statistical analysis. SAJ, KAV and LAA performed the literature search and review of the manuscript, and contributed to the intellectual concept of the study. *ORCID (Open Researcher and Contributor ID).

REFERENCES:

1. Peul WC, van den Hout WB, Brand R, Thomeer RT, Koes BW. Prolonged conservative care versus early surgery in patients with sciatica caused by lumbar disc herniation: two year results of a randomised controlled trial. BMJ. 2008;336(7657):1355-8.
2. McGirt MJ, Eustacchio S, Varga P, Vilendecic M, Trummer M, Gorensek M et al. A prospective cohort study of close interval computed tomography and magnetic resonance imaging after primary lumbar discectomy: factors associated with recurrent disc herniation and disc height loss. Spine (Phila Pa 1976). 2009;34(19):2044–51.
3. Strumqvist B, Fritzell P, Hagg O, Jonsson B. One – year report from the Swedish National Spine Register. Acta Orthop Suppl. 2005;76(319):1-24.
4. Camino Willhuber G, Kido G, Mereles M, Bassani J, Petracchi M, Elizondo C et al. Factors associated with lumbar disc hernia recurrence after microdiscectomy. Rev Esp Cir Ortop Traumatol. 2017;61(6):397-403.
5. Byvaltsev VA, Kalinin AA, Belykh EG, Sorokovikov VA, Shepelev VV. [Optimization of segmental lumbar spine instability treatment using minimally invasive spinal fusion technique]. Zh Vopr Neirokhir Im N N Burdenko. 2015;79(3):45-54.
6. Barth M, Diepers M, Weiss C, Thomé C. Two-year outcome after lumbar microdiscectomy versus microscopic sequestrectomy: part 2: radiographic evaluation and correlation with clinical outcome. Spine (Phila Pa 1976). 2008;33(3):273–9.
7. Carragee EJ, Spinnickie AO, Alamin TF, Paragioudakis S. A prospective controlled study of limited versus subtotal posterior discectomy: short-term outcomes in patients with herniated lumbar intervertebral discs and large posterior annulus defect. Spine (Phila Pa 1976). 2006;31(6):653–7.
8. Loupasis GA, Stamos K, Katonis PG, Sapkas G, Korres DS, Hartofilakidis G. Seven- to 20-year outcome of lumbar discectomy. Spine (Phila Pa 1976). 1999;24(22):2313–7.
9. Yorimitsu E, Chiba K, Toyama Y, Hirabayashi K. Long-term outcomes of standard discectomy for lumbar disc herniation: a follow-up study of more than 10 years. Spine (Phila Pa 1976). 2001;26(6):652-7.
10. Ambrossi GL, McGirt MJ, Sciubba DM, Witham TF, Wolinsky JP, Gokaslan ZL, et al. Recurrent lumbar disc herniation after single-level lumbar discectomy: incidence and health care cost analysis. Neurosurgery.2009;65(3):574–8.
11. Atlas SJ, Keller RB, Wu YA, Deyo RA, Singer DE. Long-term outcomes of surgical and nonsurgical management of sciatica secondary to a lumbar disc herniation: 10 year results from the maine lumbar spine study. Spine (Phila Pa 1976). 2005;30(8):927-35.
12. Belykh E, Krutko AV, Baykov ES, Giers MB, Preul MC, Byvaltsev VA. Preoperative estimation of disc herniation recurrence after microdiscectomy: predictive value of a multivariate model based on radiographic parameters. Spine J. 2017;17(3):390-400.
13. Malter AD, McNeney B, Loeser JD, Deyo RA. 5-year reoperation rates after different types of lumbar spine surgery. Spine (Phila Pa 1976). 1998;23(7):814-20.
14. Belykh E, Giers MB, Preul MC, Theodore N, Byvaltsev V. Prospective Comparison of Microsurgical, Tubular-Based Endoscopic, and Endoscopically Assisted Diskectomies: Clinical Effectiveness and Complications in Railway Workers. World Neurosurg. 2016;90;273-80.
15. Carragee, E, Han MY, Suen PW, Kim D. Clinical outcomes after lumbar discectomy for sciatica: the effects of fragment type and annular competence. J Bone Joint Surg Am. 2003;85-A(1):102-8.
16. Weinstein JN, Lurie JD, Tosteson TD, Tosteson AN, Blood EA, Abdu WA et al. Surgical versus nonoperative treatment for lumbar disc herniation: four-year results for the Spine Patient Outcomes Research Trial (SPORT). Spine (Phila Pa 1976). 2008; 33(25):2789-800.
17. Kim KT, Park SW, Kim YB. Disc height and segmental motion as risk factors for recurrent lumbar disc herniation. Spine (Phila Pa 1976). 2009;34(24):2674-8.
18. Pfirrmann CW, Metzdorf A, Zanetti M, Hodler J, Boos N. Magnetic resonance classification of lumbar intervertebral disc degeneration. Spine (Phila Pa 1976). 2001;26(17):1873–8.
19. Grogan J, Nowicki BH, Schmidt TA, Haughton VM. Lumbar facet joint tropism does not accelerate degeneration of the facet joints. AJNR Am J Neuroradiol. 1997;18(7):1325-9.
20. Fardon DF, Milette PC. Nomenclature and classification of lumbar disc pathology. Recommendations of the Combined task Forces of the North American Spine Society, American Society of Spine Radiology, and American Society of Neuroradiology. Spine (Phila Pa 1976). 2001;26(5):E93-113.
21. Watters WC 3ed, McGirt MJ. An evidence-based review of the literature on the consequences of conservative versus aggressive discectomy for the treatment of primary disc herniation with radiculopathy. Spine J. 2009;9(3):240–57.
22. McGirt MJ, Ambrossi GL, Datoo G, Sciubba DM, Witham TF, Wolinsky JP et al. Recurrent disc herniation and long-term back pain after primary lumbar discectomy: review of outcomes reported for limited versus aggressive disc removal. Neurosurgery. 2009;64(2):338–44.
23. Lequin MB, Barth M, Thome C, Bouma G. Primary Limited Lumbar Discectomy with an Annulus Closure Device: One-Year Clinical and Radiographic Results from a Prospective, Multi-Center Study. Korean J Spine. 2012;9(4):340-7.
24. Parker SL, Grahovac G, Vukas D, Vilendecic M, Ledic D, McGirt MJ, Carragee EJ. Effect of an Annular Closure Device (Barricaid) on Same Level Recurrent Disc Herniation and Disc Height Loss after Primary Lumbar Discectomy: Two-Year Results of a Multi-Center Prospective Cohort Study. Clin Spine Surg. 2016;29(10):454-60.
25. Arts MP, Brand R, van den Akker ME, Koes BW, Bartels RH, Peul WC et al. Tubular diskectomy vs conventional microdiskectomy for sciatica: a randomized controlled trial. JAMA. 2009;302(2):149–58.
26. Bouma GJ, Barth M, Ledic D, Vilendecic M et al. The high-risk discectomy patient: prevention of reherniation in patients with large anular defects using an anular closure device. Eur Spine J. 2013;22(5):1030-6.
27. Lebow RL, Adogwa O, Parker SL, Sharma A, Cheng J, McGirt MJ. Asymptomatic same-site recurrent disc herniation after lumbar discectomy: results of a prospective longitudinal study with 2-year serial imaging. Spine (Phila Pa 1976). 2011;36(25):2147-51.
28. Trummer M, Eustacchio S, Barth M, Klassen PD, Stein S. Protecting facet joints post-lumbar discectomy: Barricaid annular closure device reduces risk of facet degeneration. Clin Neurol Neurosurg. 2013;115(8):1440-5.
29. Barth M., Fontana J, Thomé C, Bouma GJ, Schmieder K. Occurrence of discal and non-discal changes after sequestrectomy alone versus sequestrectomy and implantation of an anulus closure device. J Clin Neurosci. 2016;34:288–93.
30. Lange N, Meyer B, Shiban E. Symptomatic annulus-repair-device loosening due to a low-grade infection. Acta Neurochir (Wien). 2017;160(1):199-203.
31. Kuršumović A, Rath S. Performance of an Annular Closure Device in a 'Real-World', Heterogeneous, At-Risk, Lumbar Discectomy Population. Cureus. 2017;9(11):e1824.

SURGICAL SITE INFECTIONS IN PATIENTS AFTER POSTERIOR LUMBAR SPINE FUSION

INFECÇÕES NO LOCAL CIRÚRGICO EM PACIENTES APÓS A FUSÃO POSTERIOR DA LOMBAR

INFECCIONES DEL SITIO QUIRÚRGICO EN PACIENTES DESPUÉS DE LA FUSIÓN LUMBAR POSTERIOR

Vadim Anatol'evich Byvaltsev[1], Ivan Andreevich Stepanov[1], Vladislav Eduardovich Borisov[1], Medetbek Djumabekovich Abakirov[2]

1. Irkutsk State Medical University, Irkutsk, Russia.
2. People's Friendship University of Russia, Moscow, Russia

ABSTRACT

Objective: Infectious complications are the most common cause of unsatisfactory results of surgical treatment and prolongation of hospitalization in patients following spinal surgery. The purpose - to assess the microbiological characteristics of SSI in patients after posterior lumbar fusion for degenerative disease, and to determine the relationship between these characteristics and surgical features of SSIs. Methods: A single-center retrospective non-randomized cohort study was performed, 1563 patients aged 37 to 59 years were included in the study. Microbiological characteristics were analyzed, and their interrelations with the surgical features of all cases of SSIs were determined. Results: The incidence of SSIs was 2.67% (41). Monomicrobial SSIs were detected in 46.3% (19) patients, polymicrobial in 36.5% (15) cases, and negative results of inoculation in 17.07% (7) patients. The most frequent pathogens of SSIs in the study group were *S. aureus* and *S. epidermidis* - 37.9% (33) and 24.1% (21), respectively. The period of development of symptoms of SSIs in patients after posterior lumbar fusion averaged 25.9±65.3 days. Methicillin-resistant *S. aureus* and *S. epidermidis* (*MRSA* and *MRSE*) were verified in 24.1% (21) cases. Conclusions: Assessment of microbiological characteristics should be carried out in all diagnosed cases of SSIs in patients after spine surgical interventions, as these are closely linked to the surgical features of the infectious process. Also, the treatment tactics for this group of patients should be determined by a medical team working in conjunction. ***Level of evidence IV; Descriptive study.***

Keywords: Surgical Wound Infection; Spine; Surgical Procedures, Operative; Microbiology.

RESUMO

Objetivos: As complicações infecciosas são a causa mais comum de resultados insatisfatórios no tratamento cirúrgico e de prolongamento da hospitalização em pacientes após cirurgia da coluna vertebral. O objetivo - avaliar as características microbiológicas do SSI em pacientes após a fusão lombar posterior para sua doença degenerativa e determinar a relação entre essas características e as características cirúrgicas de SSIs. Métodos: Um estudo de coorte retrospectivo não aleatorizado de um centro foi realizado, 1563 pacientes com idade entre 37 e 59 anos foram incluídos no estudo. As características microbiológicas são analisadas e sua interação com as características cirúrgicas de todos os casos de SSIs é determinada. Resultados: A incidência de SSIs foi de 2,67% (41). Os SSI monomicrobianos foram detectados em 46,3% (19) pacientes, polimicrobianos - em 36,5% (15) casos e resultados negativos de inoculação – em 17,07% (7) pacientes. Os agentes patogénicos mais frequentes das SSI no grupo de estudo foram S. aureus e S.epidermidis - 37,9% (33) e 24,1% (21), respectivamente. Conclusões: A avaliação das características microbiológicas deve ser realizada em todos os casos diagnosticados de SSI em pacientes após intervenções cirúrgicas da coluna vertebral em conexão inextricável com as características cirúrgicas do processo infeccioso, e as táticas de tratamento deste grupo de pacientes devem ser determinadas estritamente colegialmente. ***Nível de evidência IV; Estudo descritivo.***

Descritores: *Infecção da ferida cirúrgica; Coluna vertebral; Procedimentos Cirúrgicos; Microbiologia.*

RESUMEN

Objetivo: Las complicaciones infecciosas son la causa más común de resultados insatisfactorios del tratamiento quirúrgico y la prolongación de la hospitalización en pacientes después de la cirugía espinal. El objetivo es evaluar las características microbiológicas de la ISQ en pacientes después de una fusión lumbar posterior por su enfermedad degenerativa, y determinar la relación entre estas características y las características quirúrgicas de las ISQ. Métodos: Se realizó un estudio de cohorte retrospectivo no aleatorizado de un centro, 1563 pacientes de 37 a 59 años de edad fueron incluidos en el estudio. Se analizó las características microbiológicas y se determinó su interrelación con las características quirúrgicas de todos los casos de ISQ. Resultados: La incidencia de ISQ fue del 2,67% (41). Se detectaron ISQ monomicrobianas en 46,3% (19) pacientes, polimicrobianas, en 36,5% (15) casos y resultados negativos de inoculación, en 17,07% (7) pacientes. Los patógenos más frecuentes de las ISQ en el grupo de estudio fueron S. aureus y S. epidermidis: 37,9% (33) y 24,1% (21), respectivamente. El período promedió de desarrollo de síntomas de ISQ en pacientes después de la fusión lumbar posterior fue de 25,9 ± 65,3 días. Conclusiones: La evaluación de las características microbiológicas debe llevarse a cabo en todos los casos diagnosticados de ISQ en pacientes después de intervenciones quirúrgicas espinales en conexión inextricable con las características quirúrgicas del proceso infeccioso. Además de eso, las tácticas de tratamiento de este grupo de pacientes deben determinarse estrictamente de forma colegiada. ***Nivel de evidencia IV; Estudio descriptivo.***

Descriptores: *Infección de la herida quirúrgica; Columna vertebral; Procedimientos quirúrgicos; Microbiología.*

Study conducted at the Irkutsk State Medical University, Irkutsk, Russia.
Correspondence: Irkutsk, PO, Russia. Box number 62. 664082. byval75vadim@yandex.ru

http://dx.doi.org/10.1590/S1808-185120181703193839

Received on 04/04/2018, accepted on 07/25/2018

INTRODUCTION

It is known that infectious complications are the most common cause of unsatisfactory results of surgical treatment and prolongation of hospitalization in patients following spinal surgery.[1,2] According to the National Register of Infections, surgical site infections (SSIs) are the third most frequently registered nosocomial infection, accounting for 14-16% of cases of infection among hospitalized patients.[3] Often, SSIs require complex treatment to cure the inflammatory process, up to the time of repeated audit operations. Due to their high incidence rate, SSIs are a significant economic «burden» for practical health care; the costs associated with SSIs in the US and Europe range from $15,800 to $43,900 for each newly identified case of SSI.[4,5] In addition, SSIs are a direct factor affecting one of the most important indicators in the work of a health care institution and practical health care in general, which is the quality of specialized medical care.[6]

Some small randomized clinical and retrospective studies confirm the effectiveness of individual antimicrobial drugs in the prevention of SSIs in patients after spinal surgery.[7-10] Nevertheless, so far, in many clinical recommendations for the prevention of SSIs there is no common opinion in regard to the selection of certain groups of antibacterial agents in this group of patients. When choosing antibacterial drugs, it is necessary to take into account their broad activity in vitro with respect to the most probable pathogens characteristic for this species and the localization of SSIs.[11,12] When searching for literature sources in the Pubmed, Medline and E-library databases, we found only single reports devoted to the study of the microbiological characteristics of SSIs in patients after surgical operations on the spine. These studies include a small number of respondents and do not take into account the relationship between microbiological characteristics and surgical features of SSIs.[13-16]

A modern understanding of the problem of SSIs in conditions of growing resistance of microorganisms to antibacterial drugs includes an assessment of the microbiological characteristics of each SICI case in indissoluble connection with the surgical features of this type of complications. All this allows us to choose a rational tactic for antimicrobial therapy, and to develop effective antibiotic prophylaxis for SSIs, while minimizing adverse drug reactions.

The purpose of this study was to evaluate the characteristics of SSIs in patients following posterior lumbar fusion, and to determine the relationship between these characteristics and the surgical features of SSIs.

METHODS

A single-center retrospective non-randomized cohort study was performed.

The study included all cases of SSIs in patients after posterior lumbar fusion.

The criteria for exclusion from the study were: (1) age over 60 years, (2) osteoporosis, (3) suffered spine trauma, (4) decompensated diabetes mellitus, (5) chronic heart disease, (6) renal failure, and (7) secondary immunodeficiency states.

The study was performed at the Neurosurgical Center of Road Clinical Hospital, St. Irkutsk-Passenger (Irkutsk, Russia).

The study was conducted between March 2012 and November 2017.

Each case of SSIs was confirmed by the medical team working in conjunction, consisting of a neurosurgeon, a general surgeon, and an infectious disease specialist, taking into account clinical and laboratory data, and classified according to the recommendations of the National Nosocomial Infection Surveillance (NNIS).[17]

Surgical features of SSIs in the study group included: (1) the duration of the development of SSI symptoms from the time of surgery, (2) the prevalence of SSI in the patient groups after the first operation and after repeated operations on the lumbosacral spine, (3) as well as the frequency of occurrence of this complication, depending on the level of the operated vertebral-motor segment.

Bacteriological study of the separated postoperative wounds was carried out according to the methodological recommendations of the sanitary-epidemiological regime. The material for the study was carefully collected using a sterile Pasteur pipette with a rubber pear, and placed in a sterile tube.

The sowing was performed on universal dense nutrient media by the Lincei method. To isolate staphylococci, we sowed directly on a Petri dish with yellow-salt agar medium (Chistovich's medium). In addition, as a storage medium, we used broth with 6.5% sodium chloride, a broth with 1% glucose, poured into 0.5 ml tubes, in which 0.2-0.3 ml of flushing liquid was inoculated. The seeded tubes were incubated at 37°C for 20-24 hours, after which they were seeded on Chistovich's medium. To identify the bacteria of the group of *E. coli*, seeding on the enrichment medium was performed, for which a tampon was immersed in 10-20% bile broth or Kessler's medium. A day later, the incubation at 37°C was performed by transferring to Endo medium. The identification of strains was carried out taking into account their morphological and cultural characteristics. Antisensitivity was determined by the disk method. For each identification of microbial association during the bacteriological examination, the microorganisms detected were individually recorded.

The study was approved by the ethics committee of the Irkutsk State Medical University (No. 12 of 08.02.2016). The study was conducted in accordance with the principles of good clinical practice and the Helsinki Declaration.[18] Before the study, patients provided written informed consent.

Statistical processing of data was carried out using Microsoft Excel 2010 software. The data obtained are presented in the form M±SD (M is the mean value, SD is the standard deviation). The relationship between the microbiological and surgical characteristics of SSI was estimated using the χ^2 criterion. A significance threshold of $p > 0.05$ was set.

RESULTS

The study included 1563 patients (755 women and 808 men) aged 37 to 59 years (mean age 45.2 ± 4.6 years) who underwent rear posterior lumbar fusion.

The incidence of SSIs in the study group was 2.67% (41). Monomicrobial SSIs were detected in 46.3% (19) patients, polymicrobial - in 36.5% (15) cases and negative seeding results were verified in 17.07% (7) patients. At 4.08% (2) patients, a second hospitalization was required to perform audit interventions on the wound with complex SSI therapy. Gram-positive bacteria were identified in 65.5% (57) patients with SSIs, gram-negative microorganisms in 29.8% (26) cases and fungal isolates in in 7.3% (4) of the patients. The most frequent pathogens of SSIs in the study group were *S. aureus* and *S. epidermidis*, with 37.9% (33) and 24.1% (21), respectively. Other common etiologic agents of SSIs were: *Enterococcus spp*. - 11.4% (10), *E. coli* - 8.04% (7), *Propionibacterium spp.* - 5.74% (5) and *Peptostreptococcus* - 4.59% (4). Table 1 shows all the identified SIC agents and their incidence.

The average period of development of symptoms of SSIs in patients after posterior lumbar fusion was 25.9±65.3 days. At the same time, when gram-negative pathogens were detected, the period of symptom development of this complication had a shorter duration - 21.5 ± 40.3 days. The longest period of development of symptoms of SSIs was noted in the case of identification of *Propionibacterium spp*., which was 35.8±44.2 days. (Table 2)

Methicillin-resistant *S. aureus* and *S. epidermidis* (MRSA and MRSE) were verified in 24.1% (21) cases. It should be noted that the frequency of occurrence of MSSA was almost twice that of MRSA. On the other hand, the prevalence of MRSE was also almost twice the frequency of MSSE. Vancomycin-resistant *Enterococcus* was isolated in 7.3% (3) patients with SSIs. Cefazolin-resistant gram-negative bacteria accounted for 42.3% (11) of all the SSIs caused by gram-negative bacteria, and 12.6% of the total number of microorganisms sown. In 2.29% (2) cases *E. coli* resistant to cefazolin and producing a wide spectrum of β-lactamases were sown.

Table 1. Types of SSIs pathogens in patients after posterior lumbar fusion and the frequency of their occurrence.

Microorganism	%	N
S. aureus	37.9	33
MRSA	4.59	8
MSSA	9.19	16
S. epidermidis	24.1	21
MRSE	6.89	13
MSSE	3.44	7
*Enterococcus spp.**	11.4	10
E. coli	8.04	7
Peptostreptococcus	4.59	4
*Propionibacterium spp.***	5.74	5
P. aeruginosa	2.29	2
P. mirabilis	2.29	2
A. baumannii	1.14	1
Candida spp.	1.14	1
A. fumigatus	1.14	1

* - vancomycin-resistant E. faecium (3), E. gallinarum (7); ** - P. acnes (4) P. avidum (1).

Table 2. Period of development of symptoms of SSI depending on the type of microorganism.

Microorganism	Days to SSI
All	25,9±65.3
Gram-negative microorganisms	21.5±40.3
S. aureus	19.6±47.1
S. epidermidis	24.1±42.5
Enterococcus spp.	23.8±54.3
E. coli	24.7±38.6
Peptostreptococcus	28.1±39.4
P. acnes	35.8±44.2

In patients who underwent repeated surgical interventions on the lumbar spine, SSIs was significantly more common, in contrast to the group of patients who were first operated for degenerative disease of the lumbar spine (p=0.0023) (Figure 1). The number of diagnosed cases of SSIs caused by gram-negative bacteria increased with statistical significance from the level of the intervertebral disc L1-L2 to L5-S1 (p=0.034) (Figure 2).

DISCUSSION

SSIs represent one of the most challenging complications in surgical practice. The present retrospective cohort study presents the results of the analysis of the microbiological characteristics of SSIs cases in patients after posterior lumbar fusion for its degenerative disease. Given the high prevalence of methicillin-resistant strains of the genus *Staphylococcus spp.* and other microorganisms with multiple drug resistance, a clear understanding of the microbiology

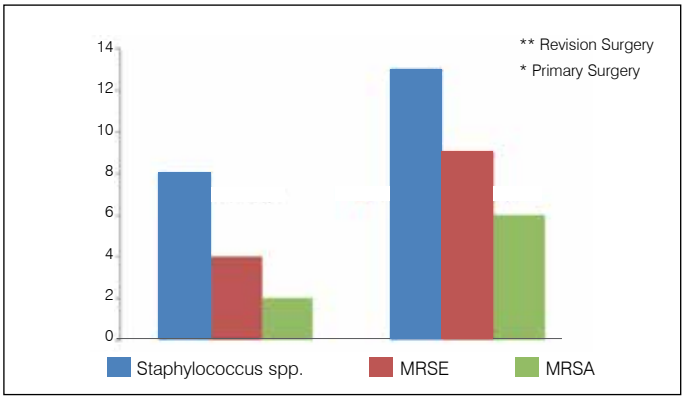

Figure 1. Number of SSIs cases caused by Staphylococcus spp. (including MRSE and MRSA) in the groups of patients with first-time and repeated surgical interventions: there is a significant difference in the overall prevalence of SSIs between these groups and the incidence of SSIs caused by MRSA (* - p = 0.0023, ** - p = 0.0041).

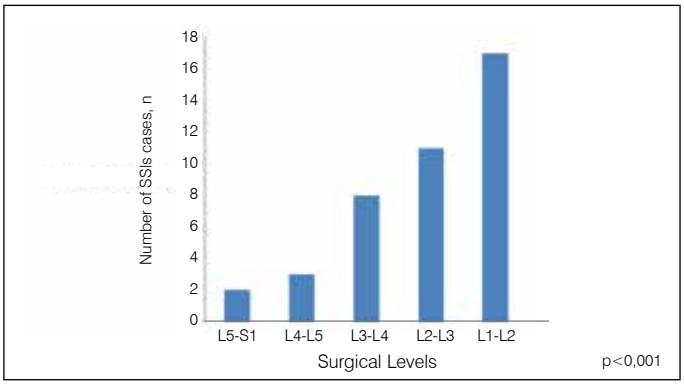

Figure 2. Number of SSIs cases after the performed posterior lumbar fusion depending on the operated level.

of SSIs should be developed to modify the perioperative prevention of this type of adverse events and the selection of effective empirical antimicrobial therapy.

In our study, most of the causative agents of SSIs belonged to the gram-positive microflora, mainly *S. aureus* and *S. epidermidis*. The results obtained are in many ways consistent with data from other clinical and microbiological studies confirming the predominant participation of skin microflora in the role of etiological agents of SSIs.[14,19,20] It has been proven that *S. epidermidis* is the most common causative agent of SSIs in patients who have undergone lumbar or lumbosacral fusion,[21] a fact that was also confirmed by the results of this study. When identifying S. *epidermidis* from a detachable wound, the tactics of treating a patient with SSIs should be determined by the medical team working in conjunction, consisting of a neurosurgeon, general surgeon, infectious disease specialist and clinical pharmacologist. This is because the genus *Staphylococcus spp*. is capable of rapid biofilm formation on the surface of implanted implants, which nullifies the effectiveness of antibiotic therapy.[22,23] The studies that have been conducted on the characteristics of the formation of biofilms (the rate of their formation and resistance to the action of antimicrobial drugs), depending on the material of the implants (stainless steel, titanium, cobalt and chromium alloy) did not show significant differences.[24]

It should be noted that in most cases, SSIs symptoms developed in patients who underwent repeated fusion surgeries on the spine, the causative agents of which were methicillin-resistant *Staphylococcus spp*. In a study by Abdul-Jabbar et al.[25] using the binary logistic regression method, it was proven that decompression-stabilizing surgical interventions performed at the

low lumbar level significantly increased the risk of SSIs. Current clinical recommendations for antibiotic prophylaxis of SSIs do not regulate the widespread use of vancomycin, however, in patients at high risk of developing this complication, the use of vancomycin is considered necessary.[26] In our opinion, patients who undergo repeated operations on the spine have a high risk of SSIs, and local use of vancomycin powder to prevent this type of complications is an effective and justified method.

The prevalence of SSIs caused by gram-negative microflora was 29.5%, which fully agrees with the data from the global literature.[13, 27, 28] It is important to note that the majority of cases of SSIs in which the gram-negative bacteria acted as an etiological agent were significantly more frequent at the lower lumbar level, which probably reflects the microbial landscape of the skin in this anatomical region. This is also confirmed by the fact that in the overwhelming majority of cases of SSIs in patients who had undergone surgical interventions at the lower lumbar level, microbial associations are distinguished. Nevertheless, it cannot be unequivocally asserted that the cause of the development of SSIs in this group of patients is intraoperative inoculation of bacteria or postoperative sowing of the wound by the urinary and/or fecal microflora. Undoubtedly, the data obtained underscore the importance of pre-surgical treatment of the skin (shaving the areas of surgery and douches with antiseptic solutions), and also of swabbing the operating field with alcohol antiseptic solutions, at least three times.[29,30] In addition, in the postoperative period, special attention should be given to the processing and dressing of wounds, especially in the lower lumbar spine. In a systematic review by Xing et al.[31] it was shown that prolonged use of active drainage in patients after lower lumbar and lumbosacral fusion significantly increases the risk of SSIs. Undoubtedly, it is necessary to conduct further large multicenter studies to determine the role of the level of the operated segment and active drainage of the wound in the development of SSIs.

The relatively high percentage of cefazolin-resistant gram-negative microflora casts doubt on the efficacy of this antibacterial drug in preventing the development of SSIs. On the other hand, the overall prevalence of cefazolin-resistant gram-negative bacteria among all isolated pathogens is low, and in most cases of SSIs, the causative agent was the genus *Staphylococcus spp*. Taking into account the accumulated experience of the Neurosurgical Center of the Road Clinical Hospital at st. Irkutsk-Passenger (Irkutsk, Russia) on prevention and treatment of SSIs in patients after various surgical interventions on the spine, we recommend the use of cefazolin in perioperative prevention of this complication, including in patients at high risk. This antibacterial drug has a broad spectrum of action, can be administered intravenously and intramuscularly with a small amount of undesirable drug reactions, and is low in cost.

Limitations of the study

This study has a number of limitations that need to be identified. It is a retrospective study, which could not but affect the quality of data collection for analysis. In addition, the work was carried out in one institution only, which has certain features of the microbial landscape of the department and the operating unit; this does not allow us to extrapolate the data obtained to other medical and preventive institutions. Undoubtedly, it is necessary to conduct further large-scale studies with the inclusion of several institutions and a larger number of patients under study, which will allow us to reliably estimate and analyze the statistical data obtained.

CONCLUSION

SSIs in spinal neurosurgery are important prognostic factors for the clinical outcome of surgical treatment of patients, the quality of care provided, and the cost-effectiveness of hospitalization. Modification of modern methods of antibiotic prophylaxis of SSIs in patients after performed surgical interventions on the spine will significantly reduce the incidence of this complication, improve the results of treatment of this group of patients, and reduce the costs of practical health care for the provision of specialized medical care for patients with degenerative diseases of the spinal column. The present study evaluates the microbiological characteristics of SSIs in indissoluble connection with their surgical features. The data obtained by us can be used in the designation of empirical antimicrobial therapy, taking into account the characteristics, the type of operation performed, and the probable pathogen of SSIs, including when choosing rational antibiotic prophylaxis with fewer unwanted drug reactions. Perioperative administration of cefazolin and intraoperative topical application of vancomycin powder is a justified and effective method of antibiotic prophylaxis of SSIs in patients at high risk. Thus, the evaluation of microbiological characteristics should be carried out in all diagnosed cases of SSIs in patients after surgical interventions on the spine, in close connection with the surgical features of the infectious process. The tactics of treatment of this group of patients is determined by a medical team working in conjunction, consisting of a neurosurgeon, general surgeon, infectious disease specialist, clinical pharmacologist and epidemiologist.

All authors declare no potential conflict of interest related to this article.

CONTRIBUTION OF THE AUTHORS: Each author made significant individual contributions to this manuscript. VAB (0000-0003-4349-7101)* were the main contributors in the drafting of the manuscript. IAS (0000-0001-9039-9147)* performed the surgery, followed up patients and gathered clinical data. VEB (0000-0003-2060-5739)* and MDA (0000-0003-2069-5967)* evaluated the data from the statistical analysis. IAS and VAB performed the literature search and review of the manuscript, and contributed to the intellectual concept of the study. *ORCID (Open Researcher and Contributor ID).

REFERENCES

1. Norman G, Atkinson RA, Smith TA, Rowlands C, Rithalia AD, Crosbie EJ et al. Intracavity lavage and wound irrigation for prevention of surgical site infection. Cochrane Database Syst Rev. 2017;(10):CD012234.
2. Cheng H, Chen BPH, Soleas IM, Ferko NC, Cameron CG, Hinoul P. Prolonged Operative Duration Increases Risk of Surgical Site Infections: A Systematic Review. Surg Infect (Larchmt). 2017;18(6):722-35.
3. Martin ET, Kaye KS, Knott C, Nguyen H, Santarossa M, Evans R et al. Diabetes and Risk of Surgical Site Infection: A Systematic Review and Meta-analysis. Infect Control Hosp Epidemiol. 2016;37(1):88-99.
4. Byvaltsev VA, Stepanov IA, Borisov VE, Kalinin AA, Pleshko IV, Belykh EG et al. Surgical site infections in spinal neurosurgery. Kazan Medical J. 2017;98(5):796-803.
5. Anderson DJ, Podgorny K, Berríos-Torres SI, Bratzler DW, Dellinger EP, Grrene L et al. Strategies to Prevent Surgical Site Infections in Acute Care Hospitals: 2014 Update. Infect Control Hosp Epidemiol. 2014;35(6):605-27.
6. Hyldig N, Birke-Sorensen H, Kruse M, Vinter C, Joergensen JS, Sorensen JA et al. Meta-analysis of negative-pressure wound therapy for closed surgical incisions. Br J Surg. 2016;103(5):477-86.
7. Cizik AM, Lee MJ, Martin BI, Bransford RJ, Bellabarba C, Chapman JR et al. Using the spine surgical invasiveness index to identify risk of surgical site infection: a multivariate analysis. J Bone Joint Surg Am. 2012;94(4):335-42.
8. Patel H, Khoury H, Girgenti D, Welner S, Yu H. Burden of Surgical Site Infections Associated with Select Spine Operations and Involvement of Staphylococcus aureus. Surg Infect (Larchmt). 2017;18(4):461-73.
9. Ando M, Tamaki T, Yoshida M, Sasaki S, Toge Y, Matsumoto T et al. Surgical site infection in spinal surgery: a comparative study between 2-octyl-cyanoacrylate and staples for wound closure. Eur Spine J. 2014;23(4):854-62.
10. Pull ter Gunne AF, van Laarhoven CJHM, Cohen DB. Incidence of surgical site infection following adult spinal deformity surgery: an analysis of patient risk. Eur Spine J. 2010;19(6):982-8.

11. Bratzler DW, Dellinger EP, Olsen KM, Perl TM, Auwaeter PG, Bolon MK et al. Clinical practice guidelines for antimicrobial prophylaxis in surgery. Am J Health Syst Pharm. 2013;70(3):195-283.
12. Mangram AJ, Horan TC, Pearson ML, Silver LC, Jarvis WR. Guideline for prevention of surgical site infection, 1999. Hospital Infection Control Practices Advisory Committee. Infect Control Hosp Epidemiol. 1999;20(4):250-78.
13. Horwitz NH, Curtin JA. Prophylactic antibiotics and wound infections following laminectomy for lumber disc herniation. J Neurosurg. 1975;43(6):727-31.
14. Kowalski TJ, Berbari EF, Huddleston PM, Steckelberg JM, Mandrekar JN, Osmon DR. The management and outcome of spinal implant infections: contemporary retrospective cohort study. Clin Infect Dis. 2007;44(7):913-20.
15. Rihn JA, Lee JY, Ward WT. Infection after the surgical treatment of adolescent idiopathic scoliosis: evaluation of the diagnosis, treatment, and impact on clinical outcomes. Spine (Phila Pa 1976). 2008;33(3):289-94.
16. Thalgott JS, Cotler HB, Sasso RC, LaRocca H, Gardner V. Postoperative infections in spinal implants. Classification and analysis – a multicenter study. Spine (Phila Pa 1976). 1991;16(8):981-4.
17. Schwab F, Gastmeier P, Piening B, Geffers C. The step from a voluntary to a mandatory national nosocomial infection surveillance system: the influence on infection rates and surveillance effect. Antimicrob Resist Infect Control. 2012;1:24.
18. Williams JR. The Declaration of Helsinki and public health. Bull World Health Organ. 2008;86(8):650-2.
19. McClelland S 3rd, Hall WA. Postoperative central nervous system infection: incidence and associated factors in 2111 neurosurgical procedures. Clin Infect Dis. 2007;45(1):55-9.
20. Rao SB, Vasquez G, Harrop J, Maltenfort M, Stein N, Kaliyadan G et al. Risk factors for surgical site infections following spinal fusion procedures: a case-control study. Clin Infect Dis. 2011;53(7):686-92.
21. Viola RW, King HA, Adler SM, Wilson CB. Delayed infection after elective spinal instrumentation and fusion. A retrospective analysis of eight cases. Spine (Phila Pa 1976). 1997;22(20):2444-50.
22. Dakheel KH, Abdul Rahim R, Neela VK, Al-Obaidi JR, Hun TG, Yusoff K. Methicillin-Resistant Staphylococcus aureus Biofilms and Their Influence on Bacterial Adhesion and Cohesion. BioMed Research International. 2016;2016:4708425.
23. Yadav MK, Chae SW, Im GJ, Chung JW, Song JJ. Eugenol: A Phyto-Compound Effective against Methicillin-Resistant and Methicillin-Sensitive Staphylococcus aureus Clinical Strain Biofilms. PLoS ONE. 2015;10(3):e0119564.
24. Adachi K, Tsurumoto T, Yonekura A, Nishimura S, Kajiyama S, Hirakata Y et al. New quantitative image analysis of staphylococcal biofilms on the surfaces of nontranslucent metallic biomaterials. J Orthop Sci. 2007;12(2):178-84.
25. Abdul-Jabbar A, Takemoto S, Weber MH, Hu SS, Mummaneni PV, Deviren V et al. Surgical site infection in spinal surgery: description of surgical and patient-based risk factors for postoperative infection using administrative claims data. Spine (Phila Pa 1976). 2012;37(15):1340-5.
26. Anderson DJ, Podgorny K, Berríos-Torres S, Bratzler D, Dellinger EP, Grrene L et al. Strategies to Prevent Surgical Site Infections in Acute Care Hospitals:2014 Update. Infect Control Hosp Epidemiol. 2014;35(6):605-27.
27. Rihn JA, Lee JY, Ward WT. Infection after the surgical treatment of adolescent idiopathic scoliosis: evaluation of the diagnosis, treatment, and impact on clinical outcomes. Spine (Phila Pa 1976). 2008;33(3):289-94.
28. Abdul-Jabbar A, Berven SH, Hu SS, Chou D, Mummaneni PV, Takemoto S et al. Surgical site infections in spine surgery: identification of microbiologic and surgical characteristics in 239 cases. Spine (Phila Pa 1976). 2013;38(22):E1425-31.
29. Lee I, Agarwal RK, Lee BY, Fishman NO, Umscheid CA. Systematic review and cost analysis comparing use of chlorhexidine with use of iodine for preoperative skin antisepsis to prevent surgical site infection. Infec Control Hosp Epidemiolo. 2010;31(12):1219-29.
30. Maiwald M, Chan ES. The forgotten role of alcohol: a systematic review and meta-analysis of the clinical efficacy and perceived role of chlorhexidine in skin antisepsis. PLoS One. 2012;7(9):e44277.
31. Xing D, Ma JX, Ma XL, Song DH, Wang J, Chen Y et al. A methodological, systematic review of evidence-based independent risk factors for surgical site infections after spinal surgery. Eur Spine J. 2013;22(3):605-15.

ADVANTAGES AND WEAKNESSES OF PERCUTANEOUS ENDOSCOPIC LUMBAR DISCECTOMY: ALGORITHM SELECTION

VANTAGENS E FRAQUEZAS DA DISCECTOMIA LOMBAR ENDOSCÓPICA PERCUTÂNEA: SELEÇÕES DE ALGORITMO

VENTAJAS Y DEBILIDADES DE LA DISCECTOMÍA LUMBAR ENDOSCÓPICA PERCUTÁNEA: SELECCIÓN DE ALGORITMO

Artem Gushcha[1], Andrey Vershinin[1], Sergey Arestov[1], Alexey Kashcheev[1], Vladimir Tjurnikov[1], Maksim Dreval[1], Ekateryna Poltoraco[1], David Petrosyan[1].

1. Neurology Research Center of the Russian Academy of Sciences, Department of Neurosurgery, Volokolamskoe Avenue, Moscow, Russia.

ABSTRACT

Objective: Degenerative diseases of the spine are the most common disorder seen in the practice of the neurosurgeon. According to many surgeons, microdiscectomy is the "gold standard" of surgical treatment. Analyzing the current literature, it is seen that the use of endoscopic techniques in spinal surgery is increasing. However, due to the lack of detailed information on the advantages and disadvantages of these methods, there is a need for continuing research in this area. Work to clarify the features of these methods, their specificity and algorithmization will increase the effectiveness of surgical treatment. Methods: This study included patients with herniated lumbar intervertebral discs, the presence of pain in the leg, and failed of conservative therapy. In the period 2014 to 2017, 172 endoscopic lumbar discectomies were performed, using microendoscopic discectomy and percutaneous endoscopic lumbar discectomy. The effectiveness of each technique was evaluated through comparative analysis. Results: In both groups, the methods used obtained high efficacy rates. Comparative analysis showed the advantages of the percutaneous technique in terms of shortening the return to normal activity time, hospitalization time, and disability, and reducing back pain in the early postoperative period. On the other hand, the microendoscopic discectomy enabled greater radicality to be achieved in cases with herniated disc ossification and complex anatomy of the vertebral segment. Conclusions: Analysis of the data obtained led to the formulation of an algorithm for selecting the optimum endoscopic method for achieving positive results of surgical treatment. ***Level of Evidence II; Therapeutic studies, investigating the results of treatment.***

Keywords: Intervertebral disc displacement; Diskectomy; Neuroendoscopy.

RESUMO

Objetivo: As doenças degenerativas da coluna vertebral estão em primeiro lugar, de acordo com a frequência de ocorrência na prática de um neurocirurgião. De acordo com muitos cirurgiões, a microdiscectomia é o "padrão-ouro" do tratamento cirúrgico. Ao analisar as publicações atuais, há uma tendência em aumentar o uso de técnicas endoscópicas na cirurgia da coluna vertebral. A falta de informações detalhadas sobre as vantagens e desvantagens desses métodos leva à necessidade de continuar a pesquisa nessa direção. Realizar o trabalho detalhando as características desses métodos, sua especificidade e algoritmo aumentará a eficácia do tratamento cirúrgico. Métodos: O estudo incluiu pacientes com discos intervertebrais lombares com hérnia, presença de dor na perna e a não eficácia da terapia conservadora. No período de 2014 a 2017, 172 discectomias lombares endoscópicas foram realizadas. O estudo utilizou discectomia microendoscópica e discectomia lombar endoscópica percutânea. Sua eficácia e análise comparativa foram avaliadas. Resultados: Em ambos os grupos, foram obtidas altas taxas de eficácia dos métodos utilizados. A análise comparativa mostrou as vantagens dos métodos percutâneos sob a forma de encurtamento dos períodos de ativação, hospitalização, incapacidade e redução da dor nas costas no pós-operatório precoce. A discectomia microendoscópica permite alcançar maior radicalidade em casos de ossificação do disco herniado e anatomia complexa do segmento vertebral. Conclusões: A análise dos dados obtidos possibilitou a formulação de um algoritmo para seleção do método endoscópico, que permite alcançar resultados positivos no tratamento cirúrgico. ***Nível de Evidência II; Estudos terapêuticos, investigando os resultados do tratamento.***

Descritores: Deslocamento do disco intervertebral; Discotomia; Neuroendoscopia.

RESUMEN

Objetivo: Las enfermedades degenerativas de la columna vertebral son el trastorno más común visto en la práctica de un neurocirujano. Según muchos cirujanos, la microdiscectomía es el "estándar de oro" del tratamiento quirúrgico. Al analizar publicaciones actuales, se puede notar que el uso de técnicas endoscópicas en la cirugía espinal está aumentando. Sin embargo, la falta de información detallada sobre las ventajas y desventajas de estos métodos lleva a la necesidad de continuar investigando en esta dirección. Llevar a cabo un trabajo para detallar las características de estos métodos, su especificidad y algoritmización aumentará la efectividad del tratamiento quirúrgico. Métodos: Este estudio incluyó a pacientes con discos intervertebrales lumbares herniados, la presencia de dolor en la pierna y falla de la terapia conservadora. En el período de 2014 a 2017, se realizaron 172 discectomías lumbares endoscópicas, utilizando discectomía microendoscópica y discectomía lumbar endoscópica percutánea. La efectividad de cada técnica fue evaluada a través de análisis comparativo.

Study conducted at the Neurosurgical Department of the Neurology Research Center, Moscow, Russia.
Correspondence: Arestov Sergey. 125367, Russia, Moscow, Volokolamskoe Avenue 80. sarestov@gmail.com

CC BY

http://dx.doi.org/10.1590/S1808-185120181703191839

Received on 02/20/2018, accepted on 07/25/2018

Resultados: En ambos grupos, se obtuvieron altas tasas de eficacia de los métodos utilizados. El análisis comparativo mostró las ventajas del método percutáneo cuanto al acortamiento de los períodos para retorno a las actividades, tiempo de hospitalización y discapacidad y reducción del dolor de espalda en el período postoperatorio temprano. Por otro lado, la discectomía microendoscópica permite lograr una mayor radicalidad en casos con osificación de disco herniado y anatomía compleja del segmento vertebral. Conclusiones: El análisis de los datos obtenidos permitió formular un algoritmo para seleccionar el mejor método endoscópico para obtener resultados positivos del tratamiento quirúrgico. ***Nivel de Evidencia II; Estudios terapéuticos que investigan los resultados del tratamiento.***

Descriptores: Desplazamiento del disco intervertebral; Discectomía; Neuroendoscopía.

INTRODUCTION

One of the most common reasons for going to the doctor is back pain. 80-100% of the world's population have suffered this kind of pain at some time in their lives. In any given year, around 20% of the population and 50% of the working-age population will suffer from back pain.[1-3] Back pain, particularly of vertebrogenic cause, significantly limits patients' activity, affecting quality of life and in some cases, causing psychological and emotional changes.[4] The increasing lifespan of the able-bodied population, a lack of regular exercise, and poor nutrition have led to excessive body weight, dysfunction of the deep muscle corset system, and age--related degenerative-dystrophic changes in the spine. As a result, the number of cases of herniated intervertebral discs has increased. Degenerative and dystrophic diseases of the spine are the most frequent occurrence in the practice of the neurosurgeon. In the presence of a herniated intervertebral disc, failure of conservative therapy and/or an increase in neurological deficit, surgical treatment is indicated. Most operations associated with intervertebral disc herniation performed at the lumbar level are performed using a microscope and can be combined under the term "microdiscectomy". According to many surgeons, this is the "gold standard" of surgical treatment. However, the desire to reduce the amount of intervention, blood loss, and risks of possible delayed complications have led to the active introduction of endoscopic technologies aimed primarily at improving the patient's quality of life and reducing invasiveness compared with traditional open operations.

Analyzing the current literature, it is seen that the use of endoscopic techniques in spinal surgery is increasing. Percutaneous endoscopic methods of treating herniated intervertebral disc enables good results to be achieved in patients with pain in the leg. Due to a lack of detailed information on the advantages and disadvantages of these methods, there is a need for continuing research in this area. Work to clarify the features of these methods, their specificity and algorithmization will increase the effectiveness of surgical treatment. Thus, the purpose of this study is to determine the advantages and disadvantages of percutaneous endoscopic lumbar discectomy, and formulate an algorithm for choosing the best surgical technique.

METHODS

General data on the study group

The study included patients with herniated lumbar intervertebral discs, the presence of pain in the leg, and failure of conservative therapy. In the period 2014 to 2017, 172 endoscopic lumbar discectomies were performed, which were divided into two groups:
1. The main group consisted of 86 patients who underwent percutaneous endoscopic lumbar discectomies (PELD) (of which 38 (44%) were men). The "Inside out" (Spine TIP, Karl Storz, Germany) and "Outside in" (TESSYS, Joymax, Germany) methods were used.
2. A control group of 86 patients (of which 35 (41%) were men) who underwent microendoscopic discectomy (MED) using tubular retractors and video guidance (Easy Go, Karl Storz, Germany).

Exclusion criteria were: patients under 18 or over 80 years of age, patients with no pain in the leg, patients with scoliotic deformities, spondylolisthesis, or instability at the level of the proposed surgical intervention, and patients with absolute contraindications to routine surgical treatment.

The study was approved by the local ethics review board of the FGBNU NSC (protocol No. 10/13 of 16/10/13). Informed consent was signed by all patients. Intergroup comparison in the pre--operative period showed the statistical comparability of the two groups (Table 1).

Description of surgical methods

PELD a surgical treatment method for herniated intervertebral discs, full endoscopic surgery, performing a skin incision of up to 1 cm and puncture access through the surrounding tissues. A special feature of this technique is that it causes minimal trauma, due to the delicacy of the operation and the surgical instruments used. Three access variants (intralaminar, posterolateral and transforaminal) were used, and two variants in the method of performing the access - posterolateral or transforaminal ("Inside out" and "Outside in"). In the intralaminar access, the surgery is performed through the interstitial space, passing through the vertebral canal and displacing the root (Figure 1).

In the percutaneous posterolateral and transforaminal access, a working cannula is introduced into the foramen, with decompression and visualization of the root. The "Inside out" option involves the insertion of a cannula into the intervertebral disc, removal of the hernia and visualization of the achieved decompression of the nerve root, which is in the direction of the foramen exit (Figure 2).

The "Outside in" option involves primary decompression with the formation of a resection of the articular process in the medial

Table 1. The general table of statistical reliability of comparability of the two groups (Mann-Whitney test).

N	Criterion	PELD (Me[LQ;UQ])	MED (Me[LQ;UQ])	p–value
1	Floor	0.54 (Fisher's test)		
2	Age, years	41.5 [32;48]	44.5 [40;55]	0.062883
3	Anamnesis of back pain, months	36 [26;36]	24 [24;36]	0.944505
4	Anamnesis of leg pain, months	2 [1;4]	4 [1;5]	0.343464
5	Time of observation, months	19.5 [16;25]	18.5 [13;23]	0.194165
6	VAS of back pain before surgery, points	5 [4;5]	5 [4;5]	0.932568
7	VAS of leg pain before surgery, points	6 [6;7]	6 [6;7]	0.515710
8	Sensitivity disorders before surgery, scores	4 [3;5]	4 [3;5]	0.896248
9	Movement disorders before surgery, scores	5 [5;5]	5 [5;5]	0.675132
10	ODI before surgery, scores	66 [58;78]	68 [62;78]	0.834356

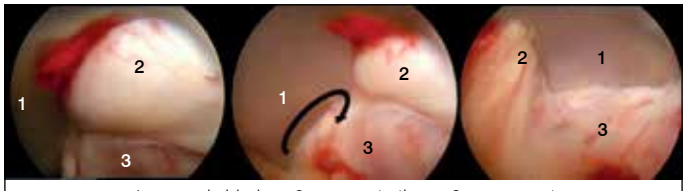

1 - cannula blade 3 - sequestration 2 - nerve root

Figure 1. Stages of intralaminar access, from left to right: visualization, rotation and displacement of the root, safe position of the scapula for the removal of the hernia.

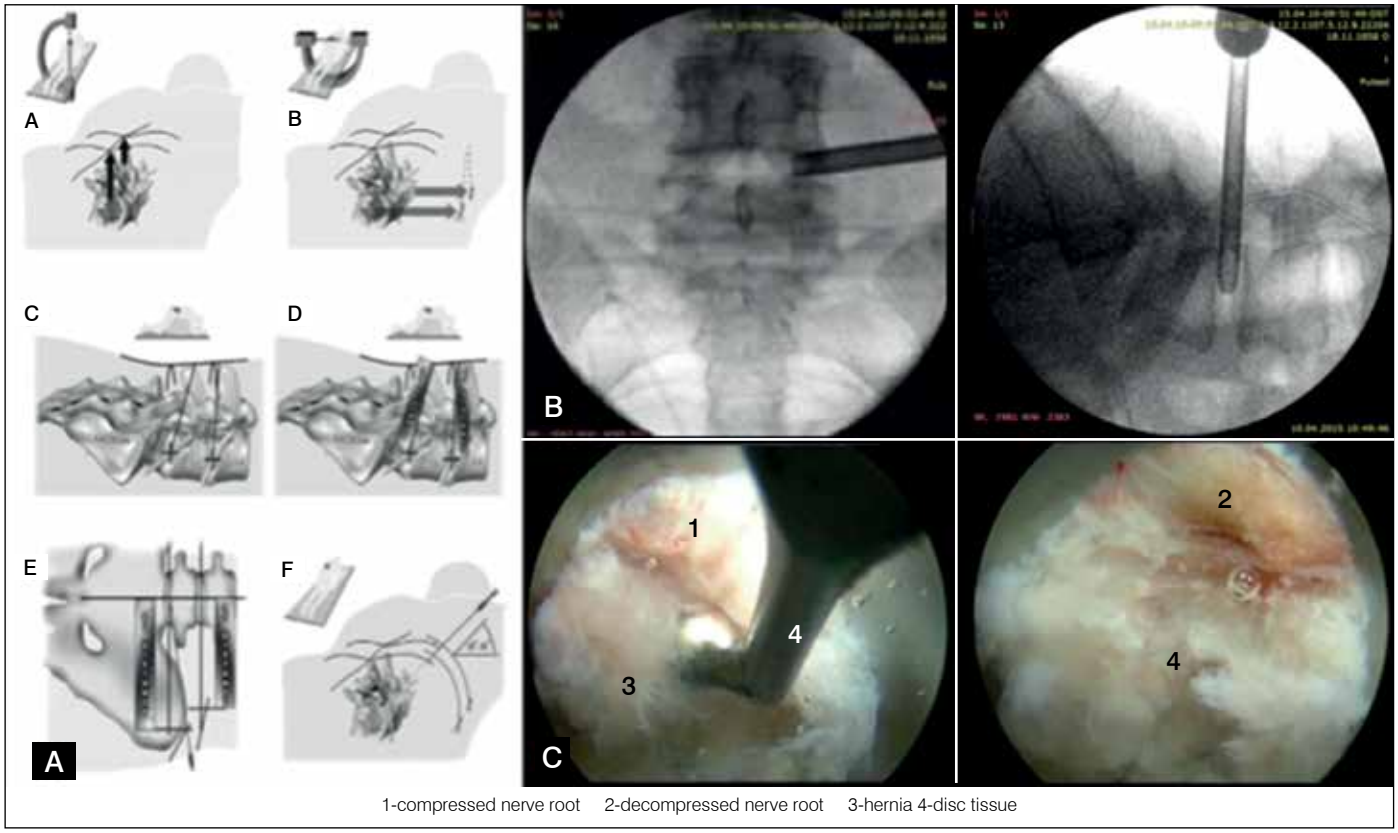

Figure 2. PELD "Inside out" method. A - A. Young access system;[5] B- X-ray correct position of cannula C-stages of decompression.

direction to the area of compression of the nerve root and without entry into the intervertebral disc (Figure 3).

Microendoscopic discectomy (MED) is a method based on microsurgical removal techniques, using tubular retractors and endoscopic imaging. This method uses standard microsurgical instruments, but manipulation is carried out through a working port with a diameter of 14-18 mm created in the paravertebral muscles. For the microendoscopic discectomy, interlaminar and posterolateral approaches were used (Figure 4).

Criteria and methods of evaluation

The patients of both groups were examined four times (before surgery, on day 1, and 6 and 12 months after the operation). To determine the effectiveness of the methods and compare them, the mean indices of activation, hospitalization, temporary incapacity for work and the frequency of complications in the two groups were calculated and compared.

All patients signed an informed consent form and read the information sheet. This was followed by collection of complaints and anamnesis, detailed clinical and neurological examination, MRI (on a Siemens Magnetom Avanto 1.5 T. (Germany) in T1 and T2 modes, STIR) and CT scan of the lumbar department (on a "SOMATOM Definition AS 40" "Siemens" apparatus (Germany) in bone and soft tissue modes), to determine the degree of ossification of the hernia and the presence of marginal osteophytes, functional spondylography (in the lateral projection, to detect instability) on the Visual Analog Scale, Oswestry Disability Index, and Macnab Scale.

Statistical processing of the data was carried out using the software "STATISTICA 8.0" (StatSoft, USA). For the quantitative parameters, the frequency and proportion (as a %) of the total number of patients in each group were calculated. To compare the frequencies of a binary feature in two independent groups, an analysis of the 2x2 tables was performed, performing Fisher's exact test for small samples. For the quantitative parameters, the Median, 25th and 75th percentile, mean and the standard deviation from the mean were calculated. For the non-normal distribution of characteristics, the data were presented as median and interquartile interval Medians [LQ; UQ]. The reliability evaluation was carried out using a nonparametric Mann-Whitney test to compare two unrelated groups. For the normal distribution of characteristics, criteria of parametric comparison were used. $p < 0.05$ was considered indicative of statistical significant difference.

RESULTS

In the main group, the activation time was 10 [9;12] hours, and in the control group, it was 14 [13;16] hours. Thus, the patients of the main group became active earlier, which indicates less surgical trauma for the PELD (Mann-Whitney U Test, $p < 0.001$) (Figure 5).

In the study of hospitalization times, there was a significant decrease in the number of patients in the PELD group, with median values of 2 [2;3] days compared to the MED group, with median values of 4 [3;4] hours (Mann-Whitney U Test, $p < 0.001$) (Figure 6).

Estimating the time of temporary incapacity for work from the moment of patient discharge from the hospital, a significant decrease in the PELD group was revealed (Mann-Whitney U Test, $p < 0.001$). The median value for time of incapacity for work in the PELD group was 2 [2;3] weeks, and in the MED group, it was 3 [3;4] weeks. Thus, it was deduced that the patients of the PELD group had shorter recovery times and earlier return to work.

In the first day after the operation, the level of back pain in the PELD group was -1 [1;2] points, which was significantly less than in the MED group, with -3 [2;3] points. Leg pain in the PELD group was -1 [0;1], and in the MED group, 0 [0;0] by the VAS (Mann-Whitney U Test, $p < 0.001$). Six months later, the level of back pain in the patients of the PELD group was -0 [0;1], and in the MED group, -1 [1;2] (Mann-Whitney U Test, $p < 0.001$), and leg pain, both in the PELD group, and in the MED level of the pain syndrome according to the VAS was 0 [0;0] Thus, a significant advantage of PELD was revealed in the early and late postoperative periods (Figure 7).

Assessing the quality of life according to the Oswestry Disability Index, a significant improvement in the quality of life was observed in the patients of both groups. In the intergroup comparison, the indices did

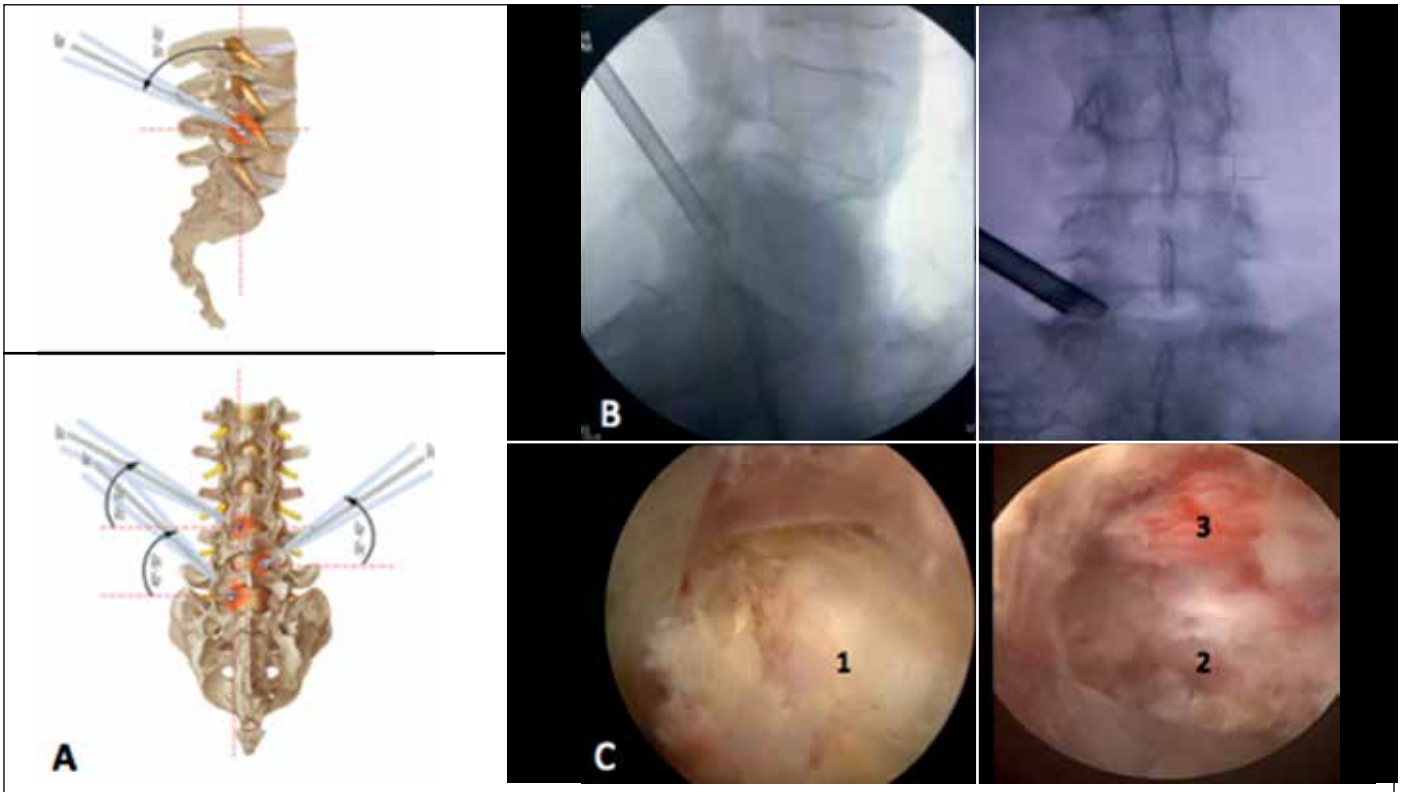

1 - hernia 2 - disc tissue 3 - decompressed nerve root

Figure 3. PELD "Outside in" method. A - T. Hoogland access system;[6] B- X-ray correct position of cannula C-stages of decompression.

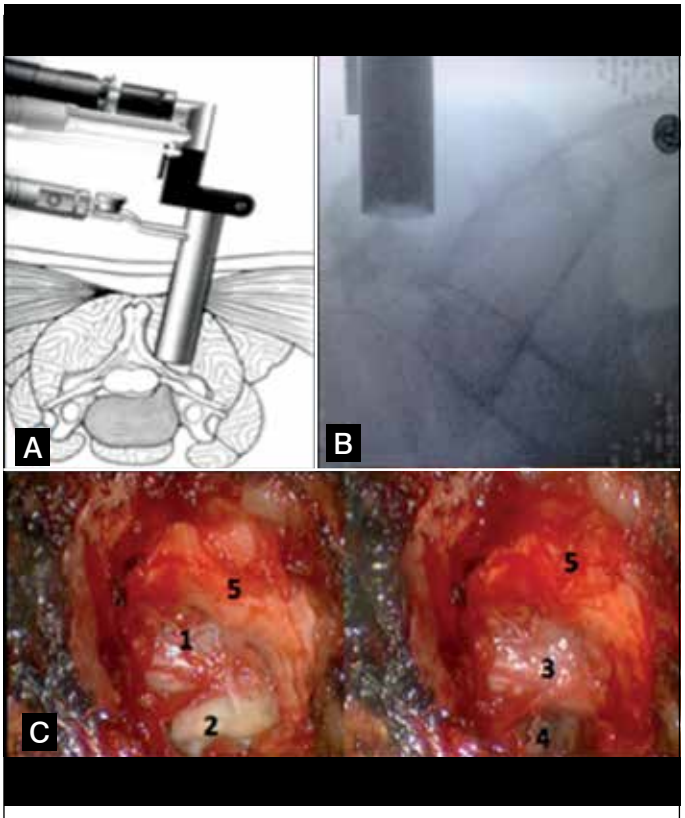

1 - compressed nerve root, 2 - hernia 3 - decompressed nerve root
4 - disc tissue; 5 - yellow ligament

Figure 4. Microendoscopic discectomy A - Access system;[6] B- X-ray correct position tubular retractor; C-stages of decompression.

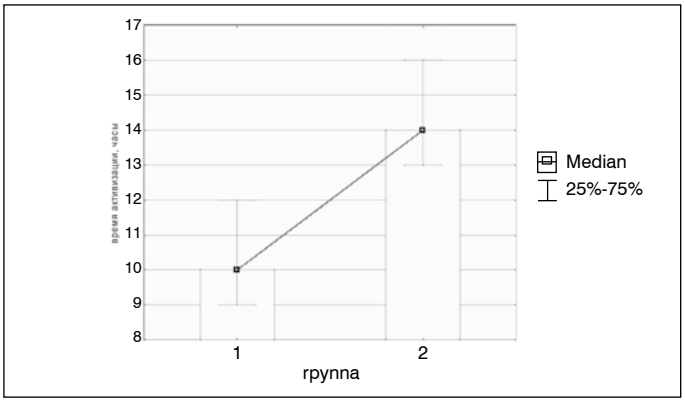

Figure 5. Activation time in two groups.

not differ significantly after 6 months (Mann-Whitney U Test, p = 0.299), or after 12 months (Mann-Whitney U Test, p = 0.133) (Figure 8).

Assessing the surgical treatment performed, according to Macnab's subjective evaluation scale, there was a persistent prevalence of excellent and good results throughout the entire 12-month postoperative follow-up. The statistical processing of the data showed no significant differences (Mann-Whitney U Test, p = 0.324 on day 1, p = 0.766 after 6 months and p = 0.57 after 12 months) (Table 2).

During the course of the study, an analysis of surgical complications was carried out, and the means used to minimizing them were determined. In the two groups (n = 172), there were 13 clinical cases in which complications of surgical intervention were recorded, i.e. 7.6%. Intergroup analysis showed that the incidence of surgical complications in the PELD group was n = 8, 9.3%, and in the MED group n = 5, 5.8%. Accordingly, the incidence of complications in the PELD group was somewhat higher (Table 3).

Based on the results of this study, an algorithm was developed to select the best endoscopic method for surgical treatment of herniated intervertebral discs of the lumbosacral spine (Figure 9).

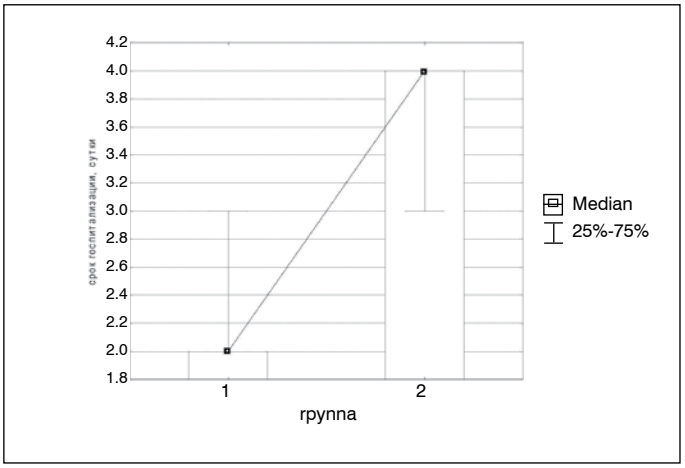

Figure 6. Time of hospitalization in two groups.

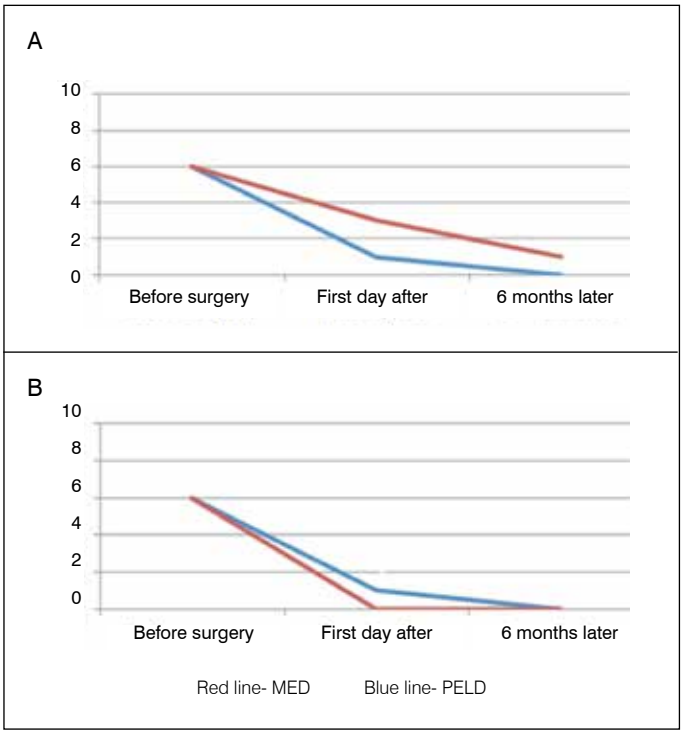

Figure 7. A- dynamics of back pain in VAS; B- dynamics of leg pain in VAS.

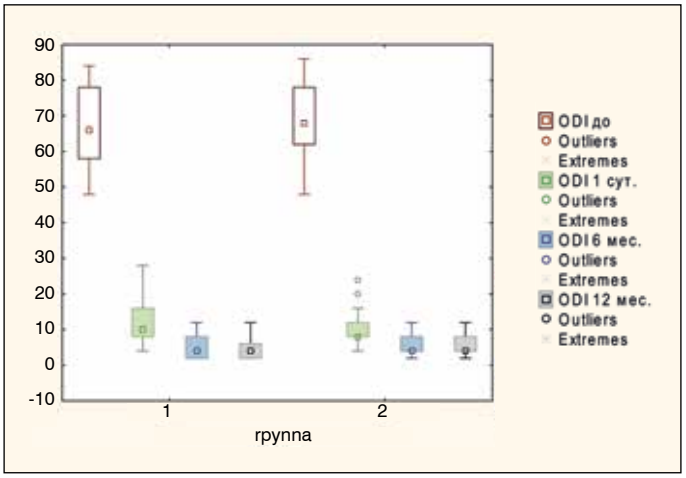

Figure 8. Dynamics of the quality of life by Oswestry Disability Index.

Table 2. Results of surgical treatment on the Macnab scale.

Group	Result/points	After surgery					
		1 day		6 months		12 months	
		N	%	N	%	N	%
PELD	Excellent/4	63	73.5 %	68	79.4 %	73	85.3 %
	Good/3	20	23.5 %	18	20.6 %	13	14.7 %
	Satisfactorily/2	3	3 %	0	0 %	0	0 %
MED	Excellent/4	53	61.8 %	71	82.3 %	68	79.4 %
	Good/3	30	35.2 %	15	17.7 %	18	20.6 %
	Satisfactorily/2	3	3 %	0	0 %	0	0 %

Table 3. Surgical complications.

Group	Variants of complications, (n)			
	Relapse	Bleeding	Postoperative neuritis	Increased neurological deficit
PELD	2	0	4	2
MED	2	2	1	0

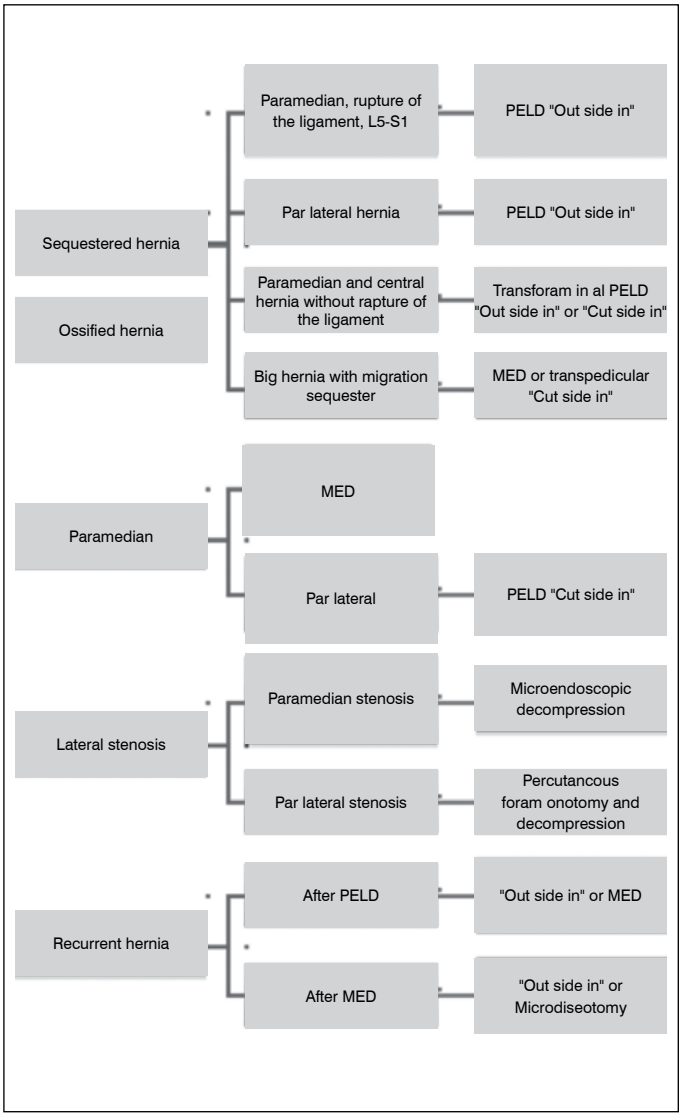

Figure 9. The algorithm for selecting the best endoscopic method for surgical treatment.

DISCUSSION

The statistical analysis of the results of surgical treatment of patients with herniated intervertebral discs of the lumbosacral spine resulted in the indication of the percutaneous endoscopic method. The advantages of this method are described in detail, and include greater radicality with minimal trauma. The algorithm developed for selecting the optimal endoscopic method enables greater efficiency of the surgery and shorter recovery times for patients. Thus, the proposed goal of this work was achieved and the research tasks were solved.

CONCLUSIONS

1. The advantage of percutaneous endoscopic lumbar discectomy is a significant reduction in return to normal activity times, hospitalization for temporary disability, and level of back pain in the early postoperative period. These aspects lead to shorter rehabilitation times for patients.
2. Disadvantages of percutaneous endoscopic lumbar discectomy are a lack of sufficient radicality due to ossification of the hernia and/or complicated anatomy of the intervertebral foramen in clinical cases.
3. The developed algorithm divides herniated intervertebral discs by anatomical localization, size, and the presence of osteophytes, and determines the optimal tactics of surgical treatment by endoscopic methods.

All authors declare no potential conflict of interest related to this article.

CONTRIBUTION OF THE AUTHORS: Each author contributed individually and significantly to the development of the manuscript. AG (0000-0003-3451-5750)*, AV (0000-0002-8006-1334)* and SA (0000-0003-4809-4117)* were the main contributors in the drafting of the manuscript. AK (0000-0001-7681-3073)* and MD (0000-0002-7839-309X)* performed the surgery, followed up the patients and gathered clinical data. EP (0000-0001-9208-2987)* and DP (0000-0001-9588-7721)* evaluated the data from the statistical analysis. VT (0000-0003-4881-4241)* performed the literature search and review of the manuscript, and contributed to the intellectual concept of the study. *ORCID (Open Researcher and Contributor ID).

REFERENCES

1. Braddom RL. Perils and pointers in the evaluation and management of back pain. Semin Neurol. 1998;18(2):197-210.
2. Hall H. Back Pain. In: Noseworthy JH, editor-in-chief. Neurological Therapeutics Principles and Practice. 2nd ed. Vol. I. Chapter 21. Oxon: Informa Healthcare; 2006. p. 240–56.
3. Jayson MIV. General aspects of back pain: an overview. In: Jayson MTV, Swezey RL, Knoplich J, et al., editors. Back pain, Painful Syndromes and Muscle Spasms: Current Concepts and Recent Advances. London: Partheon Publishing Group; 1990. p. 11-5.
4. Gerwin R, Dommerholt J, Shah J. An expansion of Simons´ integrated hypothesis of trigger point formation. Curr Pain Headache Rep. 2004;8(6):468-75.
5. Yeung AT, Tsou PM. Posterolateral endoscopic excision for lumbar disc herniation: Surgical technique, outcome, and complications in 307 consecutive cases. Spine (Phila Pa 1976). 2002;1(27):722-31.
6. Hoogland T, van den Brekel-Dijkstra K, Schubert M, Miklitz B. Endoscopic transforaminal discectomy for recurrent lumbar disc herniation: a prospective, cohort evaluation of 262 consecutive cases. Spine (Phila Pa 1976). 2008;33(9):973-8.

CERVICAL ENDOSCOPIC DISC SURGERY: PRECISE APPROACH FOR MINIMALLY INVASIVE DECOMPRESSION

CIRURGIA DO DISCO ENDOSCÓPICO CERVICAL: ABORDAGEM PRECISA PARA DESCOMPRESSÃO MINIMAMENTE INVASIVA

CIRUGÍA DE DISCO CERVICAL ENDOSCÓPICA: ENFOQUE PRECISO PARA LA DESCOMPRESIÓN MÍNIMAMENTE INVASIVA

Artem Gushcha[1], Sergey Arestov[1], Andrey Vershinin[1], Alexey Kashcheev[1], Vladimir Tjurnikov[1], Maksim Dreval[1], Ekateryna Poltoraco[1], David Petrosyan[1]

1. Research Center of Neurology, Moscow, Russia.

ABSTRACT

Objective: Technological advances in recent decades have led to a complexity of choice of the most effective method for treating cervical disc herniations. The idea of removing disc herniations using endoscope techniques is not new, and is successfully used in the treatment of lumbar disc herniations. But in the case of the cervical spine, full endoscopic procedures only started to be performed at the beginning of 2014, by Yang JS and coauthors, and their effectiveness was and still is a matter of controversy. The proposed method of endoscopic portal disc herniation removal was used for the past two years, and its results were compared with the anterior microsurgical approach using a single-level cage implantation. Methods: Twenty-five patients were included in this study, with a comparator group of 25 patients operated by ordinary anterior cervical discectomy with a single-disc fusion. All patients were operated on by the same group of surgeons. Results: During the analysis of VAS data, it was confirmed that the degree of local and radicular pain in the two groups was not significantly different ($p > 0.05$). According to the Neck Disability Index (NDI) there was a significant difference between the two groups in relation to the endoscopic patient group. Data using the Odom criteria showed significantly better results for the endoscopic group. During the research it was observed that the patients in the endoscopically operated group were discharged from hospital more quickly, after 3 [2; 5] days compared to 5 [4; 6] days in the microsurgery group. Conclusion: The method performed is a safe and reliable alternative to convenient surgical techniques. ***Level of Evidenced II; Therapeutic study, investigating the results of treatment.***

Keywords: Humans; Intervertebral disc displacement; Diskectomy; Endoscopy; Cervical vertebrae; Neuroendoscopy.

RESUMO

Objetivo: Os avanços tecnológicos das últimas décadas determinaram a complexidade da escolha do método mais eficaz para o tratamento das hérnias discais cervicais. A idéia de remover hérnias de disco usando técnicas de endoscópios não é nova e é utilizada com sucesso no tratamento de hérnias discais lombares. Mas, no caso da coluna cervical, apenas procedimentos totalmente endoscópicos são realizados a partir de 2014 por Yang JS com coautores e sua eficácia foi e ainda é um assunto questionável. O método proposto de remoção da hérnia discal portal endoscópica foi utilizado durante os últimos 2 anos e seus resultados foram comparados com a abordagem microcirúrgica anterior utilizando um implante em gaiola de nível único. Método: 25 pacientes foram incluídos neste estudo, com um grupo comparativo de 25 pacientes operados por discectomia cervical anterior comum com uma fusão de disco único. Todos os pacientes foram operados com o mesmo grupo de cirurgiões. Resultados: Durante a análise dos dados da EAV confirmou-se que o grau de dor local e radicular nos dois grupos não foi significativamente diferente ($p > 0,05$). De acordo com o Neck Disability Index (NDI), houve uma diferença significativa entre dois grupos em relação ao grupo de pacientes endoscópicos. Dados usando critérios de Odom mostraram resultados significativamente melhores no grupo endoscópico. Durante a pesquisa, percebeu-se que os pacientes do grupo operado endoscopicamente tiveram alta mais rápida do hospital em 3 [2; 5] comparado com 5 [4; 6] dias no grupo microcirúrgico. Conclusão: O método realizado é uma alternativa segura e confiável para técnicas cirúrgicas convenientes. ***Nível de Evidência II; Estudos terapêuticos - Investigação dos resultados do tratamento.***

Descritores: *Seres humanos; Deslocamento do disco intervertebral; Disotomia; Endoscopia; Vértebras cervicais; Neuroendoscopía.*

RESUMEN

Objetivo: Los avances tecnológicos durante las últimas décadas han llevado a una elección compleja sobre el método más efectivo para el tratamiento de hernias de disco cervical. La idea de eliminar las hernias discales usando técnicas endoscópicas no es nueva y se utiliza con éxito en el tratamiento de las hernias de disco lumbar. Pero en el caso de la columna cervical, procedimientos totalmente endoscópicos solamente empezaran a ser realizados en el inicio de 2014, por Yang JS y coautores, y su efectividad era y sigue siendo un tema cuestionable. El método propuesto de remoción de la hernia discal endoscópica se utilizó durante los últimos 2 años y sus resultados se compararon con el enfoque microquirúrgico anterior utilizando una implantación de caja en un solo nivel. Métodos: Se incluyeron 25 pacientes en este estudio con un grupo comparativo de 25 pacientes operados por discectomía cervical anterior común con una fusión de disco único. Todos los pacientes fueron operados con el mismo grupo de cirujanos. Resultados: Durante el análisis de los datos de EVA, se

Study conducted at the Neurosurgical Department of Research Center of Neurology.
Correspondence: Sergey Arestov. Research Center of Neurology, 125367, Russia, Moscow, Volokolamskoe ave. 80 sarestov@gmail.com

CC BY

http://dx.doi.org/10.1590/S1808-185120181703191840

Coluna/*Columna.* 2018;17(3):206-11

Received on 02/20/2018 accepted on 07/25/2018

confirmó que el grado de dolor local y radicular en los dos grupos no fue significativamente diferente (p> 0,05). De acuerdo con el Índice de Discapacidad Cervical (NDI), hubo una diferencia significativa entre los dos grupos con respecto al grupo de pacientes endoscópicos. Los datos que utilizan los criterios de Odom mostraron resultados significativamente mejores en el grupo endoscópico. Durante la investigación, se observó que los pacientes del grupo que fuera operado endoscópicamente fueron dados de alta más rápidamente del hospital, en 3 [2; 5] días comparado con 5 [4; 6] días en el grupo microquirúrgico. Conclusión: El método realizado es una alternativa segura y confiable a las técnicas quirúrgicas convenientes. ***Niveles de Evidencia II; Estudios terapéuticos - Investigación de los resultados del tratamiento.***

Descriptores: *Seres humanos; Desplazamiento del disco intervertebral; Discectomía; Endoscopía; Vértebras cervicales; Neuroendoscopía.*

INTRODUCTION

The prevalence of discogenic compression syndromes at the cervical level is extremely high nowadays. Despite the relatively small proportion of cervical disc intervertebral lesions detected among the total number of degenerative spinal lesions, according to J.S. Lawrence,[1] around about 10% of the population experience periodic compression pain in the cervical spine or in the arm.

When assessing cervical disc herniation, a generally accepted classification of the staging of the formation of herniated intervertebral discs (protrusion, prolapse and sequestration) is that proposed by A.P. Decoulx[2], which is important in assessing the clinical course of the process and selecting the best form of treatment, as well as for classifying herniated intervertebral discs by their axial localization and relationship to the bone structures of the spinal canal. According to this, the median paramedian (laterally offset from the sagittal plane), lateral and foraminal hernias are distinguished.

Based on their analysis of a large number of clinical observations, J.H. Vland et al.[3] distinguish the characteristic clinical signs that accompany the course of radicular compression at the cervical level. These signs are of practical importance for determining the level of lesion and axial localization of the herniation. Along with the characteristic radicular incidence of the pain syndrome, sensitivity disorders, prolapse of the tendon reflexes corresponding to innervated dermatome, as well as paresthesia, indicating lateralization of the compressed root in the foraminal opening, are often detected. In cases where the data are unclear, the use of the Spurling test is recommended[4] (axial load on the neck with shaking from side to side).

J. Knightly conventionally identifies two pathoanatomical variants of the formation of the compression substrate at the level of the intervertebral disc - soft disc (fragments of the fallen or prolapsing disc as an acute phase of the disease) and hard disc - the "hard disc" (appearance of osteophytes and their enlargement as a chronic phase of the disease).[5] The structural state of the compressing factor, like its axial position, is the key, in our opinion, to the choice of surgical treatment tactics. In terms of clinical symptoms, patients with "soft disc" present predominantly brachialgia symptoms, often occurring after physical exertion, sudden head movement or neck trauma. The pain is acute radicular, spreading to the dermatomes, and often dependant on the position of the head and limbs. The spread of pain like a "helmet" or a homolateral half of the head, like a hemicranium, is very characteristic in these patients. Hypesthesia accompanying this kind of compression always extends to single dermatomes and may be accompanied by an isolated decrease in tendon reflexes from adjacent muscles. A more rare violation is a reduction in strength (paresis) in the proximal parts of the upper limbs, often of a one-sided and unstable nature.

The symptomatology that accompanies the development of "hard disc" is characterized by headaches and pains in the hands, usually symmetrical and symptoms usually characterized as headaches and pain in arms. These symptoms are mostly symmetrical and accompanied by localized unstable pain during palpation at the level of herniation having some diagnostic value.. In such a course of the disease, multiple areas of decreased sensitivity are characteristic, and may include conductive anesthesia from the level of the lesion, with decreased muscle strength below the affected segment, involving deep paresis in more severe cases. The peculiarity of the clinical symptom in patients with ossified compression formations in the vertebral canal of the cervical level is the presence of normo- or hyperreflexia, which is considered a probable consequence of chronic circulatory disturbance at the base of the anterior spinal artery.

Clinical symptoms in patients with "hard disc" progress much more slowly than those in "soft" hernias.

Traditional CT and MRI studies provide complementary information for the diagnosis of pathology. The first is preferred for detecting compression factors (hernia, osteophytes), while the second is used to detect the effects of the compression (compression of the spinal cord and roots). Bischoff (2003) investigated the sensitivity, specificity and accuracy of CT, MRI and myelography in determining the diagnosis of "herniated disc" and "stenosis of the spinal canal." The accuracy and sensitivity of CT was slightly higher than that of MRI. CT remains the best method for assessing central stenosis. MRI provides an image of the entire cervical spine and enables the identification of stenosis in the direct sagittal projection. (Figure 1)

Studies by Jan T. Wilmink[6] revealed the following clinico-radiographic correlations in CT.

1. Complete occlusion of the radicular opening by laterally migrated masses of the degenerated intervertebral disc ("soft disc") is always accompanied by radicular syndrome.

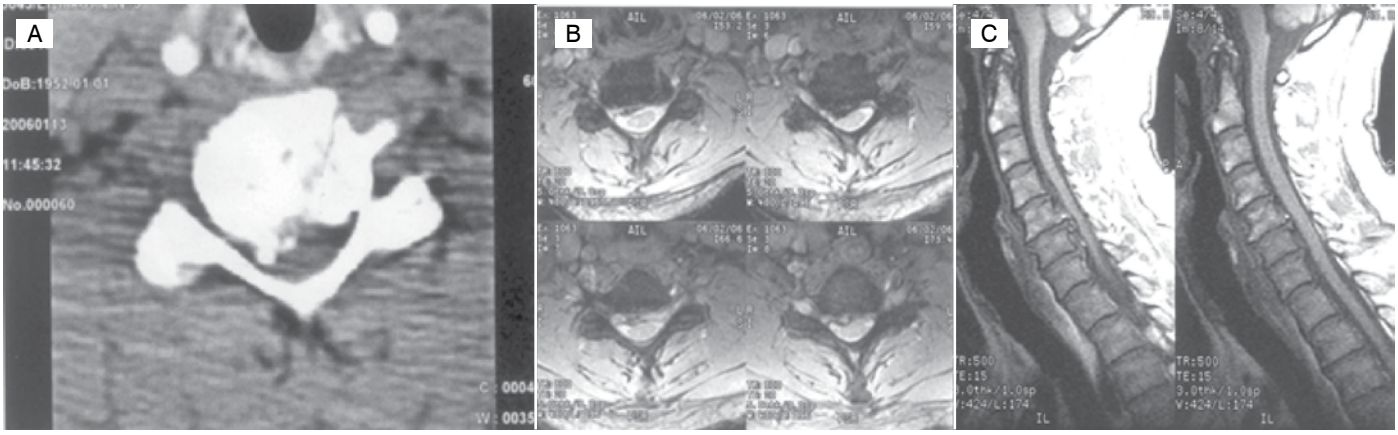

Figure 1. Diagnostic findings in patient with "soft" C6-C7 disc herniation. CT scans (A) accompanied with MRI (B, C) revealed characteristics of this lesion.

2. Narrowing of the intervertebral opening with an osteophyte ("hard disc") causes edema of the root and a less pronounced radicular syndrome in comparison with the first variant.
3. Paramedian protrusions of the disc, which do not cause complete occlusion of the radicular opening and express compression of the spinal cord, often leading to the development of radicular symptoms on the contralateral side to the hernia.

The treatment of compression syndromes caused by degenerative changes in the cervical spine has a fifty-year history, but despite this, there is still no single criterion for choosing the best surgical intervention. On one hand, this is understandable due to the continuous improvement of surgical interventions at the cervical level and the development of operations "design" the spine. On the other, notions of the pathogenesis and biomechanics of change have deepened. Over the past fifty years, both anterior and posterior accesses to spinal surgery have developed in parallel. The development of the anterior access through the interfascial spaces was carried out by a transverse or oblique incision along the anterior edge of the nipple muscle by many surgeons.[7,8] The history of posterior access begins in 1955, when D. Northfield proposed enlarged bilateral laminectomy one segment above and below the pathological level.[9] W. Scoville, in 1961, performed a limited bilateral laminectomy, supplemented by bilateral facet resection.[10] In the development of the posterior approaches, the goal was to decompress neural formations by removing the posterior support back arch of vertebrae and the spinous process. Of these accesses, it was not always possible to remove the compression formations located on the ventral surface of the spinal canal, although there were isolated reports of the removal of disc hernia and osteophytes of the vertebral bodies.[11] The posterolateral access includes posterior foraminotomy or facetectomy. This surgical technique was developed in 1944 by Spurling,[4] and later, in more detail, by Frykholm, Scoville[12] (keyhole technology). This kind of posterior access allowed a small incision to be made, to produce a foraminotomy and remove the disc hernia. However, due to the likelihood of neurological deficits and the need for segment stabilization, most neurosurgeons still prefer to use the safer anterior access.[13] Existing endoscopic methods involve intra-disc interventions that do not allow for significant decompression of the spinal canal structures in the required volume.

In our department, for the last ten years, portal endoscopic discectomy has been widely used to treat hernias of the intervertebral discs of the lumbar spine, the effectiveness and safety of which has been proven.[14] Since 2014, this technology has been successfully used to treat herniated intervertebral discs of the cervical spine. Based on our experience, a detailed description of the operation of portal endoscopic discectomy of herniated intervertebral discs of the cervical spine, and the most significant technical features of this method, are presented in this paper.

It should be noted that the application of the method for operations at the cervical level is described for the first time in detail in both the domestic and foreign literature. Analyzing the published data, we found a large number of studies dealing only with the use of the full endoscopic technology (i.e. operations at the cervical level through percutaneous approaches, both anterior and posterior, providing only foraminotomy).[15-17] It should be noted that in terms of technique, portal endoscopic methods at both the lumbar and cervical level are similar to microsurgical interventions, but they differ significantly from the latter in terms of the degree of trauma of soft tissues in accessing and in the quality of visualization.

METHODS

Our study included 25 patients with lateral disc herniations at level C5-C6 in 9 cases and C6-C7 in 16 cases, operated by endoscopic portal cervical discectomy. The control group consisted of 25 patients operated by microsurgical anterior cervical single-level discectomy with interbody fusion at levels C5-C6 and C6-C7. A more thorough analysis of these patients was described in previous papers.[14,15]

The patients of both groups were evaluated using the VAS score – radicular pain regression degree and timing, local cervical pain reduction based on the NDI (Neck Disability Index) - social adaptation of patients, and general recovery after surgery by the Odom criteria. The NDI enables the degree of social adaptation of the patient to be assessed based on the summation of points related to the ability to perform certain activities (walking, sleeping, reading, rest, etc.). The Odom criteria are used to characterize the effect of operation - from good to unsatisfactory. The evaluations using the NDI index and Odom test was carried out immediately before the patient's discharge. In addition, the estimated postoperative hospitalization time.

Statistical analysis was performed using the Mann-Whitney test to determine the reliability of results.

This study was approved by the local ethics committee of the Neurology Research Center of (protocol no. 2/15 of 2/10/15).

SURGICAL TECHNIQUE

Position on the operating table

The patient is placed on the operating table in the prone position with the hands and arms alongside the body. The head is laid on a soft headrest or fixed in a Mayfield clamp. The neutral position of the cervical spine is established.

Planning of the surgical incision

We used X-ray in the lateral position for surgical incision planning. Usually it was placed 1-2 cm lateral to the midline, depending on the patient's composition.

Operative access

After the incision is made, the aponeurosis of the muscles is cut and under X-ray guidance, an endoscopic tube introduced in the projection of the desired level. (Figure 2)

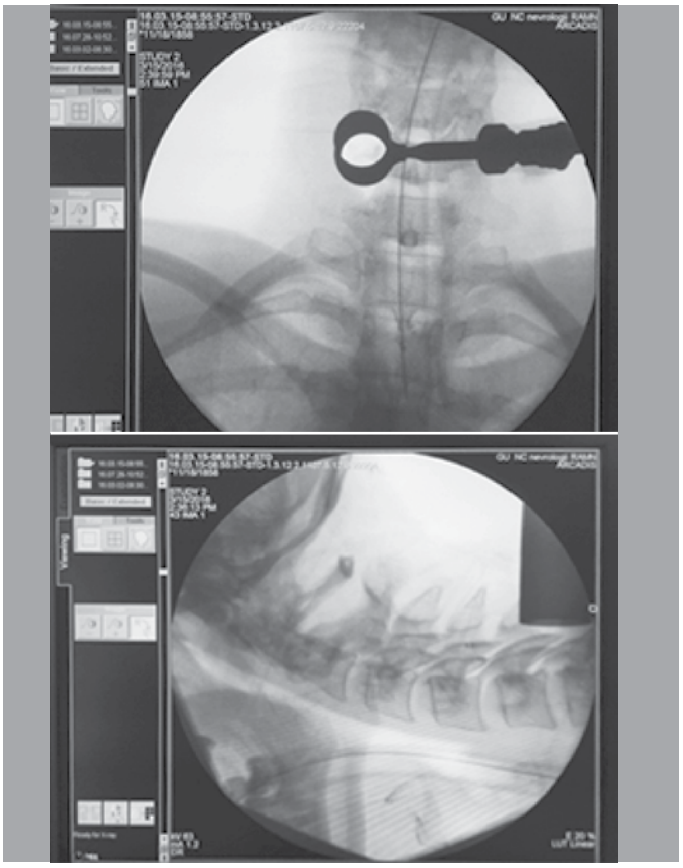

Figure 2. Fluoroscopic view of endoscopic port position.

The base of the lower articular process of lower vertebra is assumed as the optimal point for the installation of the port. After introducing the operating port, a slight resection of adjacent vertebral arches is performed, then the yellow ligament is exposed. If the port is properly installed, no significant resection of the intervertebral joint is required. However, various authors[16-18] warn that the removal of 25% to 50% of the intervertebral joint can lead to segmental instability. After removing the soft tissues from the intralaminar gap, the yellow ligament is opened - preferably as medially as possible.

Main stage of the operation

Usually just after the yellow ligament opening, a dural sack can be perfectly visualized. When it is released from the fatty tissue, a nerve root funnel can be reached. Sometimes the funnel may be covered by the medial part of facet joint, necessitating a marginal resection. Along the funnel and a portion of the venous plexus can usually be visualized. (Figure 3a) Reckless movements in this position can lead to substantial blood loss, even requiring converting to microsurgery due to a lack of visualization. Nevertheless, thorough dissection of veins and nerve root funnel makes it possible to visualize the disc herniation and perform its removal. (Figure 3b)

Wound closure

Layer wound suturing is performed. Particular attention is paid to restoring the integrity of muscle aponeuroses in the field of operational access.

In the early postoperative period, we advise the use of at least a mild cervical orthosis for 3 weeks to reduce axial load on the operated spinal-motor segment and discipline the patient in case of physical activity and what movements are not correct. and how to perform every-day activity correctly. That's a discipline. In case of russian people it's not sufficient to say when you can load your spine - you need to say that for example refrigerator movement is prohibited, barrel movement above 20 kilos is prohibited and soon.

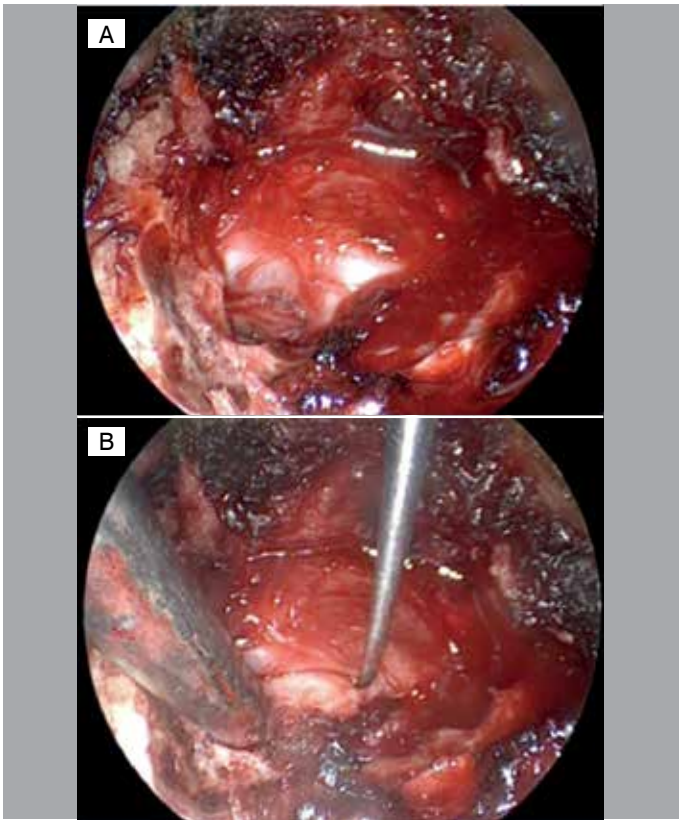

Figure 3. Main operation stage.

RESULTS

In both the study group and the control groups, there was no increase in the neurological deficit. In 2 (8%) patients in the group with endoscopic disc removal, transient numbness occurred in the zone of innervated dermatome, which had regressed completely by the time of discharge from hospital. In the preoperative period, the median intensity of the pain syndrome in the shoulder and forearm according to the Visual Analogue Scale (VAS) was 6 (3; 8) in the group with posterior endoscopic discectomy and 6 (4; 8) in the group with anterior microsurgical discectomy. After the operation, this indicator decreased to 1 (0; 6) in the group with endoscopic posterior discectomy, and 2 (1; 6) in the group with microsurgical anterior discectomy. In both groups, there was a significant decrease in pain syndrome ($p = 0.016$ and $p = 0.034$, respectively). Before discharge from hospital, the level of pain syndrome in the shoulder and forearm in the two groups did not differ significantly ($p > 0.05$). When assessing the pain syndrome in the neck, the comparability of the two groups in the preoperative period ($p > 0.05$) and a significant reduction in the level of pain in the postoperative period ($p = 0.024$ in the study group and $p = 0.034$ in the control group) were noted. (Table 1)

All patients of the study group immediately after the operation noted complete or near complete regression of the pain.

A significant improvement in the scores in patients who underwent endoscopic surgery was noted. The patients of both groups were subjectively satisfied with the result. With regard to the Odom test, there was also an advantage for the patients of the study group in terms of the number of excellent to good results. (Table 2)

Significant differences in postoperative hospitalization times were noted: in the study group, the term was 3 [2; 5] days, and in the control group, 5 [4; 6] days. In the study group, 1 (4%) patient noted the repeated appearance of radicular pain syndrome one week after the operation. The MRI data of this patient before and after the operation are shown in Figures 4 and 5.

Control MRI showed that the disc herniation is completely removed and the pain syndrome is not associated with its relapse. After receiving antineuritic therapy for 2 weeks, the pain syndrome completely regressed.

Table 1. Intensity of local pain in the neck and forearm according to the VAS.

	Group of patients who underwent the endoscopic procedure (N = 25)	Group of patients who underwent the anterior microsurgical procedure (N = 25)
Pain in forearm and shoulder		
Score before operation	6 [3; 8]	6 [4; 8]
Score before discharge	1 [0; 4]	2 [1; 6]
Mann-Whitney Test,	0.016	0.034
Local neck pain		
Score before operation	5 [2; 6]	6 [3; 7]
Score before discharge	1 [0; 3]	3 [1; 5]
Mann-Whitney Test,	0.024	0.034

Table 2. Outcome according to the NDI and Odom criteria.

	Group of patients who underwent the endoscopic procedure (N = 25)	Group of patients who underwent the anterior microsurgical procedure (N = 25)
NDI index median and interval scores		
Score before operation	24 [8; 32]	23 [6; 39]
Score before discharge	13 [5; 25]	13 [5;19]
Mann-Whitney Test,	0.056	0.026
Odom criterion (number of patients)		
Excellent to good	21	17
Average to bad	4	8

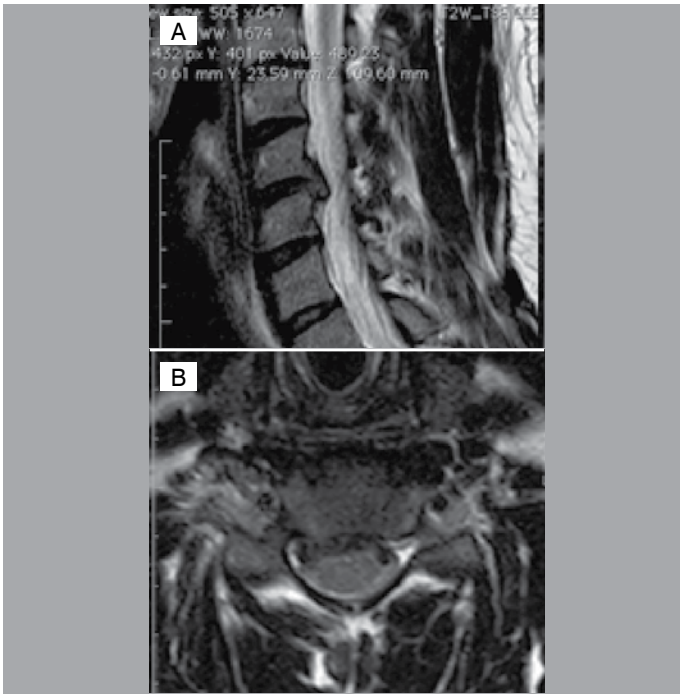

Figure 4. MRI before operation.

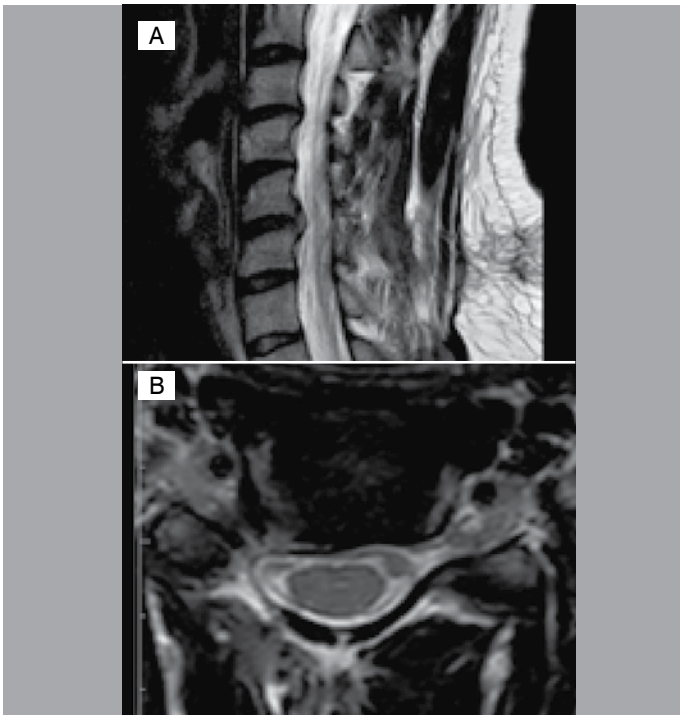

Figure 5. MRI after operation.

DISCUSSION

Although surgery for the treatment of compression syndromes represented by neurological and vascular disorders has existed for a long time,[15] there is still controversy surrounding the best approach. The main one is which approach option to choose to access the site of decompression - anterior or posterior. Both access routes enable the task to be fully carried out, the choice of access being determined by the site of the compressing factor, which is proven for single-level interventions.

According to H. Jho, expressed in a private conversation, posterior cervical foraminotomy has limitations in anterior compression with osteophyte, posterior compression with a univertebral joint and with a pronounced cicatricial process. Dealing with clinical syndrome of cervical radiculopathy requires an even more thorough examination of the patient, as it is often not accompanied by unambiguous radiographic evidence of the cause of compression, and almost never involves pathognomonic changes in the neurovascular structures. As the main criterion for deciding on the level of radiculopathy, greater reliability for detecting muscle atrophies in the corresponding muscles has been proven. Modern neuroimaging methods enable us to determine the nature of the compressing factor: "soft" (herniated intervertebral disc) or "hard" (osteophyte or bone spur) - this is decisive in the choice of surgical access. In the presence of a lateral soft disc, a posterior endoscopic portal removal is shown, whereas an osteophyte in this zone can be more radically eliminated by a ventral approach. The nature of the compressing factor in cervical radiculopathy syndrome should also be considered in relation to neurological symptoms. In the presence of an osteophyte, the severity of radicular symptoms (especially pain) is significantly lower than in the formation of a "soft" hernia.

The ineffectiveness of surgical treatment of patients with radiculopathy, according to our data, is due mainly to the underestimation of neurological symptoms and the interpretation of neuroimaging data. In particular, the paramedian location of the herniated intervertebral disc is often accompanied by radicular symptoms in the opposite arm. Ignorance of this fact can cause inadequate choice of the side of surgical access and, accordingly, lack of clinical effectiveness of the operation.

A significant factor in selecting the surgical access is confirmed deformity of the spine and identified segmental instability. Kyphosis of the cervical region, associated with degenerative process in the vertebrae, always involves the use of ventral access with appropriate stabilizing measures.

Based on the data obtained and the results of the operations performed, we developed an algorithm for selecting surgical access in the formation of spinal cord compression at the cervical level. (Figure 6)

The use of endoscopic microdiscectomy in the treatment of herniated intervertebral discs of the cervical spine has rather high efficiency and allows clinical results to be achieved with significantly lower operational injury. The technical features and proposed recommendations revealed by us will contribute to the wider introduction of this promising low-traumatic method in neurosurgical practice.

CONCLUSION

Our studies demonstrate the safety and effectiveness of the posterior portal endoscopic discectomy method. This type of intervention, with fairly clear ideas about the anatomical features of the compressing factor, is more effective than other operations in terms of speed of rehabilitation and social adaptation of patients, and also shortens the postoperative hospital times.

Based on our results, we propose and approve indications and contraindications for cervical portal endoscopic discectomy.

This operation is indicated if:

- the clinical data from radiculopathy corresponds to the side and the level of lesion detected during MRI/CT examination;
- CT/MRI data confirm the compliance of the "soft" compression of the spine located in the lateral third of the diameter of the vertebral canal, the clinical symptoms of the disease;
- There is no effect of conservative treatment, conducted over 3 weeks.

The operation is contraindicated if:

- there are signs of segmental instability;
- there is a kyphotic deformation of the spine at the level of disc herniation.

All authors declare no potential conflict of interest related to this article.

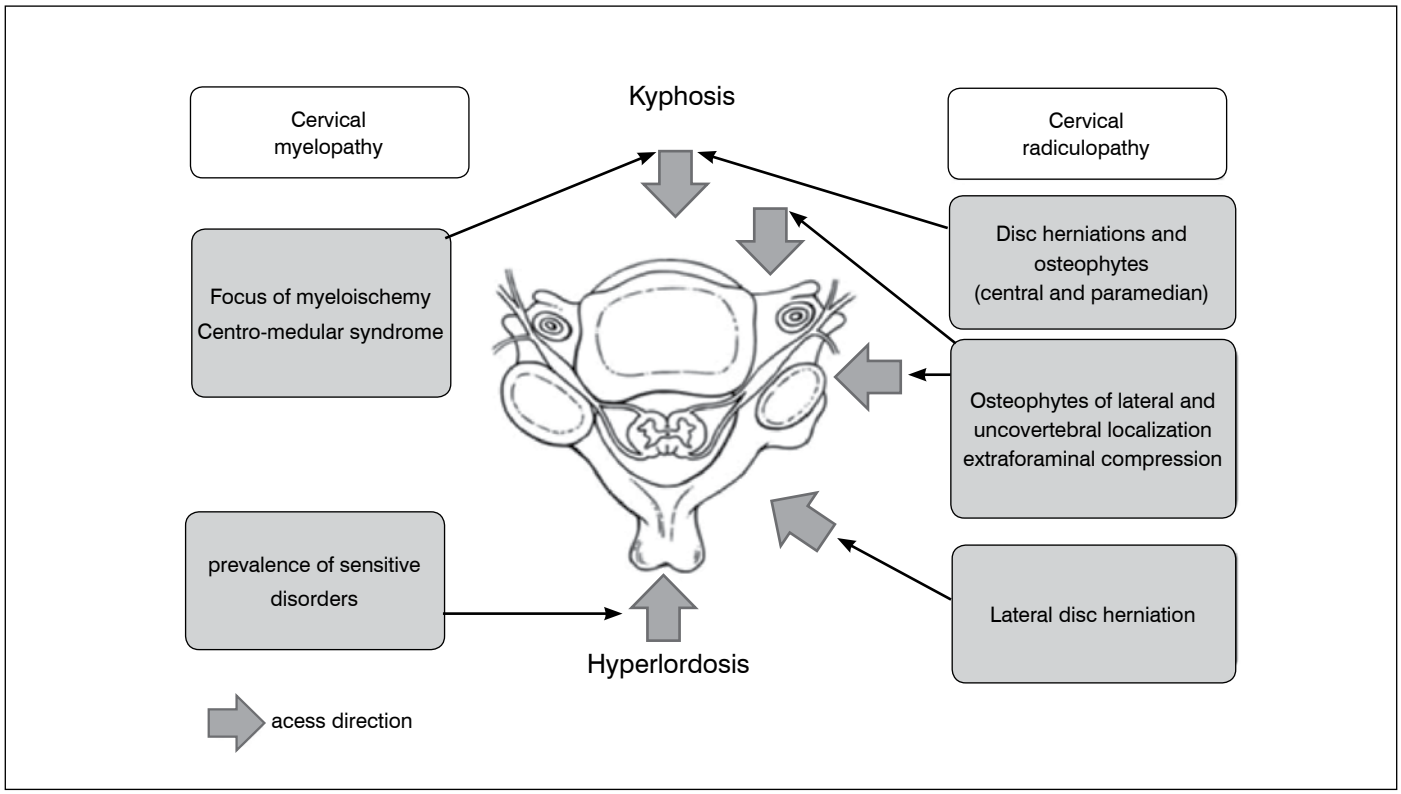

Figure 6. Algorithm of preferred surgical access to the cervical spine.

CONTRIBUTION OF THE AUTHORS: AG (0000-0003-3451-5750)*, SA (0000-0003-4809-4117)* and AV (0000-0002-8006-1334)* actively and equally performed listed below operations and actively contributed to this article. AK (0000-0001- 7681-3073)* and MD (0000-0002-7839-309X)* assisted in surgery, followed up the patients and gathered clinical data. EP (0000-0001-9208-2987)* and DP (0000-0001-9588-7721)* evaluated the data from the statistical analysis. VT (0000-0003-4881-4241)* performed the literature search and review of the manuscript, and contributed to the intellectual concept of the study. *ORCID (Open Researcher and Contributor ID).

REFERENCES

1. Lawrence JC. Disc degeneration: its frequency and relationship to symptoms. Ann Rheum Dis. 1969;28(2):121-38.
2. Decoulx P, Houcke E, Razemon JP, Lemerle P. Anatomie pathologique de la hernie discale. Presse Med. 1958;66(40):899-902.
3. Bland J.H. Disorders of the Cervical Spine: Diagnosis & medical management. 2nd ed. Philadelphia: WB Saunders Company, 1994
4. Popelyansky Ya.Yu. Bolezni perifericheskoy nervnoy sistemi: Guidelines. Moscow: Medicine, 1989.
5. Knightly JJ, Greene KA, Marciano FF, Ronderos JF, Sonntag VK. Locked facets and disc herniation. J .Neurosurg. 1994;80(5):952-3.
6. Wilmink JT, Hofman PAM. T2-weighted 3D FSE MR myelography in the cervical spine: comparison of 2 techniques. Neuroradiology. 1995;37(Suppl. S56): 56.
7. Smith GW, Robinson RA. The treatment of certain cervical-spine disorders by anterior removal of the intervertebral disc and interbody fusion. J.Bone Joint Surg Am. 1958;40-A(3):607-24.
8. Szpalski M, Gunzburg R (Eds). The Degenerative Cervical Spine. Philadelphia: Lippincott Williams & Wilkins; 2001.
9. Shen FH, Samartzis D, Khanna N, Goldberg EJ, An H. Comparison of clinical and radiographic outcome in instrumented anterior cervical discectomy and fusion with or without direct uncovertebral joint decompression. Spine J. 2004:4(6):629-35.
10. Spurling RG, Segerberg LH. Lateral intervertebral disk lesions in the lower cervical region. J Am Med Assoc. 1953;151(5):354-9.
11. Shevelev IN, Goushcha AO. Degenerative and dystrophic diseases. Moscow: Publishing house of Vladimir Levin; 2010.
12. Guscha AO, Arestov SO. Endoscopic Spinal Surgery. Moscow: GEOTAR-Media; 2010.
13. Yang JS, Chu L, Chen L, Chen F, Ke ZY, Deng ZL. Anterior or posterior approach of full-endoscopic cervical discectomy for cervical intervertebral disc herniation? A comparative cohort study. Spine (Phila Pa 1976). 2014;39(21):1743-50.
14. Li XC, Zhong CF, Deng GB, Liang RW, Huang CM. Full-Endoscopic Procedures Versus Traditional Discectomy Surgery for Discectomy: A Systematic Review and Meta-analysis of Current Global Clinical Trials. Pain Physician. 2016;19(3):103-18.
15. Nowinski GP, Visarius H, Nolte LP, Herkowitz HN. A biomechanical comparison of cervical laminoplasty and cervical laminectomy with progressive facetectomy. Spine (Phila Pa 1976). 1993;18(14):1995-2004.
16. Raynor RB, Pugh J, Shapiro I. Cervical facetectomy and its effect on spine strength. J Neurosurg. 1995;63(2):278–82.
17. Zdeblick TA, Ducker TB. The use of freeze-dried allograft bone for anterior cervical fusions. Spine (Phila Pa 1976). 1991;16(7):726-9.
18. Goushcha AO, Arestov SO. Torakoscopicheskaya chirurgiya v lecheniyi novoobrazovaniy pozvonochnika i paraspinal'nih opuholey. Russian traumotology and orthopedy. 2010;2(56):129-31.

SPINAL CORD STIMULATION FOR FAIL BACK SURGERY SYNDROME: LITERATURE REVIEW AND CLINICAL STUDY

ESTIMULACIÓN DE LA MÉDULA ESPINAL PARA EL SÍNDROME DE CIRUGÍA DE ESPALDA FALLIDA: REVISIÓN DE LA LITERATURA Y ESTUDIO CLÍNICO

ESTIMULAÇÃO DA MEDULA ESPINHAL PARA SÍNDROME DE CIRURGIA DE RETORNO: REVISÃO DA LITERATURA E ESTUDO CLÍNICO

Kashcheev Alexey Alexeevich[1], Gushcha Artem Olegovich[1], Tjurnikov Vladimir Mikhaylovich[1], Arestov Sergey Olegovich[1], Vershinin Andrey Vyacheslavovich[1], Dreval' Maxim Dmitrievich[1], Poltorako Ekaterina Nikolaevna[1], Petrosyan David Vazgenovich[1]

1. Research Center of Neurology, Department of Neurosurgery, Volokolamskoe Road, Moscow.

ABSTRACT

Objective: Fail back surgery syndrome (FBSS) is a common cause of pain following spine surgery, and is associated with persistent or recurrent pain despite anatomically correct intervention. Spinal cord stimulation (SCS) is regarded as one of the most effective methods of treatment for fail back surgery syndrome. Methods: We studied 34 patients who underwent test stimulation and chronic SCS for FBSS. Results: Six months postoperatively, mean improvement by the visual analog scale (VAS) of average and maximum daily pain, and the painDETECT score, were 54.4%, 50.7% and 57.3%, respectively. This meets the criteria for effectiveness of the method, according to the literature. Most of patients reported significant improvements in life quality and less need for analgesics. Complications were seen in nine patients (26.4%) and included: intraoperative dura injury (one patient, 2.9%), wound infection (one patient, 2.9%), and electrode displacement (seven patients, 20.5%). No cases of postoperative neurological deterioration were seen. Conclusions: SCS is safe and effective for the treatment of neuropathic pain caused by FBSS. ***Level of Evidence IV; Case series.***

Keywords: Spinal Cord Stimulation; Neuralgia; Failed Back Surgery Syndrome.

RESUMO

Objetivos: A síndrome da cirurgia de falência reversa (SAF) é uma causa comum de dor após cirurgia de coluna e associada a dor persistente ou recorrente, apesar da intervenção anatomicamente correta. Estimulação da medula espinhal (SCS) é considerado como um dos métodos mais eficazes de tratamento para a síndrome de cirurgia de retorno. Métodos: Foram estudados 34 pacientes submetidos a estimulação de teste e SCS crônica para FBSS. Resultados: 6 meses de pós-operatório melhora a média de dor diária média e máxima diária na escala análoga visual (VAS), bem como a pontuação do PainDetect foram de 54,4%, 50,7% e 57,3%, respectivamente. Ele atende aos critérios de eficácia do método, de acordo com a literatura. A maioria dos pacientes relatou melhora significativa da qualidade de vida e menor necessidade de analgésicos. As complicações foram observadas em nove pacientes (26,4%) e incluíram: lesão da dura-máter intraoperatória (um paciente, 2,9%), infecção da ferida (um paciente, 2,9%), deslocamento do eletrodo (sete pacientes, 20,5%). Não houve casos de deterioração neurológica no pós-operatório. Conclusões: A SCS é segura e eficaz para o tratamento da dor neuropática causada pela FBSS. ***Nível de Evidência IV; Séries de casos.***

Descritores: *Estimulação da medula Espinal; Neuralgia, Síndrome pós – lamenectomia.*

RESUMEN

Objetivo: El síndrome de cirugía de espalda fallida (FBSS) es una razón común para el dolor después de la cirugía de la columna vertebral y se asocia con dolor persistente o recurrente a pesar de la intervención anatómicamente correcta. La estimulación de la médula espinal (SCS) se considera uno de los métodos de tratamiento más eficaces para el síndrome de cirugía de espalda fallida. Métodos: Se estudiaron 34 pacientes que se sometieron a estimulación de prueba y SCS crónica para FBSS. Resultados: A los seis meses la mejora promedio postoperatoria por la escala visual análoga (EVA) del dolor diario promedio y máximo diario, así como el puntaje de painDETECT fueron 54,4%, 50,7% y 57,3%, respectivamente. Esto cumple con los criterios de efectividad del método, según la literatura. La mayoría de los pacientes informaron una mejoría significativa de la calidad de vida y una menor necesidad de analgésicos. Las complicaciones se observaron en nueve pacientes (26,4%) e incluyeron: lesión duramadre intraoperatoria (uno paciente, 2,9%), infección de la herida (uno paciente, 2,9%), desplazamiento del electrodo (siete pacientes, 20,5%). No se observaron casos de deterioro neurológico postoperatorio. Conclusiones: SCS es seguro y efectivo para el tratamiento del dolor neuropático causado por FBSS. ***Nivel de Evidencia IV; Series de casos.***

Descriptores: *Estimulación de la médula espinal; Neuralgia; Sindrome de fracaso de la cirugía espinal lumbar.*

Study conducted at Federal State Research Institution, Research Center of Neurology, Department of Neurosurgery.
Correspondence: A. A. Kashcheev 80 Volokolamskoe Road, Moscow 125367. +7(903)573-5496. akascheev@endospine.ru

CC BY

http://dx.doi.org/10.1590/S1808-185120181703193251

Coluna/*Columna*. 2018;17(3):212-5

Received on 03/21/2018 accepted on 07/25/2018

INTRODUCTION

Spine surgery is one of the most rapidly developing fields of modern medicine, and more than 1,000,000 spine operations are currently performed each year, worldwide.[1] Thanks to minimally invasive, endoscopic and percutaneous technologies, the number of intraoperative and early postoperative complications has decreased and the overall postoperative results have dramatically improved.

Nevertheless, the incidence of late postoperative complications is still high.[2] One of the main such complications is fail back surgery syndrome (FBSS, or post-laminectomy syndrome), a term that is still controversial. According to different authors, FBSS can be defined as "Persistent or recurrent pain in the back/neck or limbs, despite surgery or treatment thought likely to relieve pain",[3] "Chronic radicular pain that has recurred or persists in the same distribution despite anatomically satisfactory previous spinal surgery",[4,5] "Lumbar (cervical) pain of unknown origin either persisting despite surgical intervention or appearing after surgical intervention for spinal (origin) pain originally in the same topographical distribution".[6] As a result, we can emphasize that FBSS always has the following characteristics: chronic neuropathic pain, history of spine surgery (or surgeries), absence of clear etiologic factor of pain, and anatomically correct primary spine surgery.

One of the most modern and encouraging methods of treatment for FBSS is spinal cord stimulation (SCS).

METHODS

Patients with FBSS treated by chronic SCS in the neurosurgical department of the Research Center of Neurology from 2014 to 2017 were prospectively included in our study. All patients signed an Informed Consent Form. The study was approved by the local Ethics Committee of the Research Center of Neurology.

The extended preoperative clinical examination included:

- neurological examination (by a neurosurgeon and neurologist, independently);
- medical history;
- visual analog scales (VAS) of pain, painDETECT score, Beck depression inventory;
- magnetic resonance imaging (MRI), computed tomography (CT), dynamic X-Ray;
- neurophysiological examination (electroneuromyography, transcranial magnetic stimulation);
- test X-Ray assisted blockages;
- standard preoperative tests and examinations (blood and urine tests, ECG, chest X-Ray);
- other methods, if needed (densitometry, ultrasound etc).

The Inclusion criteria were as follows:

- neuropathic pain, everyday VAS score ≥ 4, painDETECT score ≥ 19;
- no indications for direct revision surgery;
- no effect of correct conservative pain management for 3-6 months (estimated by a neurosurgeon and neurologist, independently).

The Exclusion criteria were as follows:

- clear correlation between body position and pain, indications for revision surgery, satisfactory or good effect of conservative pain management;
- radicular or conduction pain;
- severe depression (Beck depression inventory ≥ 20), attempted suicide, mental disorders troubling patient education and/or decreasing compliance;
- severe comorbidities;
- negative test stimulation.

All patients underwent two-stage implantation of SCS systems produced by two different manufacturers (St. Jude and Medtronic). The First stage included test stimulation to estimate the coverage and clinical effect of the stimulation.

The epidural space was punctured percutaneously at level L2-L3 under local anesthesia, using a Tuohy needle. The needle position was verified by a common method (loss of resistance) and intraoperative X-Ray. An electrode was then implanted using fluoroscopic control at level Th7-Th12, depending on the site of the pain. (Figure 1) The technical feasibility of electrode implantation strongly depended on epidural scarring.

Intraoperative testing was normally performed at a frequency 60 Hz, pulse width 300 msec. The results of the intraoperative testing were regarded as positive if the patient felt paresthesia and a feeling of vibration in the region of pain. It is important that these feelings should be tolerable and comfortable for patient. At higher frequencies, muscle fibrillation can be seen in the corresponding group of muscles.

The test electrode was pulled through the counteropening in the lumbar region and fixed by suture. (Figure 2) Patient can walk immediately after surgery.

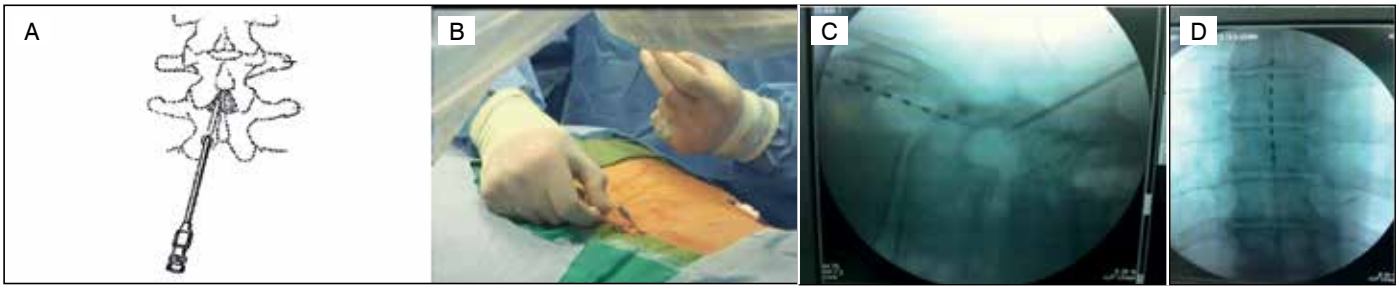

Figure 1. Implantation of test electrode for SCS: A – Needle insertion (angle not more than 30 °); B – gauge insertion; C, D – electrode is located dorsally on Th9-Th10 (A/P and lateral view).



Figure 2. Intraoperative test: A, B – Connection of electrode with extension; C – intraoperative X-Ray (1 – 8 contacts of electrode; 2 – connector of extension).

During the test period (1-10 days) the results of pain relief were estimated using the pain scales and patient's questionnaire. Reprogramming can also be done if needed. (Figure 3) The main parameters of stimulation are level of perception and level of comfort.

If the test was effective, the second stage (generator implantation) was performed.

The site of electrode insertion was revised and the extension removed. The site of generator implantation ('pocket') was prepared, normally in the right gluteal region (if the patient was right-handed). The generator was connected to the electrode and intraoperative testing, as well as Z-Ray control, were performed. The wounds were closed. (Figure 4) Patient can walk immediately after surgery.

The aim of the postoperative period was to program different modes for stimulation (i.e., for sleeping, walking, the sitting position etc).

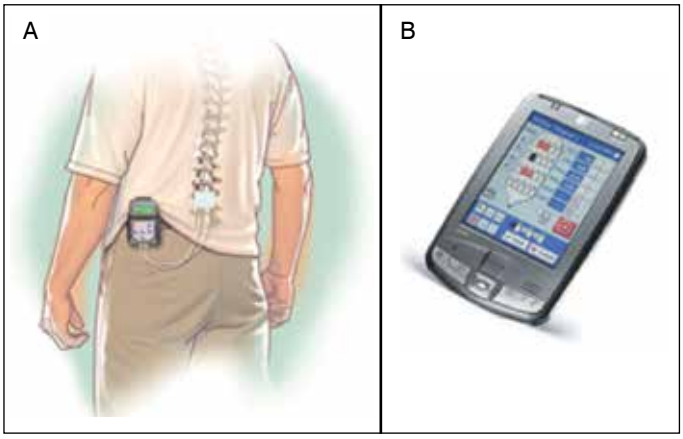

Figure 3. Test period: A – Test electrode and extension are connected to the patient's programmer; B – physician's programmer.

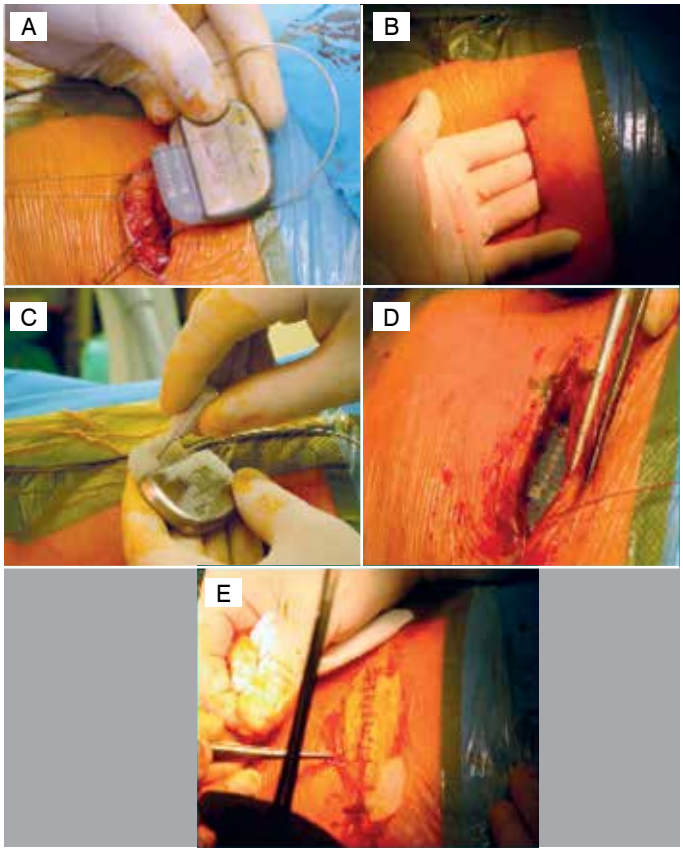

Figure 4. Implantation of permanent system for chronic SCS: A – Generator; B – "Pocket" for generator; C – connection of generator and electrode; D – connector; e – wound closure.

The level of comfort depended on the body position during the first two-to-three months postoperatively.

Results were estimated six months postoperatively by following parameters: visual analog scale (VAS) of daily average and maximum daily pain; painDETECT score; postoperative complications.

RESULTS

Thirty-four patients met the inclusion criteria, were included in the study and operated via both stages of SCS system implantation. Five patients (12.8% from the primary selection) matched the inclusion criteria but were excluded because of negative test stimulation results.

Nineteen patients (55.8%) were male, 15 – female (44.2%); age varied from 29 to 82 years. The number of previous lumbar surgeries was: 1 (11.7%), 2 (32.3%), 3 (26.5%), 4 (17.6%), 5 (5.9%), 6 (3.0%) и 7 (3.0%). Twenty patients (58.8%) underwent fusion before SCS.

The mean hospitalization time was 12.9 days.

Six months postoperatively clear pain relief was demonstrated by all three studied parameters. (Table 1)

Complications were seen in nine patients (26.4%) and included: intraoperative dura injury (one patient, 2.9%), wound infection (one patient, 2.9%), and electrode displacement requiring surgical correction (seven patients, 20.5%). No cases of postoperative neurological deterioration were seen.

Tabela 1. Preoperative and postoperative neuropathic pain syndrome.

Parameter	Preoperative score	Postoperative score (6 months)	Mean improvement
VAS: daily average pain	5-9 (6.8)	0-7 (3.1)	54.4%
VAS: daily maximum pain	5-9 (7.1)	0-7 (3.5)	50.7%
Pain detect	19-36 (27.2)	3-20 (11.6)	57.3%

DISCUSSION

According to relevant clinical studies, fail back surgery syndrome (FBSS) is a common condition with prevalence ranging from 10% to 40%.[7] FBSS develops around 4.7 years after primary surgery.[8] FBSS significantly decreases quality of life, and leads to multiple revisions (rate of revisions – 4%-19%),[9] chronic pain, depression, medical and social impairment, disability and the need for of medical treatment. Patients with FBSS permanently take antidepressants (38%), anticonvulsants (38%), and opioid analgesics (62%),[10] 86% of patients have to use more than four methods of conservative management simultaneously.[11] As a result, FBSS is a serious medical and social problem.

Multiple studies have shown effectiveness of SCS for FBSS. To date, after SCS was invented by CN Shealy in 1967 more than 200,000 SCS systems have implanted worldwide, with more than 25,000 implanted each year.[12,13] FBSS is one of the most evidence-based indications for SCS.[14] A prospective, randomized, multicenter, international, controlled study EVIDENCE trial of 132 patients with FBSS showed stable pain relief in leg or legs (more than 50% from baseline) 6-24 months postoperatively.[15] The multicenter, randomized PROCESS trial demonstrated pain relief of 50%-70% and a statistically significant reduction of drug intake.[16] RB North et al. showed that in USA SCS for FBSS is 17-53% less expensive and more effective than reoperation.[17] Retrospective studies (410 patients) also showed that 60% of patients had pain relief of more than 50%.[18] Available data in the Russian literature confirm these results: SCS was effective in early and late periods with a more than 75% decrease in analgesic drug intake in a group of more than 100 patients operated at the Neurosurgical

Institute named after N.N. Burdenko.[19] Another study on 45 patients showed that SCS is more effective than conservative pain management for SCS.[20]

Our results are comparable with those of other authors; pain relief varies from 50% to 60% depending on the measurement scale used. According to common opinion, test stimulation effectiveness of less than 50% should be regarded as a negative result. Nevertheless 4 of our 34 patients had less than 50% pain relief during the test, but claimed that they wanted the whole SCS system to be implanted as even this pain relief is still important for their quality of life. In some of our patients pain relief in the initial months after implantation was higher than in long-term; this can be explained by phenomenon of neural tolerance, and corresponds to the finding of Isagulyan ID, Tomsky AA et al.[21] The rate of technical complications in our group was fairly high (20.5%). This can be explained by learning curve that our surgical team underwent: most complications were seen during 1st year of mastering the SCS technique. It is interesting that in all patients with long fusions for deformity correction, it was feasible to implant the electrode percutaneously and avoid open surgery.

CONCLUSIONS

SCS is an effective method of the treatment for intractable neuropathic pain caused by FBSS. Chronic SCS led to ≥50% pain relief, significantly improved quality of life, reduced the need for analgesic medications, and helped avoid unnecessary revisions. Adherence to strict indications and precise patient selection are crucial for successful SCS. Neurostimulation in most cases is safe for the patient, and technically feasible; complications include electrode migration, which can be easily corrected. New methods of stimulation such as high-frequency stimulation and non-invasive external generators will improve the results of treatment and decrease the rate of complications. Long-term results of SCS for FBSS should be estimated, while enlarging the study group. We presume that patients with FBSS require a multidisciplinary approach, with the participation of neurosurgeons, neurologists, orthopedists, rehabilitation specialists and other staff.

All authors declare no potential conflict of interest related to this article.

CONTRIBUTION OF THE AUTHORS: Each author made significant individual contributions to this manuscript. AG (0000-0003-3451-5750)* and AK (0000-0001-7681-3073)* were the main contributors to the drafting of the manuscript. AG and AK carried out the surgery, followed up patients and gathered clinical data. AK and AG evaluated the data from the statistical analysis. VT (0000-0003-4881-4241)*, SA (0000-0003-4809-4117)*, AV (0000-0002-8006-1334)*, MD (0000-0002-7839-309X)*, EP (0000-0001-9208-2987)* and DP (0000-0001-9588-7721)* performed the literature search and review of the manuscript, and contributed to the intellectual concept of the study. *ORCID (Open Researcher and Contributor ID).

REFERENCES

1. Tulkin ON, Nazarov AS, Davydov EA, Bersnev VP. Characteristics of clinical presentations of Failed Back Surgery Syndrome. Translational Medicine. 2015;2(3):31-2.
2. Taylor RS. Epidemiology of refractory neuropathic pain. Pain Pract. 2006;6(1):22-6.
3. Kumar K, Taylor RS, Jacques L, Eldabe S, Meglio M, Molet J et al. Spinal cord stimulation versus conventional medical management for neuropathic pain: a multicentre randomised controlled trial in patients with failed back surgery syndrome. Pain. 2007;132(1-2):179-88.
4. Kumar K, Taylor RS, Jacques L, Eldabe S, Meglio M, Molet J et al. The effects of spinal cord stimulation in neuropathic pain are sustained: a 24-month follow-up of the prospective randomized controlled multicenter trial of the effectiveness of spinal cord stimulation. Neurosurgery. 2008;63(4):762-70.
5. Leveque JC, Villavicencio AT, Rubin L, Bulsara K, Gorecki JP. Spinal cord stimulation for failed back surgery syndrome. Neuromodulation. 2001;4(1):1–9.
6. Merskey H, Bogduk N. Lumbar spinal or radicular pain after failed spinal surgery. In: Merskey H, Bogduk, N, editors. Classification of Chronic Pain. Seattle: IASP Press; 1994. p. 179.
7. Hoy D, Brooks P, Blyth F, Buchbinder R. The epidemiology of low back pain. Best Pract Res Clin Rheumatol. 2010;24(6):769-81.
8. Follet KA, Dirks BA. Etiology and evaluation of the failed back surgery syndrome. Neurosurg Q. 1993;3(1):40–59.
9. Durand G, Girodon J, Debiais F. Medical management of failed back surgery syndrome in Europe: evaluation modalities and treatment proposals. Neurochirurgie. 2015;61(Suppl 1):S57-65.
10. Thomson S, Jacques L. Demographic characteristics of patients with severe neuropathic pain secondary to failed back surgery syndrome. Pain Pract. 2009;9(3): 206–15.
11. Ragab A, Deshazo RD. Management of back pain in patients with previous back surgery. Am J Med. 2008;121(4):272–8.
12. Shealy CN, Mortimer JT, Reswick JB. Electrical inhibition of pain by stimulation of the dorsal columns: preliminary clinical report. Anesth Analg. 1967;46(4):489–91.
13. Kreis P, Fishman S. Spinal cord stimulation percutaneous implantation techniques. New York: Oxford University Press; 2009.
14. Isagulyan ED, Shabalov VA. Chronic Spinal Cord Stimulation in treatment of Failed Back Surgery Syndrome. Hirurgia Pozvonochnika. 2015;12(3):33-43.
15. North RB, Kumar K, Wallace MS, Henderson JM, Shipley J, Hernandez J et al. Spinal Cord Stimulation versus re-operation in patients with failed back surgery syndrome: an international multicenter randomized controlled trial (EVIDENCE study). Neuromodulation. 2011;14(4):330-5.
16. Kumar K, North R, Taylor R, Sculpher M, den Abeele C, Gehring M et al. Spinal Cord Stimulation vs. Conventional Medical Management: A Prospective, Randomized, Controlled, Multicenter Study of Patients with Failed Back Surgery Syndrome (PROCESS Study). Neuromodulation. 2005;8(4):213-8.
17. North RB, Kidd D, Shipley J, Taylor RS. Spinal cord stimulation versus reoperation for failed back surgery syndrome: a cost effectiveness and cost utility analysis based on a randomized, controlled trial. Neurosurgery. 2007;61(2):361-8.
18. Kumar K, Hunter G, Demeria D. Spinal cord stimulation in treatment of chronic benign pain: challenges in treatment planning and present status, a 22-year experience. Neurosurgery. 2006;58(3):481-96.
19. Isagulyan ED, Tomskij AA, Shabalov VA, Salova EM. Chronic electrical stimulation of the spinal cord for failed back surgery syndrome. Hirurgiâ Pozvonocnika. 2015;12(3):33-43.
20. Morozov IN, Ushakov AI. Neuromodulation for Refractory Failed Back Surgery Syndrome Patients. Sovremennyje technologii v medicine. 2015;7(3):90-4.
21. Isagulyan ED, Tomsky AA, Dekopov AV, Salova EM, Troshina EM, Dorokhov EV, et al. Results of motor cortex stimulation in the treatment of chronic pain syndromes]. Zh Vopr Neirokhir Im N N Burdenko. 2015;79(6):46-60.

COMPARISON OF SURGICAL INTERVENTIONS FOR DEGENERATIVE DEFORMITIES AND INSTABILITY OF THE SPINE AMONG ELDERLY PATIENTS

A COMPARAÇÃO DE INTERVENÇÕES CIRÚRGICAS PARA PACIENTES IDOSOS COM DEFORMAÇÕES DEGENERATIVAS E INSTABILIDADE DA COLUNA VERTEBRAL

COMPARACIÓN DE INTERVENCIONES QUIRÚRGICAS PARA PACIENTES ANCIANOS CON DEFORMACIONES DEGENERATIVAS E INESTABILIDAD DE LA COLUMNA VERTEBRAL

Dmitrii Mikhaylov[1], Anton Denisov[1], Dmitrii Ptashnikov[1], Sergei Masevnin[1], Nikita Zaborovskii[1]

1. Spine Surgery and Oncology Department R. R.Vreden Russian Research Institute of Traumatology and Orthopedics. Saint Petersburg, Russia.

ABSTRACT

Objective: To evaluate the surgical results among elderly patients with degenerative deformities and instability of the spine. Methods: A retrospective study of 437 patients (337 women, 100 men) with a mean age 60. The mean follow-up time was five years. The inclusion criteria were diseases and complications following spinal trauma associated with deformities, degenerative processes, acute pain syndrome, and spinal stenosis with neurological deficit. Four study groups (A, B, C and D) were created and defined by type of surgical intervention. Group A patients (the reference group) - decompression of neural structures on both sides without fixation. Group B - decompression and transpedicular fixation performed without correction of the deformity. Group C - patients operated up to the lower-thoracic region with transpedicular screws, correction of the deformity and decompression of spinal stenosis. Group D - transpedicular fixation up to higher-thoracic region; correction of the deformity and decompression of neurological structures. The mean follow-up time was five years. Results: Group D patients achieved the best outcome. The results observed were good in 57.2% of cases (60 patients); satisfactory in 40% of cases (42 patients); and unsatisfactory in 2.8% of cases (three patients).The worst findings were observed in Group A: satisfactory in 13.4% of cases (15 patients); and, unsatisfactory in 86.6% of cases (97 patients). No good results were observed in this group. Conclusion: The results suggest that performing full deformity correction with transpedicular fixation up to the higher-thoracic region gives the best outcomes for elderly patients, and helps to prevent long-term complications. ***Evidence level III; Retrospective Comparative Study.***

Keywords: Scoliosis; Osteotomy; Patient health questionnaire.

RESUMO

Objetivo: Avaliar os resultados da operação em idosos com deformações degenerativas e instabilidade da coluna vertebral. Método: Estudo retrospectivo de 437 pacientes (337 mulheres, 100 homens) com idade média de 60 anos. A duração média da observação foi de cinco anos. Os critérios de inclusão foram doenças e complicações após uma deformidade, processos degenerativos, síndrome da dor aguda e estenose espinhal com déficit neurológico. Quatro grupos de estudo (A, B, C e D) foram criados por tipo de intervenção cirúrgica. Grupo A (grupo de referência): descompressão das estruturas neuronais de ambos os lados sem fixação. Grupo B: descompressão e fixação transpedicular realizadas sem correção. Os pacientes do grupo C foram submetidos à cirurgia para região torácica inferior com parafusos transpediculares, correção e descompressão. Grupo D com fixação transpedicular na região torácica alta; correção total; descompressão de estruturas neurológicas. A duração média da observação foi de cinco anos. Resultados: no grupo D, melhores resultados foram observados. Bons resultados em 57,2% dos casos (60 pacientes); satisfatório em 40% dos casos (42 pacientes); e insatisfatório em 2,8% (3 pacientes). Os piores resultados foram obtidos no Grupo A. Resultados satisfatórios em 13,4% dos casos (15 pacientes); e insatisfatório em 86,6% dos casos (97 pacientes). Conclusão: Os resultados sugerem que a realização de uma correção completa da deformidade com fixação transpedicular na região torácica alta leva a melhores desfechos para pacientes idosos e ajuda a evitar complicações em longo prazo. ***Nível de evidência III; Estudo Retrospecitvo Comparativo.***

Descritores: *Escoliosis; Osteotomía; Questionário de saúde do paciente.*

RESUMEN

Objetivo: Evaluar los resultados quirúrgicos en pacientes ancianos con deformaciones degenerativas e inestabilidad de la columna vertebral. Métodos: Estudio retrospectivo de 437 pacientes (337 mujeres, 100 hombres) con edad promedio de 60 años. La duración media de la observación fue de 5 años. Los criterios para la inclusión fueron enfermedades y complicaciones posteriores a traumatismo espinal asociado con deformidades, procesos degenerativos, síndrome de dolor agudo y estenosis espinal con déficit neurológico. Se crearon cuatro grupos de estudio (A, B, C y D) por tipo de intervención quirúrgica. Grupo A (el grupo de referencia): descompresión de las estructuras neuronales en ambos lados sin fijación. Grupo B: descompresión y fijación transpedicular realizadas sin corrección de la deformidad. Los pacientes del grupo C habían sido operados hasta la región torácica inferior con tornillos transpediculares, corrección de la deformidad y descompresión de la estenosis espinal. Grupo D con fijación transpedicular hasta la región torácica superior, corrección de la deformidad y descompresión de estructuras neurológicas. La duración media de la observación fue cinco años. Resultados: En grupo D se observaron mejores resultados. Los resultados observados fueron buenos en 57,2% de los casos (60 pacientes); satisfactorios en 40% de los casos (42 pacientes) e insatisfactorios en 2,8% (tres pacientes). Los peores resultados se obtuvieron en el Grupo A. Resultados satisfactorios en 13,4% de los casos (15 pacientes) e insatisfactorios en 86,6% de los casos (97 pacientes). No se observaron buenos resultados en este grupo. Conclusión: Los resultados sugieren que realizar una corrección de deformidad completa con fijación transpedicular hasta zona torácica superior lleva a mejores resultados para pacientes de edad avanzada y ayuda a evitar complicaciones a largo plazo. ***Nivel de evidencia III; Estudio Retrospectivo Comparativo.***

Descriptores: *Escoliosis; Osteotomía; Cuestionário de salud del paciente.*

Study conducted at the Russian Research Institute of Traumatology and Orthopedics, Saint Petersburg, Russia.
Correspondence: Anton Denisov, Spine Surgery and Oncology Service, R. R.Vreden Russian Research Institute of Traumatology and Orthopedics. Saint Petersburg, st. A.Baykova, 8, Russia, 195427. +7 812 670 95 52. dr.denisovspine@icloud.com

CC BY

http://dx.doi.org/10.1590/S1808-185120181703193268

Coluna/*Columna.* 2018;17(3):216-20

Received on 03/21/2018, accepted on 07/25/2018

INTRODUCTION

Treating degenerative spinal deformities accompanied by segment instability in elderly patients is problematic, and improved approaches are needed. The deformity is prevalent, affecting up to 60% of senior aged people. In the USA, around 3.3 billion dollars per annum is spent on treating spinal deformities in patients aged 60 years or older.[1–3]

Recently, surgical treatment for severe lesions has become more common. Degenerative spinal deformities are present in segment instability and secondary spinal stenosis.[1,3–6] New surgical techniques and modern anesthetic procedures are enabling patients of any age to be operated on, even if they present severe somatic pathology.[3,6–8]

A crucial link in further medical tactics for senior age patients with spinal column deformities is the pathological changes that occur in the bone-ligament formations and spinal cord. Resolving skeletal and neurological problems simultaneously requires a combined neuro-orthopedic approach; hence, surgical treatment should be combined with stabilizing and decompressing interferences.[4,9]

Where old age is combined with severe somatic pathology, the extensiveness of surgical intervention should still preserve opportunities for self-reliance and social activity.[5,6,8,10,11]

Though understanding of treatment volume is quite clearly defined in general terms, this not the case for elderly patients.[5–7,12]

It is clear from the current literature that further research is needed on the subject of treating elderly patients with deformities, spinal stenosis, and segment instability. It is necessary to specify the indications, extent, and priority of operational treatment for this patient category, and to improve the forms of surgical treatment.

Aim of the study

To compare surgical treatment results among elderly patients with degenerative deformities and instability of the spine.

METHODS

Ethical approval. The study was approved by the research ethics committee.

Patient consent. All patients gave their informed consent prior to being included into the study.

Retrospective study of 437 patients (337 women, 100 men) with a mean age 60, operated at the Russian Orthopaedic Institute of Traumatology and Orthopaedics – Vreden R.R. The follow-up period was 5 years (operated from 2002 to 2012).

Inclusion criteria

1. 60 years or older
2. presence of spinal deformity with Cobb angle of more than 30°
3. multiple spinal stenosis
4. Neurological deficit (Paresthesia of the lower limbs 3.5 points) and intensive acute pain syndrome (VAS score 7 and above)
5. Prior decompression of neural structures, with or without correction of the deformity.

The mean age of the patients was 68 years (range from 60 to 88 years). The majority of the patients (337 or 77%) were women, and 100 (23%) were male.

Etiologically, all the patients were separated into 3 groups: (1) 137 had vertebral column instability and neurological deficit due to degenerative process after idiopathic and kyphotic deformity; (2) 170 patients had degenerative scoliosis, and (3) 130 had posttraumatic deformities (more than 6 months after the incidence) plus the presence of degeneration.

Four groups were created for analysis, based on the type of surgical intervention performed.

Group A comprised patients with prior decompression of neural structures on both sides without fixation (reference group).

Group B comprised patients who underwent decompression and transpedicular fixation performed for spinal segments without correction of the deformity.

Patients of Group C underwent surgery up to the lower-thoracic region with transpedicular screws, correction of the deformity, and decompression of spinal stenosis.

Group D patients underwent transpedicular fixation up to higher-thoracic region, correction of the deformity, and decompression of neurological structures.

The duration of observation was 5 years.

All patients had passed a total complex preoperative test, including radiological and clinical methods. Additionally, information was obtained on mineral bone density by the DEXA method.

Spinal deformity criteria were evaluated using the Schwab-SRS Adult Spinal Deformity classification.[10] A summary of the types of deformity is shown in Table 1.

Nearest, mid-term, and long-term treatment results were evaluated using the VAS scale, Oswestry Disability Index, and SRS-24. The degree of neurological breaches was determined by neurological examination. The influence of intermittent lameness was reflected in quality-of-life questionnaires. A summary of the results of the four groups is shown in Table 2.

Statistical data processing

Dispersion analysis – ANOVA (Tukey HSD test) was performed using the software program Statistica 10. Confidence intervals were calculated by the improved Wald test, and normality of distribution was verified by the Shapiro-Wilk test.

A detailed study of the patients' data revealed that all the results were comparable (in terms of level of the pain, degree and significance of the deformity, and quality of life), which enabled us to conduct a comparative analysis and to consider all distinctions in the postoperative period related to the surgical treatment.

Table 1. Summary of deformity types using the Schwab-SRS Adult Spinal Deformity classification.

Type of deformity	Modifier		Number of patients (% from the sample) (boundaries of confidence interval Wald)	
	PI-LL	PT	Global Balance	
L	A (<10°)	L (<20°)	N (SVA<4 cm)	35 (8%) (0.0579-0.109 6)
	B (10° -20°)	M (20-30°)	P(SVA4-9.5 cm)	56 (12.7%) (0.0999-0.1629)
	C (>20°)	H (>30°)	PV(SVA>9.5 cm)	61 (14%) (0.1101-0.1754)
D	A (<10°)	L (<20°)	N (SVA<4 cm)	72 (16.5%) (0.1328-0,2026)
	B (10°-20°)	M (20-30°)	P(SVA4-9.5 cm)	86 (19.7%) (0.1621-0,2367)
	C (>20°)	H (>30°)	PV(SVA>9.5 cm)	61 (14%) (0.1101-0.1754)
S	B (10° -20°)	M (20-30°)	P(SVA4-9.5 cm)	38 (38(8.7%) (0.0638-0.1173)
		H (>30°)	PV(SVA>9.5 cm)	28 (28(6.4%) (0.0393-0.1019)

Table 2. Summary table of patient parameters.

Parameters before surgery	Groups				p
	A	B	C	D	
age	69 (62-78)	70 (60-80)	72 (63-81)	72 (62-82)	0.17
men	23	27	24	26	0.21
women	89	86	83	79	0.35
VAS mean value (SD)	8 (±2.2)	8 (±2.4)	8 (±1.9)	8 (±2.3)	0.24
ODI mean value % (SD)	77.4 (±4.1)	78.5 (±3.8)	78.1 (±4.2)	77.3 (±3.2)	0.19
SRS-24 mean value (SD)	1.9 (±0.6)	1.9 (±0.5)	1.9 (±0.4)	1.9 (±0.8)	0.38
paresis	-	-	-	-	
PI-LL (SD)	22.4° (±3.7)	23.3° (±3.6)	23° (±4.2)	22.7° (±3.9)	0.27
PT (SD)	34.3° (±4.3)	33.5° (±2.9)	35.5° (±3.1)	34.2 ° (±4.2)	0.176
LL (SD)	12.3° (±2.1)	13.1° (±1.9)	12.7° (±2.8)	12.9° (±2.5)	0.13
TK (SD)	44.7° (±4.7)	45.2° (±5.1)	44.3° (±5.3)	45.1° (±4.4)	0.22
SVA (SD)	7.3 cm(±2.2)	7.9 cm (±2.4)	8.1 cm (±1.9)	7.5 cm (±1.7)	0.178
CSA (SD)	4.5 cm (±1.3)	3.9 cm (±1.7)	4.4 cm (±1.4)	4.2 cm (±1.5)	0.183
Cobb (SD)	38.3° (±4.8)	38.1° (±5.2)	37.7° (±4.5)	38.4° (±5.3)	0.16

Surgical interventions

The patients of Group A underwent decompression of the spinal canal by foraminotomy via the tubular approach (one-two segments) or the central posterior approach (more than two segments).

The patients of Group B underwent fixation by transpedicular screws to stabilize the vertebral column without correction of the deformity, and neural decompression of the involved segments. (Figure 1)

The patients of Group C underwent fixation up to lower-thoracic region with correction and decompression. Monoaxial and uniplanar screws were added to correct the vertebral rotation. (Figure 2)

The patients of Group D underwent fixation up to higher-thoracic region with correction and decompression of spinal stenosis.

RESULTS

X-ray control was carried out at 3, 6, 12, and 18 months during the first 18 months of postoperative follow-up, and once in a year after the initial follow-up period.

The results were evaluated intra-group and inter-group, and compared with the primary data. The clinical control was carried out at 3, 6 12, and 18 months in the first year, and at two and five years after surgery.

The results showed different levels of pain in each of the patient groups. (Figure 3)

The early postoperative result in Group A was an even decrease in the level of pain, which can be explained by the type of surgical intervention performed. Similar results were found in Group B and were correlated with the less aggressive surgery. In Groups C and D, there was no statistically significant difference between the preoperative and postoperative pain levels. During the early follow-up period, the pain level tended to decrease unevenly in all the groups.

In Group A, the level of pain increased. This can be explained by the increasing instability of the spinal column confirmed in the functional X-ray films. In Groups B and C, significant positive dynamics were observed, which can be attributed to the adaptation to new conditions of balance, the healing process in the area of surgical approach, and the formation of a primary bone block.

During the second follow-up period, the patients of Groups A, B and C demonstrated negative dynamics with increased pain. The occurrence of the first complications was observed in this period.

The level of the pain increased, to the detriment of a continued increase in instability in the functional spinal unit (Group A) and problems with adjacent levels (Groups B, C, and D). At the same time, the patients of Group D had less complications and less increase of pain.

At the end of 5 years of follow-up, pain had reached practically preoperative levels in Group A, decreased considerably in Groups B and C and decreased maximally in Group D. Meanwhile, the data for Groups B and C were comparable. (Figure 4) Comparing the changes using the Oswestry Disability Index (ODI), we obtained the data given below. (Figure 5)

In Group A, the significant postoperative improvement was replaced by gradual steady return to initial levels. There were also changes in the Oswestry Disability Index (ODI) and evaluation of patient satisfaction with the treatment (SRS-24). (Figures 4 and 5) These results are related to increasing of spinal instability and increasing pain.

In Groups B, C, and D, the ODI ratings and SRS-24 demonstrated

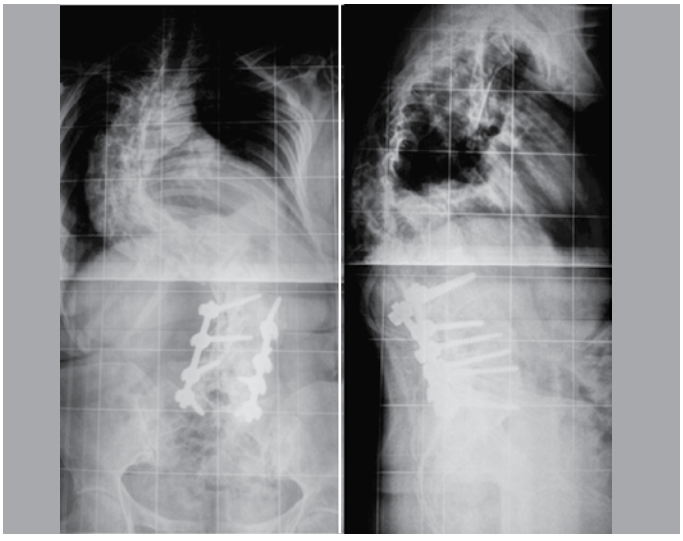

Figure 1. X-ray of patient 63 years, with the consequences of idiopathic scoliosis 5 years after surgical treatment. Transpedicular fixation without correction of the deformity.

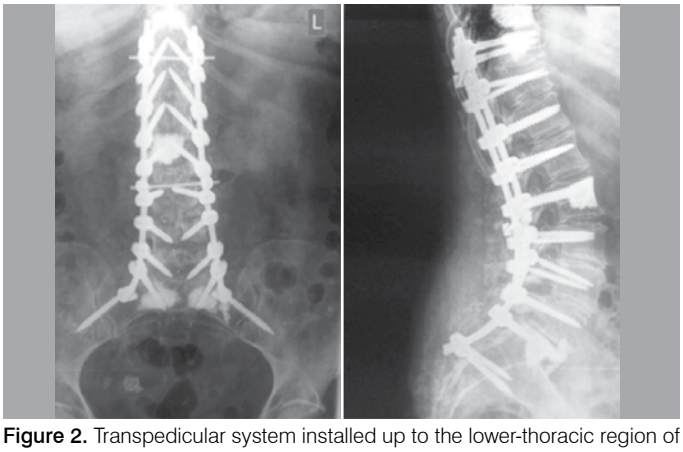

Figure 2. Transpedicular system installed up to the lower-thoracic region of the spine with cement augmentation.

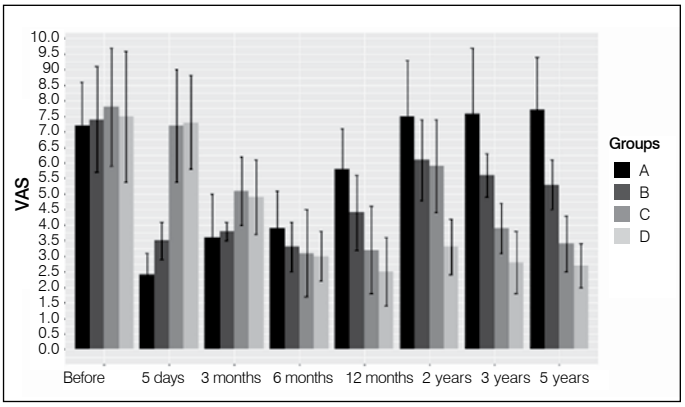

Figure 3. Pain level changing on VAS scale during 5 years, where 10 = maximum pain, and 0 = absence of pain. The table is based on the ratings of mean values with confidence intervals for each group.

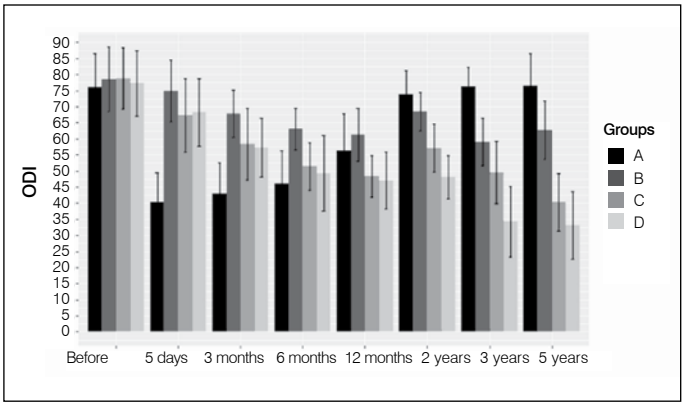

Figure 4. Changes of life quality (ODI) for 5 years for four groups, where 100 = maximally poor quality of the life, and 0 = maximally good quality of life. The table is based on the ratings of means with direction of confidence intervals for each group in measured periods of the time.

a smooth tendency to improvement, related to complications, which increased during this period. (Figures 4 and 5)

In Groups A and B, no neurological infringements were observed in the postoperative period, but neurogenic lameness increased during the entire follow-up period. In Groups C and D, unilateral monoparesis of two to four degrees was observed in 18% (Group C) and 15% (Group D), which can be explained by the nerve traction during the correction of spine deformity.

In total, at the end of five years of supervision, the lowest result was found in Group A, with 13.4% satisfactory results (15 patients) and 86.6% unsatisfactory results (97 patients). No good results were observed.

For the patients in Group B, good results were obtained in 19.5% (22 patients), satisfactory in 50.5% (57 patients) and unsatisfactory in 30% (34 patients).

For Group C, there were 24.3% good results (26 patients), 45.7% satisfactory (49 patients), and 30% unsatisfactory (32 patients). (Figure 5)

The best outcome was obtained in Group D, with 57.2% good results (60 patients), 40% satisfactory results (42 patients), and 2.8% unsatisfactory (3 patients). (Figure 6) These data confirm the statistical validity of the distinctions in relation to the surgical treatment results.

Comparative results of the clinical research are shown in Table 3 and Figure 7.

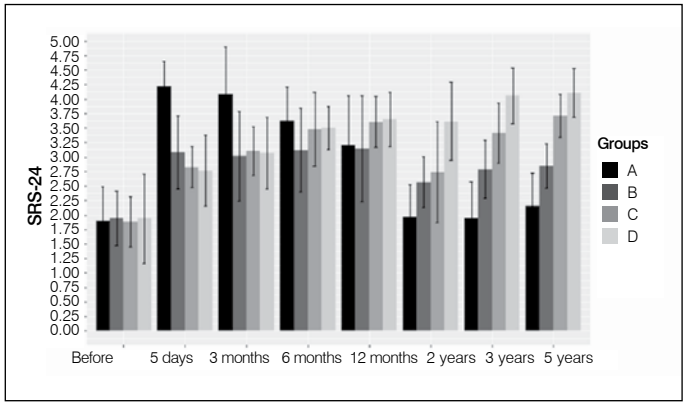

Figure 5. Changes of quality of life and satisfaction by results of surgical treatment on SRS-24 for 5 years in four groups, where 5 = maximally good result, and 1 = maximally poor result. The table is based on the ratings of means with direction of confidence intervals for each group in measured periods of the time.

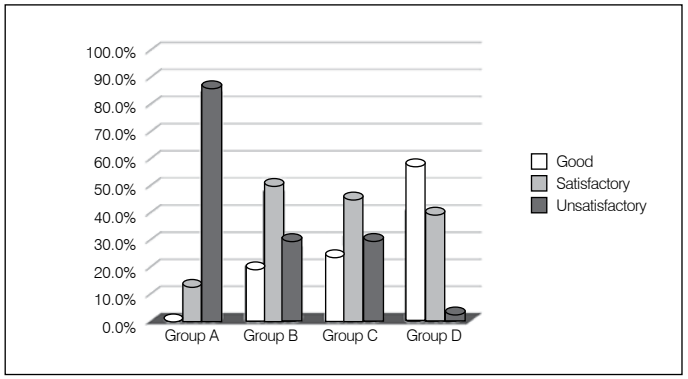

Figure 6. Results of the treatment in all groups 5 years postoperative. The value of χ^2 is 205.801. Critical value χ^2 is 16.812 (at value $p < 0.01$).

Surgical complications

The following complications were observed: increasing neurological deficit, with acute pain syndrome, instability and (or) construction fracture, adjacent segment disease with instability and (or) vertebral fractures of the adjacent level.

In total, revision surgeries due to complications were carried out in 29% (127 cases) at 113 patients (25.8%). Of these, 8.7% (38 operations, 30% from all complications) involved reinstallation of the metal construction due to instability or breakage (24 subjects, 5.5% of the total). However, for Group A this complication was not typical. In Group B, there were 8 cases (21% of the total with this type of complication), in Group C there were 26 cases (68.4%) and in Group D there were 4 cases (10.6%) (Figure 7). Operations due to neurologic infringements were performed in 13.3% cases (58 operations, 45.6% of all complications). In Group A, there were 28 cases (48.3%), in Group B, 13 cases (22.4%), in Group C, 15 cases (25.9%) and in Group D, 2 cases (3.4%). Pathology of adjacent segment was revealed in 7% (31 cases, 24.4% of all complications). In Group A, no complications were observed. In Group B there were 12 cases (38.8%), in Group C, 18 cases (58%) and in Group D only one case (3.2%) (Figure 8).

DISCUSSION

Vakkaro and Sharik suggest that decompression can result in greater collapse of the functional spinal unit, instability, and exacerbation of the lumbar deformity, resulting in increasing pain, to the detriment of strengthened spinal stenosis. This authors ascribe to the tactics of executing decompression and fixation with correction of the deformity.[13]

Our research was performed to determine the efficiency of various surgical methods in elderly persons with deformities of the spinal column. The patients were divided into four groups, depending on the extent of surgical intervention performed.

It was noted that patients of Group A withstood the operation better than others in the nearest follow-up period, but in the later follow-up period, the results for this group were unsatisfactory.

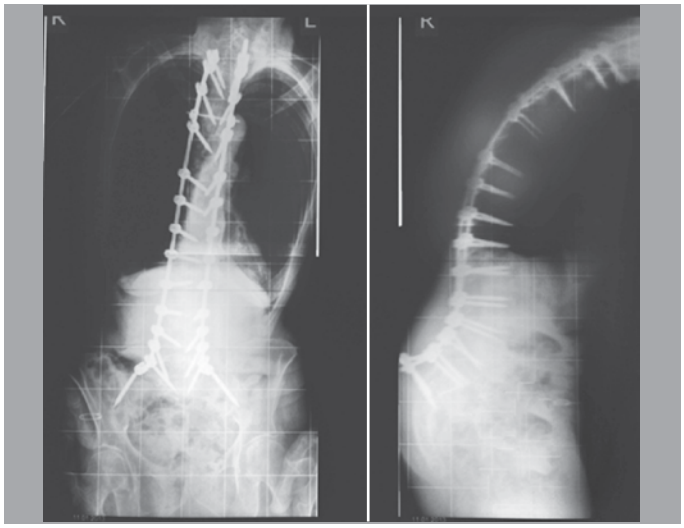

Figure 7. X-ray film of female 74 years, in first year postoperative, AP and lateral views. Loss of correction with construction instability. Positive sagittal balance SVA+68 cm, frontal imbalance 12 cm, lordosis angle LL=32º.

Table 3. Master table of treatment results in 5 years.

Groups	Preoperative				5 years postoperative			
	VAS (SD)	ODI (SD)	SRS-24 (SD)	Paresis% SD)	VAS (SD)	ODI (SD)	SRS-24 (SD)	paresis (SD)
A	8 (±2.2)	77.4 (±4.1)	1.9 (±0.6)	-	8 (±2.4)	76.5 (±2.1)	2.2 (±0.6)	-
B	8 (±2.4)	78.5 (±3.8)	1.9 (±0.5)	-	4 (±1.2)	53.7 (±5.8)	2.9 (±0.3)	-
C	8 (±1.9)	78.1 (±4.2)	1.9 (±0.4)	-	4.0 (±0.7)	45.3 (±4.7)	3.7 (±0.4)	6 (±0.7)
D	8 (±2.3)	77.3 (±3.2)	1.9 (±0.8)	-	3.0 (±1.5)	37.1 (±3.4)	4.1 (±0.4)	3 (±0.5)
P value	0.24	0.19	0.38	-	0.036	0.012	0.025	0.0027

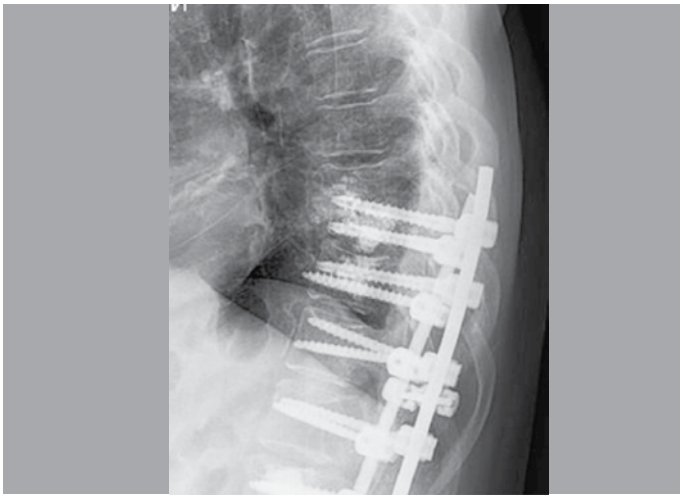

Figure 8. X-ray of a female aged 79 years, the first year postoperative. Fracture of the body Th8.

We observed the highest level of good clinical results for correction of deformity among the patients who underwent spinal osteotomies and multiply level fixation (55.5% of all good results), which corroborates the studies of Vakkaro and Sharik. For patients who received only decompression of the spinal stenosis, satisfactory results were observed only during the first month of follow-up. Furthermore, instability increasing, pain, and neurogenic lameness was observed (in 97 patients, 58.4%).

The results contradict the claim of Vakkaro and Sharik concerning the opportunity to use only local decompression in patients with degenerative deformities.[8]

At the same time, the amount of surgical and somatic complications in all groups was comparable, and we can establish that there is no direct correlation with the extent of surgery or the frequency of the above-stated complications.[2,14]

This result contradicts the belief that more aggressive surgery increases the risk of complications.[10,15,16]

Specific complications associated with applying various implants or levels selection for fixation were revealed in Groups B and C (21% and 68.4% respectively), where correction of the deformity was either not performed (Group B), or was performed with "short fixation", that didn't allow spinal balance be adjusted.

The same tendency was noted for problems with the adjacent segment. In Group B, there were 12 such cases (38.8%), with 18 cases in Group C (58%) and one case in Group D (3.2%). This also confirms the results of Vakkaro and Sharik.

Based on our results, we recommend decompressive foraminotomy if there is restabilization of the compromised spinal unit and absence of development of the deformity. And against a background of compensated balance, is preferable to use only decompression foraminotomy. For proven instability, the method of choice should be decompression of the spinal channel, stabilization of the spine with transpedicular fixation, cement augmentation, and spinal osteotomy. At the same time, long fixation is better than short fixation due to the risk of adjacent segment disease. Our conclusions partly confirm the supporters and opponents of stabilization of spine column.[3,8,15,17]

CONCLUSIONS

Based on the data obtained, it can be seen, that the majority of complications were associated with neurological problems (included acute pain syndrome, paresis and paresthesia due to nerve traction, ischemia or injury). More complications were found in Group C than in Group D.

This analysis showed that incomplete correction of the deformity could lead to its loss, vertebral or construction fractures, and screw migration. Correction of sagittal balance (SVA$<$4 cm) or pelvic indices using the formula PI+TK+LL$\leq 45^0$ or only frontal balance is insufficient, as it can lead to loss of correction, and complications.

The risk of adjacent segment pathology among patients of elderly and senile age is "short" fixation (Th10 or L1) with pelvic ring.

In patients of this age, there is no compensation of the remaining deformity in the thoracic region, compared with younger adults. Therefore, for elderly patients, transpedicular fixation could be recommended, extended up to Th4. The conclusions are based on an analysis of X-ray films taken from of Groups B, C and D.

According to the findings of our study, we recommend performing full deformity correction with transpedicular fixation as far as the higher-thoracic region in elderly patients. This approach enables the best results, while avoiding complications in long-term outcomes.

All authors declare no potential conflict of interest related to this article.

CONTRIBUTION OF THE AUTHORS: AD (0000-0001-8113-2395)* and DM (0000-0002-4747-0806)* - review and approval of the final version of the work. DP (0000-0001-5765-3158)*, NZ (0000-0003-4562-8160)* and SM (0000-0002-9853-7089)* - active participation in the discussion of results. *ORCID (Open Researcher and Contributor ID).

REFERENCES

1. Albert TJ, Purtil J, Mesa J, McIntosh T, Balderston RA. Health outcome assessment before and after adult deformity surgery: A prospective study. Spine (Phila Pa 1976). 1995;20(18):2002-2005.
2. **Fischer CR, Terran J, Lonner B, McHugh B, Warren D, Glassman S, et al. Factors predicting cost-effectiveness of adult spinal deformity surgery at 2 years. Spine Deform. 2014;2(5):415-422.**
3. DeWald CJ, Stanley T. Instrumentation-related complications of multilevel fusions for adult spinal deformity patients over age 65: Surgical considerations and treatment options in patients with poor bone quality. Spine (Phila Pa 1976). 2006;31(19 SUPPL.)S144-51.
4. Silva FE, Lenke LG. Adult degenerative scoliosis: evaluation and management. Neurosurg Focus. 2010;28(3):E1.
5. Transfeldt EE, Topp R, Mehbod AA, Winter RB. Surgical outcomes of decompression, decompression with limited fusion, and decompression with full curve fusion for degenerative scoliosis with radiculopathy. Spine (Phila Pa 1976). 2010;35(20):1872-5.
6. **Seo HJ, Kim HJ, Ro YJ, Yang HS. Non-neurologic complications following surgery for scoliosis. Korean J Anesthesiol. 2013;64(1):40-46.**
7. Smith JS, Kasliwal MK, Crawford A, Shaffrey CI. Outcomes, Expectations, and Complications Overview for the Surgical Treatment of Adult and Pediatric Spinal Deformity. Spine Deform. 2012.
8. **Glassman SD, Dimar JR, Carreon LY. Revision rate after adult deformity surgery. Spine Deform. 2015;3(2):199-203.**
9. Ploumis A, Transfledt EE, Denis F. Degenerative lumbar scoliosis associated with spinal stenosis. Spine J. 2007;7(4):428-36.
10. **Weber MH, Mathew JE, Takemoto SK, Na LH, Berven S, Spinal Seformity Study Group. Postoperative recovery outcomes in adult scoliosis: A prospective multicenter database with 5-year follow-up. Spine Deform. 2014;2(3):226-32.**
11. Yadla S, Maltenfort MG, Ratliff JK, Harrop JS. Adult scoliosis surgery outcomes: a systematic review. Neurosurg Focus. 2010;28(3):E3.
12. Schwab F, Ungar B, Blondel B, Buchowski J, Coe J. Scoliosis Research Society—Schwab Adult Spinal Deformity Classification: a validation study. Spine (Phila Pa 1976). 2012;37(12):1077-82.
13. **Dangelmajer S, Zadnik PL, Rodriguez ST, Gokaslan ZL, Sciubba DM. Minimally invasive spine surgery for adult degenerative lumbar scoliosis. Neurosurg Focus. 2014;36(5):E7.**
14. Cho KJ, Suk SI, Park SR, Kim JH, Kim SS, Choi WK, et al. Complications in posterior fusion and instrumentation for degenerative lumbar scoliosis. Spine (Phila Pa 1976). 2007;32(20):2232-7.
15. Carreon LY, Puno RM, Dimar JR 2nd, Glassman SD, Johnson JR. Perioperative Complications of Posterior Lumbar Decompression and Arthrodesis in Older Adults. J Bone Joint Surg Am. 2003;85(11):2089-92.
16. Raffo CS, Lauerman WC. Predicting morbidity and mortality of lumbar spine arthrodesis in patients in their ninth decade. Spine (Phila Pa 1976). 2006;31(1):99-103.
17. **Park JJ, Carreon LY, Glassman SD. Adult lumbar degenerative scoliosis 40° or less: Outcomes of surgical treatment with minimum 2-year follow-up. Spine Deform. 2013;1(3):211-216.**

RELATIONSHIP BETWEEN PARAMETERS OF THE LUMBAR FACET JOINTS IN A LONG-TERM POSTOPERATIVE OUTCOME

RELAÇÃO ENTRE PARÂMETROS DAS LIGAÇÕES DA FACETA LOMBAR EM UM RESULTADO PÓS-OPERATÓRIO DE LONGO PRAZO

RELACIÓN ENTRE PARÁMETROS DE LAS ARTICULACIONES FACETARIAS LUMBARES EN RESULTADO POSTOPERATORIO A LARGO PLAZO

Vadim Anatol'evich Byvaltsev[1,2,3,4], Andrei Andreevich Kalinin[1,2], Alyona Konstantinovna Okoneshnikova[1,2], Yuri Yakovlevich Pestryakov[1], Igor Vadimovich Basankin[5]

1. Irkutsk State Medical University, Irkutsk, Russia.
2. Railway Clinical Hospital, Irkutsk, Russia.
3. Irkutsk Research Center Surgery and Traumatology, Irkutsk, Russia.
4. Irkutsk state medical academy of postgraduate education, Irkutsk, Russia.
5. Research Institute Krasnodar Regional Hospital 1, Krasnodar, Russia.

ABSTRACT

Objective: To analyze the impact of the relationship between tropism and angulation of the lower lumbar facet joints on a remote clinical outcome after dynamic and rigid surgical interventions. Methods: Patients with degenerative diseases of the lower lumbar spine were subdivided into three groups, according to the method of surgical treatment: 1) (n=48) the use of an artificial prosthesis intervertebral disc (IVD); 2) (n=42) the use of interbody fusion combined with transpedicular and transfacet stabilization; 3) (n=51) the use of interbody fusion and bilateral transpedicular stabilization. Analysis was performed of the remote clinical parameters and neuroimaging characteristics before the operation was performed. Results: When analyzing clinical and instrumental parameters, a significant correlation was found between the long-term outcomes of surgical treatment on the VAS and Oswestry scales and the neuroimaging data on angulation and tropism of the facet joints (FJ). Conclusions: The data obtained testify to the importance of preoperative diagnosis of tropism and angulation of the lower lumbar facet joint, which enables differentiated surgical tactics to be selected, and remote clinical outcomes to be optimized. In the presence of neuroimaging parameters of Facet Joint angulation of less than 60^0, regardless of the presence of tropism, it is possible to perform total arthroplasty of IVD. When neuroimaging parameters of Facet Joint angulation of more than 60^0 are detected, rigid stabilization of the operated segment is recommended, while in the absence of tropism of Facet Joints, a contralateral transfacetal fixation is possible; in the presence of tropism, it is expedient to perform bilateral transpedicular stabilization. ***Level of Evidence II; Prognostic Studies—Investigating the Effect of a Patient Characteristic on the Outcome of Disease.***

Keywords: Spine; Chronic disease; Zygapophyseal joint; Spinal fusion; Arthroplasty.

RESUMO

Objetivo: Analisar o impacto da relação entre tropismo e angulação das articulações lombares inferiores em um resultado clínico remoto, após intervenções cirúrgicas dinâmicas e rígidas. Métodos: Dependendo do método de tratamento cirúrgico, os pacientes com doenças degenerativas da coluna vertebral lombar inferior foram subdivididos em três grupos: 1) (n = 48) com a utilização de uma prótese de disco intervertebral artificial (IVD); 2) (n = 42) com utilização de fusão intercorporal, combinado com transpedicular e estabilização transfacetal; 3) (n = 51) com a utilização de fusão intercorporal e estabilização transpedicular bilateral. A análise dos parâmetros clínicos remotas e características de neuroimagem antes da operação foi realizada. Resultados: Quanto a análise de parâmetros clínicos e instrumentais, uma correlação significativa foi encontrada entre os resultados a longo prazo do tratamento cirúrgico com as escalas VAS e Oswestry com dados de neuroimagiologia sobre angulação e tropismo de articulações (FJ). Conclusão: Os dados obtidos atestam a importância do diagnóstico pré-operatório de tropismo e angulação da articulação faceta lombar inferior, que permite escolher táticas cirúrgicas diferenciadas e otimizar os resultados clínicos remotos. Na presença de parâmetros de neuroimagiologia de angulação de FJs menor do que 600, independentemente da presença de tropismo, é possível realizar a artroplastia total da IVD. Quando a detecção de parâmetros de neuroimagens FJ, angulação mais do que 600, a estabilização rígida do segmento operado é recomendado, enquanto que na ausência do tropismo de FJs, uma fixação transfacetal contralateral é possível; na presença de tropismo, é conveniente realizar a estabilização transpedicular bilateral. ***Nível de Evidência II; Estudos prognósticos – Investigação do efeito de característica de um paciente sobre o desfecho da doença.***

Descritores: *Coluna vertebral; Doença crônica; Articulação zigapofisária; Fusão Vertebral; Artroplastia.*

RESUMEN

Objetivo: Analizar el impacto de la relación entre el tropismo y la angulación de las articulaciones facetarias lumbares inferiores en un resultado clínico remoto después de intervenciones quirúrgicas dinámicas y rígidas. Métodos: Los pacientes con enfermedades degenerativas de la columna lumbar inferior se subdividieron en tres grupos de acuerdo con el método de tratamiento quirúrgico: 1) (n = 48) uso de una prótesis artificial de disco intervertebral (DIV); 2) (n = 42) uso de la fusión intersomática combinada con la estabilización transpedicular y transfacetaria; 3) (n = 51) fusión

Study conducted at the Irkutsk State Medical University, Irkutsk, Russia.
Correspondence: Irkutsk, PO, Russia. Box number 62. 664082. byval75vadim@yandex.ru

http://dx.doi.org/10.1590/S1808-185120181703193840

Received on 04/04/2018, accepted on 07/25/2018

intersomática y estabilización transpedicular bilateral. Se realizó el análisis de los parámetros clínicos remotos y las características de neuroimagen antes de que se realizara la operación. Resultados: Al analizar los parámetros clínicos e instrumentales, se encontró una correlación significativa entre los resultados a largo plazo del tratamiento quirúrgico en las escalas EVA y Oswestry con datos de neuroimagen sobre la angulación y el tropismo de las articulaciones facetarias (AF). Conclusiones: Los datos obtenidos confirman la importancia del diagnóstico preoperatorio de tropismo y la angulación de la articulación facetaria lumbar inferior, lo que permite elegir tácticas quirúrgicas diferenciadas y optimizar los resultados clínicos remotos. En presencia de parámetros de neuroimagen de angulación de AF inferior a 60º, independientemente de la presencia de tropismo, es posible realizar una artroplastia total de DIV. Al detectar los parámetros de neuroimagen de la angulación de la articulación facetaria de más de 60º, se recomienda la estabilización rígida del segmento operado, mientras que en ausencia de tropismo de las articulaciones facetarias es posible una fijación transfacetaria contralateral; en presencia de tropismo, es conveniente realizar una estabilización transpedicular bilateral. ***Nivel de evidencia II; Estudios pronósticos - Investigación del efecto de una característica del paciente sobre el desenlace de la enfermedad.***

Descriptores: *Columna vertebral; Enfermedad crónica; Articulación Cigapofisaria; Fusión vertebral; Artroplastia.*

INTRODUCTION

Rigid stabilization is currently the gold standard for the treatment of most degenerative diseases of the lumbar spine.[1-3] However, there are still a significant number of unsatisfactory clinical postoperative results associated with the progression of the degenerative process in the operated and adjacent segments due to biomechanical disorders.[2-4]

It has been proven that degeneration of the adjacent level occurs as a result of increased load on the facet joints and intervertebral discs, which is associated with the development of pathological mobility of the vertebral-motor segment (VMS) above the level of the rigid stabilization.[1,2]

Potential predisposing factors contributing to accelerated degeneration of the adjacent level are: degenerative changes in the joints of FJs, the type and extent of fusion, changes in the configuration of the spinal column in the sagittal plane, and previous surgical manipulations in the adjacent segment.[1,4]

Brailsford JF in 1928 first used the term "FJ tropism" to denote an asymmetry between the right and left FJs, or the presence of a more sagittal orientation of one of the FJs.[5] Masharawi et al. demonstrated that tropism of the FJs in the thoracic spine is one of the norm variants.[6] The presence of tropism of FJs in the lumbosacral spine is the cause of degenerative diseases.[7-9]

To select the right tactics for surgical treatment of patients with degenerative diseases of FJs, it is necessary to determine and justify the optimal amount of surgical intervention in the preoperative stage, taking into account individual degenerative changes of the FJs, the orientation of the joint surfaces and their angulation, the presence or absence of tropism for improvement of long-term postoperative clinical outcomes, minimization of postoperative instability, and the restoration of normal biomechanics for prevention of the progression of degenerate changes in lumbar segments.[2,10,11]

The specific aim of this study was to search for therapeutic and diagnostic approaches to optimize the outcomes of surgical treatment of patients with degenerative diseases of the lower lumbar spine, based on the analysis of the clinical and morphological parameters of the VMS.

The overall aim of this study was to analyze the impact of the relationship between tropism and angulation of the lower lumbar facet joints on a remote clinical outcome after dynamic and rigid surgical interventions, to determine the optimal surgical tactics.

METHODS

The study was approved by the ethics committee of the Irkutsk State Medical University; each of the patients included in the study gave written informed consent – protocol No. 2 by March 13, 2013.

A total of 151 patients who underwent in-patient treatment at the Center for Neurosurgery of the Railway Clinical Hospital at the Irkutsk-Passenger Railway station of the Russian Railways in the period 2013 to 2016. Three representative groups were singled out: in 48 cases, a discectomy was performed through extraperitoneal pararectal access with implantation of the M-6 disc prosthesis (Spinal Kinetics, USA) (I group); in 42 cases - interbody fusion was performed with the T-pal cage (Synthesys, Switzerland) using the TLIF method with the ipsilateral transpedicular stabilization by the Viper II system (Synthesys, Switzerland); contralateral fixation with the Facet Wedge implant (Synthesys, Switzerland). 1) (n=48) the use of an artificial prosthesis intervertebral disc (IVD); 2) (n=42) the use of interbody fusion combined with transpedicular and transfacet stabilization; 3) (n=51) the use of interbody fusion and bilateral transpedicular stabilization. Exclusion and exclusion criteria for the study were indications and contraindications for the implementation of interbody fusion to treat clinically significant pathological mobility of the vertebral-motor segments.

Inclusion criteria

Ineffective conservative therapy, prolonged or recurrent pain syndrome, persistent neurological deficit caused by the phenomena of radicular pain to sciatica with peripheral paresis;
Decrease in the height of the interbody spacing by more than 1/3 of the height of the overlying;
Absence of signs of segment instability (segmental angulation > 10º, linear translation > 4 mm);
A one-level symptomatic degenerative disease of the lower lumbar spine, according to neuroimaging data.

Contraindications

Central stenosis of the spinal canal;
Spondylolisthesis with or without spondylolysis;
Severe concomitant pathology;
Significant osteoporosis (decrease in BMD - by 2.8 or more according to the WHO T-criterion in 1995);
Need to correct the sagittal balance;
Need for a surgical correction of 2 or more segments of the lumbosacral spine.

Long-term clinical data were studied (the level of the pain syndrome according to the visual analogue scale (VAS) in the lumbar and lower limbs, the quality of life of the patients according to the questionnaire for patients with back pain Oswestry (ODI), satisfaction with the result of surgical treatment according to the Macnab scale,[3] and instrumental parameters determined by magnetic resonance imaging (MRI) of the lumbar spine (angulation and tropism of FJs) according to the method of Karacan et al.[12]. (Figure 1)

Calculation of the angles of FJ was performed on axial MRI--grams, using the software RadiAnt DICOM Viewer. Tropism of FJs was verified in the presence of the difference between the values of the angles of the right and left FJs of more than 10º. Values of the difference in angles between FJs at the level of surgical intervention were compared with those at the level of adjacent segments (i.e., for IVD of L_{III}-L_{IV}, the control level was L_{IV}-L_V, for L_{IV}-L_V – L_{III}-L_{IV} or L_V-S_I, and for IVD of L_V-S_I – L_{IV}-L_V).

After the surgery, the follow-up catamnesis was at least 24 and a maximum of 48 months, with a median of 36 months.

To assess the significance of differences in the sample populations, the criteria of nonparametric statistics were used, and $p < 0.05$ was taken as the lower limit for reliability. The data are represented by the median and interquartile range in the form of Me (25;75).

RESULTS

Analysis of gender characteristics of patients. General characteristics of the studied patients by sex, age, and constitutional characteristics are shown in Table 1.

It was found that the operated patients were predominantly male (more than 70%) and overweight (BMI > 25.0).

Analysis of remote clinical outcomes. Characteristics of distant parameters (after 24 months, on average) of patients in the study groups, in terms of the level of pain, quality of life and the degree of patient satisfaction with the surgery performed, are shown in Table 2.

Analyzing the long-term outcomes of surgical treatment (on average in 24 months) of the patients with degenerative diseases of the lower lumbar segments with the use of dynamic fixation (group I), interbody fusion with transpedicular and less rigid transfacetal stabilization (group II), and interbody fusion with rigid transpedicular stabilization (group III) , we obtained the minimum values for level of pain, on the visual analogue scale, good functional state, according to the ODI index, and predominantly good results on the Macnab scale of subjective satisfaction with surgical treatment outcome.

Analysis of clinical and morphological parameters of the affected vertebral-motor segments of patients, and their relationship with the outcome of surgical treatment.

The main clinical parameters that have a direct correlation with the clinical postoperative outcome and quality of life level are the degree of pain according to the VAS scale, and functional state according to the ODI index. Correlation analysis of the above clinical components and morphological characteristics - angulation and tropism of FJs according to the Karacan method was performed. Correlation dependence of the long-term outcome of surgical treatment according to VAS and ODI with the studied neuroimaging parameters is shown in Tables 3, 4.

In the analysis, it was found that the angulation index of FJs in group I was significantly correlated with the clinical parameters of VAS and ODI, the correlation dependence with the index of tropism

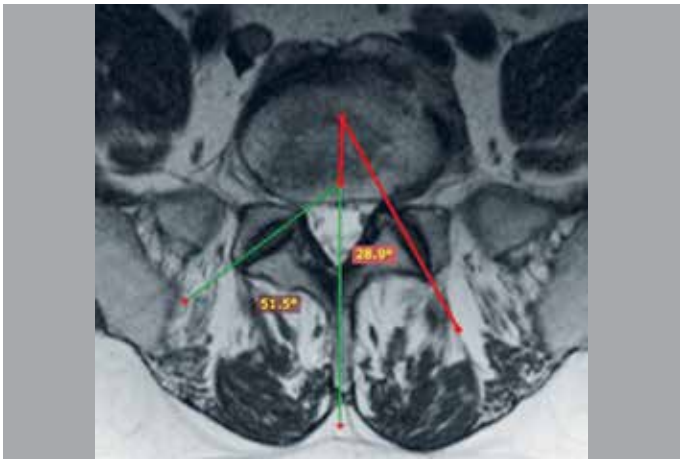

Figure 1. The procedure for calculating the angles of FJ by the method of Karacan et al. using the program RadiAnt DICOM Viewer: the angle of FJs is formed by the intersection of the lines drawn through the middle of the articular cleft of FJs and the line drawn through the center of the IVD and coinciding with the axis of the spinous process.

Table 1. The distribution of the patients by sex, age, and constitutional characteristics.

Criterion		Group I (n = 48)	Group II (n = 42)	Group III (n = 51)
age, yrs		37 (32;45)	39.5 (33;49)	40 (34;54)
Gender	Males, n, %	34 (71%)	31 (74%)	38 (75%)
	Females, n, %	14 (29%)	11 (26%)	13 (25%)
BMI, kg/m^2		25.6 (23.1;29.6)	26.1 (23.3;29.6)	26.5 (23.6;29.9)

Note: BMI - body weight index.

Table 2. Distribution of the studied patients for long-term results of surgical treatment.

Criterion		Group I (n = 48)	Group II (n = 42)	Group III (n = 51)
VAS, lumbar spine, mm		10.5 (6;14)	14 (9;24)	19 (10;29)
VAS, lower limbs, mm		8.5 (4;12)	14 (6;22)	15.5 (7;24)
ODI, score		10 (6;16)	16 (8;26)	16 (8;32)
Macnab	Excellent	25 (52%)	18 (43%)	11 (21%)
	Good	20 (42%)	15 (36%)	27 (53%)
	Satisfactory	3 (6%)	7 (16%)	9 (18%)
	Unsatisfactory	-	2 (5%)	4 (8%)

Note: VAS – Visual Analogue Scale for pain. ODI – Oswestry Disability Index. Macnab – scale of subjective evaluation of treatment outcome.

Table 3. Correlation of the FJ angulation index with remote clinical parameters by VAS and ODI and tropism index of FJ.

Criterion	Group I (n = 48)		Group II (n = 42)		Group III (n = 51)	
	R	p	R	p	R	p
VAS, lumbar spine 24 months	0.81	< 0.05	-0.91	< 0.05	-0.90	< 0.05
VAS, lower limbs, 24 months	0.79	< 0.05	-0.92	< 0.05	-0.89	< 0.05
ODI 24 months	0.90	< 0.05	-0.90	< 0.05	-0.85	< 0.05
FJ tropism	0.09	> 0.05	0.95	< 0.05	0.95	< 0.05

Note: R - the correlation index; p - confidence probability.

Table 4. Correlation of tropism index of FJ with remote clinical parameters according to VAS and ODI and FJ angulation index.

Criterion	Group I (n = 48)		Group II (n = 42)		Group III (n = 51)	
	R	p	R	p	R	p
VAS, lumbar spine 24 months	-0.44	> 0.05	-0.98	< 0.05	-0.99	< 0.05
VAS, lower limbs, 24 months	-0.45	> 0.05	-0.97	< 0.05	-0.97	< 0.05
ODI 24 months	-0.18	> 0.05	-0.97	< 0.05	-0.95	< 0.05
FJ angulation	0.04	> 0.05	0.95	< 0.05	0.95	< 0.05

Note: R - correlation index; p - confidence probability.

was absent; in group II and III, an inverse correlation was observed with all the parameters studied, except for the tropism of FJs, where a direct significant correlation was verified.

In the analysis, it was found that the index of tropism of FJs in group I did not significantly correlate with the studied parameters; in groups II and III, an inverse correlation was observed with all the clinical parameters studied, and a significant inverse correlation with tropism of FJs.

Thus, the value of FJ angulation and, in some cases, the significance of the tropism of FJs, determined by the MRI method, have a direct impact on long-term clinical outcomes, which, perhaps, makes it possible to determine the possible tactics of surgical treatment. Postoperative outcomes were categorized as follows: "good": a complete or near complete return to the former level of social and physical activity (before the onset of the disease or the last exacerbation) (possible limitation of major physical activity); "unsatisfactory": household and social activity is not fully restored, no effect from the surgery or deterioration of the state.

A comparison of the clinical and instrumental data of patients in the study groups is presented in Table 5.

Taking into account the degree of the impact of the investigated instrumental parameters on the remote clinical outcome for optimization of treatment tactics for patients with degenerative diseases of the lower lumbar spine, it was determined that:

In the group of patients operated according to the dynamic fixation method, minimum VAS and ODI scores and a smaller degree of degenerative changes in the adjacent segment were achieved with preoperative parameters of FJs: angulation < 60^0, regardless of the presence of tropism. (Figure 2)

In the group of patients operated by the method of rigid stabilization, minimum VAS and ODI scores and a smaller degree of

Table 5. Comparative analysis of clinical data depending on the postoperative outcome in patients of the study groups.

Criterion	Group I (n = 48)		p	Group II (n = 42)		p	Group III (n = 51)		p
	"good" outcomes (n = 41)	"unsatisfactory" outcomes (n = 7)		"good" outcomes (n = 36)	"unsatisfactory" outcomes (n = 6)		"good" outcomes (n = 43)	"unsatisfactory" outcomes (n = 8)	
ODI, 24 months score	6 (6;8)	16 (16;18)	<0.01	8 (6;8)	26 (20;28)	<0.01	8 (8;10)	32 (28;36)	<0.01
VAS, lumbar spine 24 months, mm	6 (5;8)	14 (14;16)	<0.01	9 (8;10)	24 (22;26)	<0.01	10 (10;12)	29 (27;30)	<0.01
VAS, lower limbs, 24 months, mm	4 (3;5)	16 (14;18)	<0.01	6 (5;7)	22 (21;23)	<0.01	7 (7;8)	24 (22;25)	<0.01
FJ angulation before surgery, degree	50 (44;59)	69 (62;74)	<0.01	70 (62;78)	52 (48;56)	<0.01	69 (61;82)	52 (49;56)	<0.01
FJ tropism before surgery	+/-	+/-	>0.05	+	+/-	<0.01	-	+/-	<0.01
General lordosis before surgery	31 (27;37)	30 (25;39)	>0.05	34 (27;36)	32 (24;37)	>0.05	30 (24;37)	31 (23;37)	>0.05
General lordosis after surgery	55 (46;62)	33 (31;37)	<0.01	53 (42;68)	37 (31;37)	<0.01	52 (44;67)	37 (35;39)	<0.01

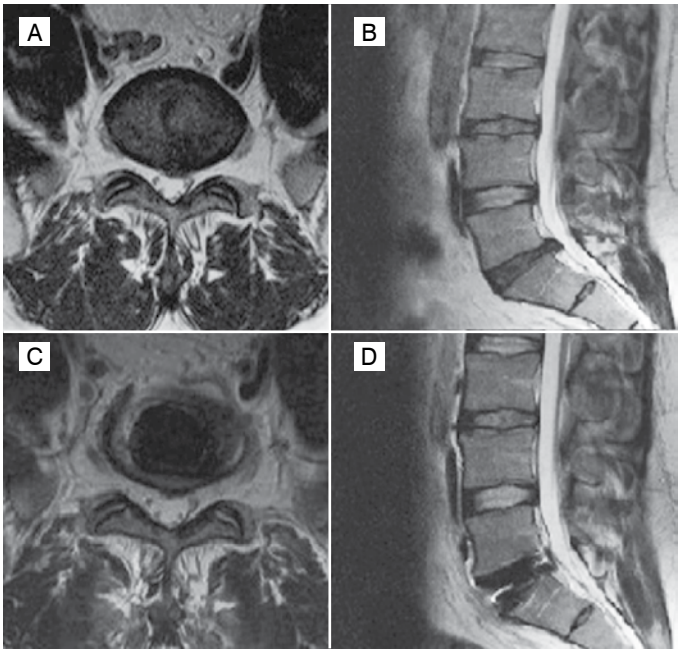

Figure 2. Patient A., 34 years old. MRI of the lumbosacral spine, T2 weighted images: A - axial projection: angulation of FJs - 58°, no tropism; B - sagittal projection (arrow indicates Hernia of IVD L_V-S_I); D - axial projection after surgery - total arthroplasty of L_V-S_I with artificial prosthesis IVD M6; C - sagittal projection after surgery. The level of pain in the lumbar spine according to VAS before surgery was 82 mm, in the left lower limb - 86 mm, ODI - 64 scores. The level of pain in the lumbar spine according to VAS in 24 months after the surgery was 6 mm, in the left lower limb VAS was 2 mm, ODI -8 scores.

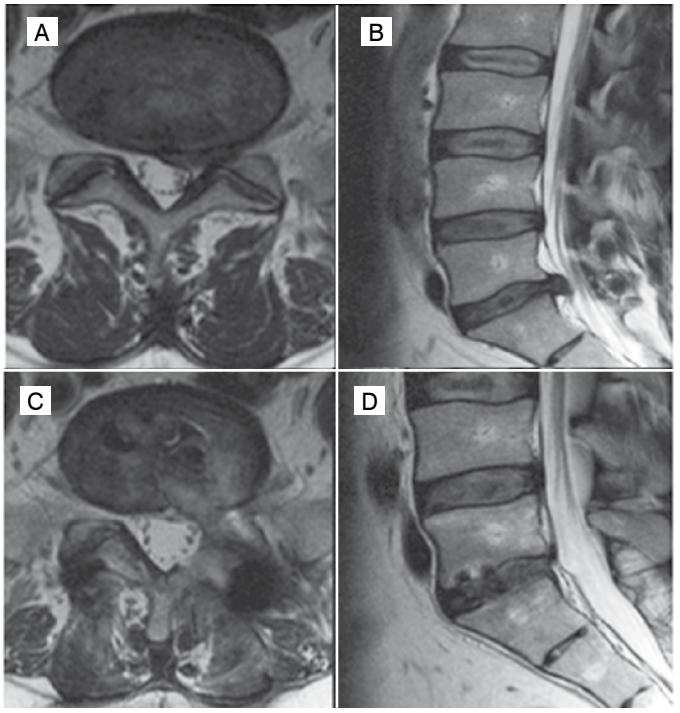

Figure 3. Patient G., 39 years old. MRI of the lumbosacral spine, T2 weighted images: A - axial projection: angulation of FJ - 63°, no tropism; B - sagittal projection (arrow indicates Hernia of IVD L_V-S_I); C - axial projection after surgery in the volume of microsurgical discectomy L_V-S_I, interbody fusion L_V-S_I., transpedicular fixation L_V-S_I by the system of cannulated screws on the left, contralateral transfacetal fixation by Facet Wedge system on the right; D - sagittal projection after surgery. The level of pain in the lumbar spine according to VAS before surgery was 77 mm, in the left lower limb - 81 mm, ODI - 62 scores. The level of pain in the lumbar spine according to VAS in 24 months after the surgery was 6 mm, in the left lower limb - 4 mm, ODI - 4 scores.

degenerative changes in the adjacent segment were achieved with preoperative parameters of FJs: angulation > 60°, while in the absence of FJ tropism, a contralateral transfacetal fixation is possible (Figure 3), and in the presence of tropism, it is advisable to perform bilateral transpedicular stabilization. (Figure 4)

DISCUSSION

Currently, approaches to surgical treatment of patients with different degrees of degenerative diseases of FJs are not well defined.[2,3] Various surgical interventions for degenerative FJ diseases are performed in spinal surgery, ranging from minimally invasive puncture techniques to partial or total facetectomy with rigid stabilization, with ambiguous results.[1,13,14] This is primarily due to the lack of objective indications for choosing the type of surgical treatment, and a failure to take into account the individual anatomical features of FJs.[2,3]

With minimum degenerative changes of FJs - I–II degree according to the classification of Fujiwara A.,[2] conservative treatment is used, which is analogous to the therapeutic principle that osteoarthritis in any location consists in the use of non-steroidal anti-inflammatory drugs, hormonal anti-inflammatory therapy, drugs-chondroprotectors, and physiotherapy.[11] Minimally-invasive methods of treatment include the use of paravertebral blockades, radiofrequency, laser, chemodenervation of FJs, and puncture of FJs with the use of a synovial fluid prosthesis (facetoplasty).[2,3,10]

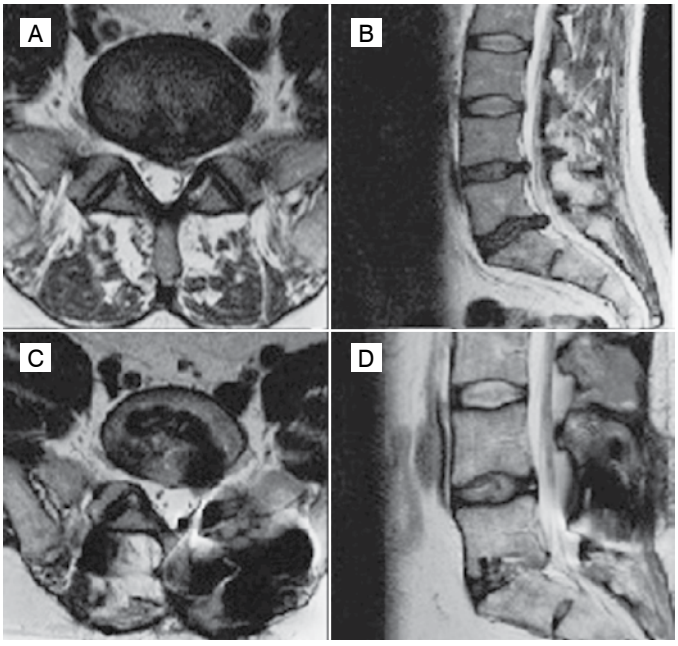

Figure 4. Patient P., 39 years old. MRI of the lumbosacral spine, T2 weighted images: a - axial projection: angulation of FJ - 65°, tropism is present; b - sagittal projection (arrow indicates Hernia of IVD L_V-S_I); c - axial projection after surgery in the volume of microsurgical discectomy L_V-S_I, interbody fusion L_V-S_I., transpedicular fixation L_V-S_I by the system of cannulated screws; d - sagittal projection after surgery. The level of pain in the lumbar spine according to VAS before surgery was 78 mm, and in the left lower limb, 72 mm, ODI - 62 scores. The level of pain in the lumbar spine according to VAS in 24 months after the surgery was 4 mm, and in the left lower limb, 3 mm, ODI - 8 scores.

With significant degenerative changes in FJs and the ineffectiveness of conservative treatment, a radical method of treatment is used - facetectomy followed by instrumental fixation of VMS.[2,4]

The accumulated experience of the adverse consequences of the use of interbody fusion and transpedicular stabilization contributes to the detailing of postoperative complications and the development of measures aimed at preventing their development.[15]

One of the most common complications of rigid fixation is degeneration of the adjacent segment, which is between 12 and 37%, often requiring revision surgery.[10,16-18]

In a number of cases, the development of postoperative pain syndrome is associated with impulse from the nociceptors of the IVD, which is caused by an increased load on the closure plates after the implantation of the cage, which is significantly higher than in the unchanged IVD.[19,20]

A good clinical outcome after rigid stabilization is 15 - 95% (with an average of 68%).[16-21] Gibson et al. found that 32% of cases in the late postoperative period developed pseudoarthrosis, accompanied by unsatisfactory clinical outcomes and instrumental signs of pathological mobility.[21] In addition, Gibson et al. showed that the high frequency of bone block formation is not correlated with long-term clinical outcomes.[22]

Unsatisfactory long-term clinical outcomes associated with the development of the syndrome of the adjacent segment, postoperative instability, pseudoarthrosis and scar intracanal changes have prompted researchers to search for the key factors that cause their development. Thus, many studies have confirmed the impact of angulation and tropism of FJs on the biomechanics of the spinal column.[23-25] However, no correlation has been made with the remote clinical outcomes of these neuroimaging parameters.

Many authors testify to the impact of tropism and angulation of FJs on the development of IVD degeneration.[23-25] However, to our knowledge, there is no study to date on the possible correlation of these morphometric parameters with a remote clinical outcome.

For the first time, Farfan H. et al. revealed a significant correlation between tropism of FJs and the formation of IVD hernias in the lumbosacral spine.[24] Also, the authors point out that the hernias of the lumbar IVD appear on the side of FJs with the smallest angle, since with this orientation of FJs, it is not capable of reducing torsion loads affecting on the fibrous ring during movement.[16,25]

Clinical studies are currently underway to investigate the relationship between tropism and the orientation of FJs with the onset of degenerative spondylolisthesis.[23,25]

Boden S. et al. [26] studied FJ angulations on MRI images from 140 patients and found that a more sagittal location and tropism of FJs contribute to the formation of degenerative spondylolisthesis.

Cinotti G. et al. according to CT data of 54 patients revealed a significant correlation between asymmetric of FJs and degenerative spondylolisthesis at the level of L_{IV}-L_V, L_V-S_I. [27]

Thus, the parameters of angulation and tropism of FJ can serve as objective criteria for a possible choice of surgical tactics, and for predicting a remote postoperative clinical outcome in patients with degenerative diseases of the lower lumbar VMS.

CONCLUSIONS

A comprehensive clinical and instrumental examination including lumbar spondylography, magnetic resonance imaging for objective analysis of morphostructural changes in the VMS is recommended for all patients with degenerative diseases of the lower lumbar spine.

The use of angulation and tropism parameters of FJs, which are determined by a non-invasive MRI method, enable the degree of degeneration of the anterior (IVD) and posterior (FJ) support complexes of the lower lumbar segments to be established, and possible tactics determined.

In the presence of neuroimaging parameters of angulation of FJs less than 60°, regardless of the presence of tropism, it is possible to perform total arthroplasty of IVD.

When detecting neuroimaging parameters of FJs angulation more than 60°, rigid stabilization of the operated segment is recommended, while in the absence of FJs tropism, a contralateral transfacetal fixation is possible; in the presence of tropism, it is expedient to perform bilateral transpedicular stabilization.

All authors declare no potential conflict of interest related to this article.

CONTRIBUTION OF THE AUTHORS: Each author made significant individual contributions to this manuscript. VAB (0000-0003-4349-7101)* were the main contributors in the drafting of the manuscript. AAK (0000-0001-9039-9147)*, AKO (0000-0003-1556-3095)*, and YYP (0000-0003-2633-7149)* performed the surgery, followed up patients and gathered clinical data. AKO evaluated the data from the statistical analysis. YYP, AAK and VAB performed the literature search and review of the manuscript, and contributed to the intellectual concept of the study. IVB (0000-0003-3549-0794)*. *ORCID (Open Researcher and Contributor ID).

REFERENCES

1. Kalichman L, Kim DH, Li L, Guermazi A, Hunter DJ. Computed tomography-evaluated features of spinal degeneration: prevalence, intercorrelation, and association with self-reported low back pain. Spine J. 2010;10(3):200-8.
2. Issack PS, Cunningham ME, Pumberger M, Hughes AP, Cammisa FP Jr. Degenerative lumbar spinal stenosis: evaluation and management. J Am Acad Orthop Surg. 2012;20(8):527-35.
3. Turner JA, Ersek M, Herron L, Haselkorn J, Kent D, Ciol MA, et al. Patient outcomes after lumbar spinal fusions. JAMA. 1992;268(7):907-11.

4. Adogwa O, Parker SL, Shau DN, Mendenhall SK, Aaronson OS, Cheng JS, et al. Preoperative Zung depression scale predicts outcome after revision lumbar surgery for adjacent segment disease, recurrent stenosis, and pseudarthrosis. Spine J. 2012; 12(3):179-85.
5. Arts MP, Kols NI, Onderwater SM, Peul WC. Clinical outcome of instrumented fusion for the treatment of failed back surgery syndrome: a case series of 100 patients. Acta Neurochir (Wien). 2012;154(7):1213-7.
6. Byvaltsev VA, Kalinin AA, Belykh EG, Sorokovikov VA, Shepelev VV. [Optimization of segmental lumbar spine instability treatment using minimally invasive spinal fusion technique]. Zh Vopr Neirokhir Im N N Burdenko. 2015; 79(3):45-54.
7. Kalinin AA, Byvaltsev VA. Relationship between vertebral metric parameters and outcome of surgical treatment of degenerative spondylolisthesis with multilevel lumbar intervertebral disc lesions. Hirurgiâ pozvonoočnika. 2015;12(4):56-62. (In Russ.)
8. Lurie JD, Tosteson TD, Tosteson A, Abdu WA, Zhao W, Morgan TS, et al. Long-term outcomes of lumbar spinal stenosis: eight-year results of the Spine Patient Outcomes Research Trial (SPORT). Spine (Phila Pa 1976). 2015;40(2):63-76.
9. Atlas SJ, Keller RB, Wu YA, Deyo RA, Singer DE. Long-term outcomes of surgical and nonsurgical management of lumbar spinal stenosis: 8 to 10 year results from the maine lumbar spine study. Spine (Phila Pa 1976). 2005;30(8):936-43.
10. Mannion AF, Denzler R, Dvorak J, Grob D. Five-year outcome of surgical decompression of the lumbar spine without fusion. Eur Spine J. 2010;19(11):1883-91.
11. Weinstein JN, Tosteson TD, Lurie JD, Tosteson A, Blood E, Herkowitz H, et al. Surgical versus nonoperative treatment for lumbar spinal stenosis four-year results of the Spine Patient Outcomes Research Trial. Spine (Phila Pa 1976). 2010;35(14):1329-38.
12. Adogwa O, Carr K, Fatemi P, Verla T, Gazcon G, Gottfried O,et al. Psychosocial factors and surgical outcomes: are elderly depressed patients less satisfied with surgery? Spine (Phila Pa 1976). 2014;39(19):1614-9.
13. Sinikallio S, Aalto T, Airaksinen O, Lehto SM, Kröger H, Viinamäki H. Depression is associated with a poorer outcome of lumbar spinal stenosis surgery: a two-year prospective follow-up study. Spine (Phila Pa 1976). 2011;36(8):677-82.
14. D'Angelo C, Mirijello A, Ferrulli A, Leggio L, Berardi A, Icolaro N, et al. Role of trait anxiety in persistent radicular pain after surgery for lumbar disc herniation: a 1-year longitudinal study. Neurosurgery. 2010;67(2):265-71.
15. Pakarinen M, Vanhanen S, Sinikallio S, Aalto T, Lehto SM, Airaksinen O, et al. Depressive burden is associated with a poorer surgical outcome among lumbar spinal stenosis patients: a 5-year follow-up study. Spine J. 2014;14(10):2392-6.
16. Miller JA, Derakhshan A, Lubelski D, Alvin MD, McGirt MJ, Benzel EC, et al. The impact of preoperative depression on quality of life outcomes after lumbar surgery. Spine J. 2015;15(1):58-64.
17. Nechanicka N, Barsa P, Harsa P. Psychosocial Factors in Patients Indicated for Lumbar Spinal Stenosis Surgery. J Neurol Surg A Cent Eur Neurosurg. 2016;77(5):432-40.
18. Maratos EC, Trivedi R, Richards H, Seeley H, Laing RJ. Psychological distress does not compromise outcome in spinal surgery. Br J Neurosurg. 2012;26(4):466-71.
19. Archer KR, Seebach CL, Mathis SL, Riley LH 3rd, Wegener ST. Early postoperative fear of movement predicts pain, disability, and physical health six months after spinal surgery for degenerative conditions. Spine J. 2014;14(5):759-67.
20. Mannion AF, Elfering A, Staerkle R, Junge A, Grob D, Dvorak J, et al. Predictors of multidimensional outcome after spinal surgery. Eur Spine J. 2007; 16(6):777-86.
21. Seebach CL, Kirkhart M, Lating JM, Wegener ST, Song Y, Riley LH 3rd, et al. Examining the role of positive and negative affect in recovery from spine surgery. Pain. 2012;153(3):518-25.
22. Anderson JT, Haas AR, Percy R, Woods ST, Ahn UM, Ahn NU. Clinical depression is a strong predictor of poor lumbar fusion outcomes among workers' compensation subjects. Spine (Phila Pa 1976). 2015;40(10):748-56.
23. Adogwa O, Parker SL, Shau DN, Mendenhall SK, Bydon A, Cheng JS, et al. Preoperative Zung depression scale predicts patient satisfaction independent of the extent of improvement after revision lumbar surgery. Spine J. 2013;13(5):501-6.
24. Murphy HA, Warnick E, McGintee R, Nicholson K, Hollern DA, Stawicki C, et al. Which Domains of the ODI Best Predict Change in Physical Function in Patients after Surgery for Degenerative Lumbar Spondylolisthesis? Spine (Phila Pa 1976). 2017.
25. Havakeshian S, Mannion AF. Negative beliefs and psychological disturbance in spine surgery patients: a cause or consequence of a poor treatment outcome? Eur Spine J. 2013;22(12):2827-35.
26. Roitberg BZ, Thaci B, Auffinger B, Kaplan L, Shen J, Brown FD, et al. Comparison between patient and surgeon perception of degenerative spine disease outcomes-a prospective blinded database study. Acta Neurochir (Wien). 2013;155(5):757-64.
27. Urban-Baeza A, Zárate-Kalfópulos B, Romero-Vargas S, Obil-Chavarría C, Brenes--Rojas L, Reyes-Sánchez A. Influence of depression symptoms on patient expectations and clinical outcomes in the surgical management of spinal stenosis. J Neurosurg Spine. 2015;22(1):75-9.
28. Djurasovic M, Glassman SD, Dimar JR 2nd, Crawford CH 3rd, Bratcher KR, Carreon LY. Changes in the Oswestry Disability Index that predict improvement after lumbar fusion. J Neurosurg Spine. 2012;17(5):486-90.
29. Adogwa O, Elsamadicy AA, Han JL, Cheng J, Karikari I, Bagley CA. Do measures of surgical effectiveness at 1 year after lumbar spine surgery accurately predict 2-year outcomes? J Neurosurg Spine. 2016;25(6):689-96.
30. Chaichana KL, Mukherjee D, Adogwa O, Cheng JS, McGirt MJ. Correlation of preoperative depression and somatic perception scales with postoperative disability and quality of life after lumbar discectomy. J Neurosurg Spine. 2011;14(2):261-7.
31. Misterska E, Jankowski R, Głowacki M. Psychometric properties of the Polish language version of the chronic pain coping inventory-42 for patients treated surgically due to herniated lumbar discs and spondylotic changes. Med Sci Monit. 2014;20:789-801.
32. Benaim C, Léger B, Vuistiner P, Luthi F. Validation of the French Version of the "Patterns of Activity Measure" in Patients with Chronic Musculoskeletal Pain. Pain Res Manag. 2017;2017:6570394.
33. Kovacs FM, Seco J, Royuela A, Peña A, Muriel A. Research The correlation between pain, catastrophizing, and disability in subacute and chronic low back pain: a study in the routine clinical practice of the Spanish National Health Service. Spine (Phila Pa 1976). 2011;36(4):339-45.
34. Cho S, Kim HY, Lee JH. Validation of the Korean version of the Pain Catastrophizing Scale in patients with chronic non-cancer pain. Qual Life Res. 2013; 22(7):1767-72.
35. Heneweer H, van Woudenberg NJ, van Genderen F, Vanhees L, Wittink H. Measuring psychosocial variables in patients with (sub) acute low back pain complaints, at risk for chronicity: a validation study of the Acute Low Back Pain Screening Questionnaire-Dutch Language Version. Spine (Phila Pa 1976). 2010;35(4):447-52.
36. Versteegh MM, Leunis A, Uyl-de Groot CA, Stolk EA. Condition-specific preference-based measures: benefit or burden? Value Health. 2012;15(3):504-13.
37. Misterska E, Jankowski R, Głowacki M. Chronic pain coping styles in patients with herniated lumbar discs and coexisting spondylotic changes treated surgically: Considering clinical pain characteristics, degenerative changes, disability, mood disturbances, and beliefs about pain control. Med Sci Monit. 2013; 19:1211-20.
38. Kim C, Harris JA, Muzumdar A, Khalil S, Sclafani JA, Raiszadeh K, et al. The effect of anterior longitudinal ligament resection on lordosis correction during minimally invasive lateral lumbar interbody fusion: Biomechanical and radiographic feasibility of an integrated spacer/plate interbody reconstruction device. Clin Biomech (Bristol, Avon). 2017;43:102-108.
39. Chotai S, Devin CJ, Archer KR, Bydon M, McGirt MJ, Nian H, et al. Effect of patients' functional status on satisfaction with outcomes 12 months after elective spine surgery for lumbar degenerative disease. Spine J. 2017; 17(12):1783-93.
40. Johansson AC, Linton SJ, Rosenblad A, Bergkvist L, Nilsson O. A prospective study of cognitive behavioural factors as predictors of pain, disability and quality of life one year after lumbar disc surgery. Disabil Rehabil. 2010;32(7):521-9.
41. Archer KR, Devin CJ, Vanston SW, Koyama T, Phillips SE, George SZ, et al. Cognitive-Behavioral-Based Physical Therapy for Patients With Chronic Pain Undergoing Lumbar Spine Surgery: A Randomized Controlled Trial. J Pain. 2016;17(1):76-89.
42. Chapman JR, Norvell DC, Hermsmeyer JT, Bransford RJ, DeVine J, McGirt MJ, et al. Evaluating common outcomes for measuring treatment success for chronic low back pain. Spine (Phila Pa 1976). 2011;36(21 Suppl):S54-68.
43. Donk RD, Verbeek ALM, Verhagen WIM, Groenewoud H, Hosman ATF, Bartels RHMA. Substantial clinical benefit for Neck Disability Index revisited: establishing the goal for treatment? Eur Spine J. 2018;27(6):1262-65.

THE IMPORTANCE OF PSYCHOLOGICAL TESTING IN PREDICTING THE EFFECTIVENESS OF LUMBAR SPINE SURGERY

A IMPORTÂNCIA DO TESTE PSICOLÓGICO NA PREVISÃO DA EFICÁCIA DA CIRURGIA DA COLUNA LOMBAR

LA IMPORTANCIA DE LAS PRUEBAS PSICOLÓGICAS EN LA PREDICCIÓN DE LA EFECTIVIDAD DE LA CIRUGÍA DE LA COLUMNA LUMBAR

Aleksandr V. Krutko [1], Olga N. Leonova [1], Eugene A. Cherepanov [1]

1. Novosibirsk Research Institute of Traumatology and Orthopaedics (NRITO) n.a. Ya.L. Tsivyan, Novosibirsk, Russia.

ABSTRACT

Objective: The result of treatment of patients with degenerative disc diseases is partly determined by the psychological characteristics of the patients. The aim of this study was to examine the correlations between the psychological scales scores in patients with degenerative lumbar disc diseases and the effectiveness of surgical treatment. Methods: The efficacy of the operation and patients' satisfaction were compared with the preoperative psychological characteristics, according to the questionnaires and scales (BBQ Symonds, Zung Scale, FABQ, PCI, BBQ Catastrophization). Results: In patients with neurogenic intermittent claudication syndrome without significant pain, the operative treatment depended significantly on the value of the BBQ Symonds scale ($p = 0.016$). In patients with severe radicular pain in the lower extremity, the effectiveness of the operation depended significantly on the value of the subscale "protection" of the PCI questionnaire ($p = 0.04$), the ODI index filled out before the operation ($p = 0.0$). In patients with lumbar syndrome, the effectiveness of operation depended significantly on the value of the PCI questionnaire as a whole ($p = 0.042$) and its subscores "rest" ($p = 0.028$), the index of the Oswestry filled out before the operation ($p = 0.035$). Conclusion: The effectiveness of the operation of degenerative lumbar disc diseases is associated with the results of preoperative psychological testing. It has been established that the BBQ Symonds scale, PCI protection and rest subscales, and the ODI questionnaire are the most significant; these psychological scales have the power to predict the effectiveness of surgical treatment. ***Level of Evidence II; Therapeutic Study - Investigating the Results of Treatment.***

Keywords: Intervertebral disc degeneration; Catastrophizing; Pain, Postoperative.

RESUMO

Objetivo: O resultado no tratamento de pacientes com doenças degenerativas do disco é parcialmente determinado pelas características psicológicas dos pacientes. O objetivo do estudo foi examinar as correlações entre as escalas de índice psicológico em pacientes com doenças degenerativas do disco lombar e a eficácia do tratamento cirúrgico. Métodos: A eficácia da operação e a satisfação dos pacientes foram comparadas com as características psicológicas pré-operatórias, de acordo com os questionários e escalas (BBQ Symods, Zung Scale, FABQ, PCI, Catastrofización de BBQ). Resultados: Em pacientes com a síndrome de claudicação neurogênica intermitente sem dor significativa, o tratamento cirúrgico dependeu significativamente do valor da escala BBQ Symods ($p = 0,016$). Em pacientes com dor radicular grave no membro inferior, a eficácia da operação dependeu significativamente do valor da "proteção" da subescala do questionário de ICP ($p = 0,04$), preenchido antes da operação pelo índice ODI ($p = 0,0$). Nos pacientes com síndrome lombar, a eficácia da operação dependia significativamente do valor do questionário PCI como um todo ($p = 0,042$) e seu subscore "repouso" ($p = 0,028$) e o índice do Oswestry preenchido antes da operação ($p = 0,035$). Conclusão: A efetividade do funcionamento das doenças degenerativas do disco lombar está associada aos resultados dos testes psicológicos pré-operatórios. Foi estabelecido que a escala BBQ Symods, subescalas de proteção e descanso de PCI e o questionário de ODI são mais significativos; essas escalas psicológicas têm poder preditivo em relação à eficácia do tratamento cirúrgico. ***Nível de Evidência II; Estudo Terapêutico – Investigação dos resultados do tratamento.***

Descritores: *Degeneração do disco intervertebral; Catastrófização; Dor pós-operatória.*

RESUMEN

Objetivo: El resultado del tratamiento de pacientes con enfermedades degenerativas del disco está parcialmente determinado por las características psicológicas de los pacientes. El objetivo del estudio fue examinar las correlaciones entre las escalas de índice psicológico en pacientes con enfermedades degenerativas del disco lumbar y la efectividad del tratamiento quirúrgico. Métodos: Se comparó la eficacia de la operación y la satisfacción de los pacientes con las características psicológicas preoperatorias según los cuestionarios y escalas (BBQ Symonds, Zung Scale, FABQ, PCI, Catastrofización de BBQ). Resultados: En pacientes con síndrome de claudicación neurogénica intermitente sin dolor significativo, el tratamiento quirúrgico dependió significativamente del valor de la escala BBQ Symonds ($p = 0,016$). En pacientes con dolor radicular severo en la extremidad inferior, la efectividad de la operación dependió significativamente del valor de la subescala "protección" del cuestionario PCI ($p = 0,04$), el índice ODI llenado antes de la operación ($p = 0,0$). En pacientes con síndrome lumbar, la efectividad de la operación dependió significativamente del valor del cuestionario PCI como un todo ($p = 0,042$) y sus subcategorías "reposo" ($p = 0,028$), el índice de Oswestry llenado antes de la operación ($p = 0,035$). Conclusión: La efectividad de la operación

Study conducted: Clinical Biorasi LLC 19495 Biscayne Blvd #900, Miami, FL 33180,
Correspondence: Neurosurgery Department of NRITO, Frunze str., 17, Novosibirsk, 630091, Russia. ortho-ped@mail.ru

http://dx.doi.org/10.1590/S1808-185120181703193836

Coluna/*Columna.* 2018;17(3):227-32

Received on 04/04/2018, accepted on 07/25/2018

de las enfermedades degenerativas del disco lumbar se asocia con los resultados de las pruebas psicológicas preoperatorias. Se ha establecido que la escala de BBQ Symonds, las subescalas de protección y reposo PCI y el cuestionario ODI son los más significativos; estas escalas psicológicas tienen poder predictivo en relación con la efectividad del tratamiento quirúrgico. ***Nivel de Evidencia II; Estudio Terapéutico - Investigación de los resultados del tratamiento.***

Descriptores: *Degeneración del disco intervertebral; Catastrofizácion; Dolor posoperatorio.*

INTRODUCTION

Degenerative diseases of the spine are one of the most common groups of pathologies of the musculoskeletal system. Their prevalence in the general population is around 25% and increases to 45% in individuals over 60 years of age.[1,2] This nosology is characterized by chronic pain in the back or leg, and is often accompanied by persistent disability.

Progression of pain, or chronic pain syndrome, the development of a neurological deficit, or failure of conservative treatment, may be factors that require surgical intervention. Even though spinal interventions have demonstrated surgical efficacy, the clinical outcomes of the surgeries range from 35 to 75% improvement, depending on the type of surgery perfomed performed,[3-7] with up to 23% incidence of repeated surgeries.[8] Up to 40% of patients note that the pain continues after the surgical treatment, albeit with lower intensity.[9-11] These results indicate that the efficiency of treatment of patients with degenerative diseases of the spine is determined solely by the completeness of surgical treatment. There is increasing evidence that the observed variability in outcomes of spinal surgeries may be partially attributed to the preoperative psychological characteristics of patients in their study Adogwa and Carr et al[12] demostrated demonstrated that preoperative screening of psychological status enables the identification of patients at risk of unfavorable outcomes of surgery; the baseline level of psychological predisposition was useful in predicting poor clinical outcomes after surgery.

The individual psychological characteristics of patients that affect the outcome of back pain and its treatment efficacy have now been established. Sinikallio et al. noted that favorable outcomes of treatment were recorded in patients with normal mood and without signs of depression, while depressive symptoms strongly influenced the ability of patients to accept the optimal treatment outcome.[13] Patients with high levels of depression, anxiety and fear avoidance often have unsatisfactory surgical outcomes and rarely return to work after the surgery.[14-17] A group of other authors, based on their own research, concluded that high levels of anxiety and depression alone do not define unfavorable outcomes of surgical treatment for degenerative diseases of the spine.[18] Archer et al.[19] proved that fear of physical activity, overcoming difficulties, positive attitudes and depression individually and independently correlate with chronic back pain and subsequent disability, and also reduce physical activity after surgery.[20,21]

According to a group of researchers, psychological screening and appropriate therapy for the disorders identified can improve the results of surgical treatment.[22] However, patients' satisfaction with surgery is directly correlated with the level of preoperative depression, regardless of the type of surgical intervention performed.[23]

There are currently many questionnaires and scales that allow reliable evaluation of patients' psychological characteristics. The most common ones are the scales that determine the patient's level of anxiety and the presence of depressive symptoms (Zung's scale, Hospital Anxiety and Depression Scale, questionnaires showing the level and avoidance of physical activity, the patients' ability to work (Fear Avoidance Beliefs Questionnaire, FABQ), Pain Coping Index (PCI), Oswestry questionnaire, Tampa scale of kinesiophobia, as well as some scales that assess patients' fears, attitudes and beliefs about their disease and the possibility of recovery (Back Beliefs Questionnaire (BBQ), Misbeliefs questionnaire, Catastrophization Scale). There are also psychological questionnaires that help to determine the subjective effectiveness of the treatment and patients' satisfaction (ODI change, Likert's scale). Their application in practical medicine is necessary to assess the patient's satisfaction with the treatment and potentially predict the effectiveness of the treatment.

Published studies on the subject are based on various hypotheses and use various scales and questionnaires. Therefore, current practice lacks a standardized protocol for detecting psychological disorders that can have significant effect on the results of surgical treatment. A universal system for assessing the psychological state of patients with degenerative diseases of the spine already at the preoperative stage will help to predict the effectiveness of surgical treatment.

The aim of our study was to examine the relationships between psychological scores of patients with degenerative diseases of the spine and their satisfaction with subsequent surgical intervention. It was also important to identify psychological scales that have the greatest predicative force in different degenerative diseases of the spine.

METHODS

We conducted a prospective study of the effect of patients' psychological characteristics and personal beliefs on the outcomes of surgical treatment of degenerative diseases of the spine.

The study included 150 patients from the Novosibirsk Neurosurgical Unit No.2 of Novosibirsk NIITO who underwent surgical treatment for osteochondrosis of the lumbar spine. Patients with radicular pain syndrome and/or neurological deficits were included in the study. All patients underwent surgical treatment in the form of decompressive or decompressive-stabilizing surgeries. The patients were divided into three groups, based on the key syndrome. The first group consisted of patients with neurogenic intermittent claudication without severe pain syndrome in any area. The second group consisted of patients with predominant radicular pain syndrome without pronounced neurologic deficit. The third group consisted of patients with predominant lumbar syndrome also without marked neurological disorders.

The inclusion criteria were: over 18 years of age on the day of enrollment; planned surgical treatment for degenerative lumbar spine disorder; and a high likelihood of the patient remaining under a doctor's supervision and being available for a telephone interview 1 year after the surgery. The exclusion criteria were: the presence of concomitant pathology, which could cause back pain (malignant neoplasm, rheumatoid diseases, osteoporosis, fractures of the vertebral bodies); long-term use of corticosteroids; and patient's reluctance to adhere to recommendations in the postoperative period.

All patients underwent radiation diagnostics at the preoperative stage to confirm the substrate of the underlying disease, as well as a general clinical examination, and examination by specialists in related fields, if necessary.

Psychological tests using questionnaires were employed to assess the personal attitudes of the patients towards their disease, and their general condition. This psychological testing was performed prior to the surgery to identify relationships between baseline psychological characteristics and the outcome of surgical treatment.

The study was approved by the local ethics committee under protocol no. 258, 11/12/2015. All patients provided written informed consent in accordance with the Declaration of Helsinki, which included their consent for the use of their data in the analyses and in the presentation of the results. The researcher received written informed consent from every potential participant in the study.

Data collection

Demographic parameters were recorded for each patient on enrollment into the study: sex, age, clinical diagnosis, type of planned surgical intervention. The study did not interfere with the patients' treatment plans. The study included patients who were scheduled to undergo surgical intervention for pain and/or neurological deficits caused by degenerative diseases of the lumbar spine.

The psychological testing was performed at the preoperative stage, one day before the surgical intervention and the baseline testing included seven questionnaires.

The Back Beliefs Questionnaire (BBQ Symonds) describes the patient's beliefs about their current disease, prognosis, and possibility of recovery. Fear of intensifying the pain leads to avoidance of physical activity, which, in turn, leads to chronic pain and decreased ability to work. The evaluation was carried out using a questionnaire with 14 items, with responses on a scale of "do not agree" to "agree".

The Zung scale is based on analytical study of depression symptoms and assesses both psychological and physiological symptoms of depression in a patient. The respondents answer each question according to the extent to which it applied to them during the past week. There are types of answers in this questionnaire. The result is calculated in points and then a qualitative score is determined based on the sum of points, from "no depression" to "severe depression".

Waddell's Fear-Avoidance Beliefs Questionnaire (FABQ) is used to determine the degree of fear of pain and its impact on the patient's performance in two critical areas: "work" and "physical activity". The evaluation is performed by calculating points over 21 items. The higher the total score, the greater the degree of the patient's fear of pain during movements.

The Pain Coping Inventory (PCI) is used to determine how people cope with back pain. The score is calculated across 8 scales ("Guarding", "Resting", "Asking for Assistance", "Relaxation", "Coping", "Task Persistence", "Social Support", "Exercises") and two main types of adaptation: "Active" and "Passive".

The Catastrophization Scale (BBQ Catastrophization) is used to assess catastrophic thinking associated with pain. The questionnaire consists of 13 questions that describe different thoughts and feelings that patients can experience in connection with pain. The patients were asked to evaluate their feelings on a scale from zero ("none") to four ("I think about it all the time"). The maximum score describes feelings of despair and helplessness.

Oswestry Disability Index (ODI) is an assessment of the degree of disability. The questionnaire contains 10 questions, each containing six possible responses ranging from zero to five. The total value is converted to a scale of 0 to 100. According to studies, the Oswestry questionnaire is recommended by the World Health Organization to assess treatment effectiveness. The ODI is focused on physical activity, not on the psychological circumstances of pain syndrome.

The second round of psychological testing was conducted in the early postoperative period, when the patients were discharged for outpatient care, and consisted of filling in the Oswestry questionnaire.

The final psychological testing was conducted by a telephone interview one year after the surgery to evaluate its effectiveness and determine the patients' satisfaction. The patients completed the Oswestry questionnaire and the Likert scale.

The Likert scale shows patients' subjective satisfaction with the surgical treatment: from "absolutely dissatisfied" to "absolutely satisfied".

To assess the effectiveness of the surgical treatment, two Oswestry questionnaire scores were compared: before the surgery and one year after the surgery (ODI change). As recommended by the authors of the Oswestry questionnaire, changes of 10 points or more were considered clinically significant. Using this criterion, changes of 10 points or more towards the lower score were considered a sign of improvement, changes in either direction by less than 10 points were considered a lack of effect, and an increase in the Oswestry scale score of 10 points or more was considered a sign of worsening.

RESULTS

Baseline characteristics

Three groups of patients were formed over the course of the study. The first group consisted of patients with neurogenic intermittent claudication without severe pain syndrome in any area. This syndrome was caused by stenosis of the vertebral canal in the lumbar spine. This group included 19 patients (12 women and seven men) with a mean age of 57.95 ± 7.08 years (Group 1). The second group consisted of patients with pronounced pain syndrome in the lower extremity due to radiculopathy caused by a herniated disc in the lumbar spine. This group included 85 patients (44 women and 41 men) with a mean age of 45.22 ± 12.98 years (Group 2). The third group included patients with predominant back pain without pronounced neurologic deficit, which corresponded to functional incompetence of the lumbar spine. The group included 26 patients (10 women and 16 men) with a mean age of 48.54 ± 10.71 years. (Group 3)

These groups were comparable in terms of sex, with no significant differences between them. (Table 1)

Patients in the first group were significantly older than patients in the second and third groups ($p < 0.05$). There were no significant differences between patients' ages in the second and third groups.

The patients underwent appropriate surgical treatment based on the established clinical diagnosis. The patients of the first group, who suffered from neurogenic intermittent claudication due to stenosis of the vertebral canal of the lumbar spine, underwent stabilizing operations. The patients from the second group, whose leading syndrome was radiculopathy due to a herniated disc in the lumbar spine, underwent decompressive or decompressive-stabilizing operations. The patients of the third group, suffering from low back pain as a manifestation of the functional incompetence of the lumbar spine, underwent stabilizing operations.

Comparative analysis of the psychological questionnaires scores (Table 2) in the three study groups, did not reveal significant pre-operative differences between the groups as measured by Symonds Catastrophization Scale, Zung scale, physical activity subscale of the Wadell's Fear-Avoidance Beliefs Questionnaire (FABQ), general scale of Pain Coping Index, general Back Beliefs Scale, and Oswestry scale (in all the cases, $p > 0.05$).

Based on the Zung scale scores, only a small proportion of patients in all groups experienced mild depression (up to 7.69% in the third group); most of the subjects had no depression.

Significant differences were observed between the first and second group ($p < 0.05$) according to the "work" subscale of Waddell's Fear-Avoidance Belief Questionnaire (FABQ).

Although the overall score on the Pain Coping Index did not reveal any differences between the groups, significant differences were observed in subscale comparison; there was significant difference between the first and second group ($p < 0.05$) on the "Resting" subscale.

There were significant differences between the first and second group ($p < 0.05$) in the Catastrophization Scale (BBQ).

Therefore, Group 1 is characterized as being older, and there are significant differences in the following psychological scales: "work" subscale of Fear-Avoidance Beliefs Questionnaire (compared to groups 2 and 3), "Resting" subscale of Pain Coping Index (compared to group 2), Catastrophization scale (compared to group 2). There were no significant differences between the second and third group at the preoperative stage.

Table 1. Characteristics of groups of patients by sex and age.

Name	G0	G1	G2	p.01	p.02	p.12
Sex : F	12 [63.16 %]	44 [51.76%]	10 [38.46%]	0.518	0.182	0.335
Sex : M	7 [36.84%]	41 [48.24%]	16 [61.54%]			
Age, M±m	57.95 ± 7.08	45.22 ± 12.98	48.54 ± 10.71	0	0.001	0.196

Table 2. General baseline characteristic of patients according to the psychological questionnaires, M ± m, medians (the first quantile: the third quantile).

Name	G0	G1	G2	p.01	p.02	p.12
Symonds Catastrophization Score	34 (28:37)	31 (25:35)	31 (25:36)	0.183	0.605	0.357
Zung	0.33 (0.24:0.42)	0.25 (0.17:0.35)	0.25 (0.17:0.4)	0.078	0.505	0.395
Depression (Zung): light	1 [5.26%]	5 [5.88%]	2 [7.69%]	1.000	1.000	0.665
Depression (Zung): no	18 [94.74%]	80 [94.12%]	24 [92.31%]	1.000	1.000	0.665
FABQ phys act score	18 (15.5:0.5)	18 (15:21)	18 (5:20)	0.816	0.703	0.463
FABQ work score	32 (25:37)	24 (16:33)	24 (16:34)	0.014	0.112	0.542
Adapt	68.8 ± 12.2	65.3 ± 13.74	67.62 ± 12.6	0.278	0.752	0.427
Guarding (III)	5.11 (4.28:5.67)	4.67 (3.78:5.44)	4.67 (3.78:5.64)	0.183	0.345	0.953
Resting (III)	6 (5:6.43)	5 (4:5.86)	5 (4 :6)	0.031	0.117	0.382
Asking for assistance (III)	4.5 (2.38:5.25)	3.75 (2.75:5.5)	3.75 (2.75:4.88)	0.820	0.490	0.683
Relaxation (Well)	4 (2.36:4.86)	3.14 (2:4.29)	3.14 (2:4.43)	0.188	0.756	0.181
Coping Self-statements (Well)	5.09 (3.5:5.77)	4.36 (2.91:5.55)	4.36 (2.91:5.91)	0.391	0.621	0.109
Task persistence (Well)	4.67 (3.67:5.17)	4.33 (3:5.33)	4.33 (3:6.13)	0.646	0.394	0.158
Social support (Other)	4.56 ± 1.83	4.17 ± 1.53	4.1 ± 1.6	0.399	0.388	0.845
Exercise/Stretch (Well)	3.67 (2.71:5.42)	3.33 (2:4.42)	3.33 (2:5.92)	0.198	0.827	0.371
BBQ Catastrophization	35 (21.5:39.5)	22 (14:30)	22 (14:2.75)	0.011	0.071	0.892
ODI on admission	44.6 ± 13.91	40.73 ± 6.98	47.06 ± 5.46	0.302	0.579	0.081

Efficacy of surgery

The patients completed the Oswestry questionnaire again upon discharge from inpatient care, enabling evaluation of the dynamics of the pain syndrome and the results of surgical treatment in the early postoperative period. The Oswestry "after surgery" score in patients of the second group was found to be significantly lower than the corresponding index in patients of the third group ($p < 0.05$). (Table 3)

To assess the long-term outcomes of surgical treatment, the Oswestry questionnaire was completed one year after the surgery, and the patients also assessed their satisfaction using the Likert scale. (Table 4)

The Oswestry "in 1 year" score decreased in all three groups compared to baseline; for the patients of the second group, this index was significantly lower than for those of the first and third groups ($p < 0.05$).

The ODI change is the difference between the Oswestry index "on admission" and "1 year after the surgery", and determines the effectiveness of the treatment performed. Based on the value of this parameter, a positive effect of surgical treatment was observed in all three study groups, as measured by a decrease in the score of more than 10 points. There were no significant differences between the groups ($p > 0.05$).

Based on the Likert scale, the patients of all three groups were "very satisfied" with the results of the surgery. However, significant differences were observed between the results for groups 2 and 3 ($p < 0.05$).

Thus, the patients from the second group are characterized as having higher physical activity "after surgery" (ODI after surgery) compared to patients of the third group as well as "one year later" (ODI after one year) compared to patients of the first and third groups. In addition, the patients of the second group were more satisfied with the treatment compared to those of the third group.

Table 3. Values of the Oswestry index after the surgery, M ± m.

Name	G0	G1	G2	p.01	p.02	p.12
ODI after surgery	36.84 ±14	31.16±14.54	38.44±15.08	0.124	0.716	0.036

Table 4. Dynamics of ODI values 1 year later and the Likert scale, M ± m, medians (the first quantile: the third quantile).

Name	G0	G1	G2	p.01	p.02	p.12
ODI after 1 year	28.89 (16.89:33.33)	12 (2:26)	12 (2:40)	0.007	0.662	0.012
ODI change	-16.89±8.91	-23.99±1.31	-19.64±1.13	0.159	0.649	0.364
Likert subjective	2 (1:3)	2 (1:3)	2 (1:2)	0.592	0.145	0.020

The relationship between the psychological scales and the outcome

Given that the ODI change and the Likert scale demonstrated the effectiveness of surgical treatment and patients' satisfaction, we attempted to identify the relationship between these parameters and the demographic and psychological characteristics, using regression analysis.

It has been established that the effectiveness of surgical treatment and satisfaction with its outcome do not depend on the sex and age of a patient ($p > 0.05$).

It has been shown that ODI change significantly depended on the "Guarding" subscale score of the Pain Coping Index questionnaire and the Oswestry questionnaire score, completed before the surgery ($p < 0.05$).

It has been established that the ODI change in the first group (in patients without pain syndrome with neurogenic intermittent claudication) depended significantly on the value of the Symonds Catastrophization Scale ($p < 0.05$).

It has been shown that ODI change in the second group (in patients with radiculopathy) depended significantly on the "Guarding" subscale score of the Pain Coping Index questionnaire and the Oswestry questionnaire score, completed before the surgery ($p < 0.05$).

It has been shown that ODI change in the third group (in patients with low back pain) depended significantly on the overall score on Pain Coping Index and its "Resting" subscale and the Oswestry questionnaire score, completed before the surgery ($p < 0.05$). In this group of patients, the Likert score (satisfaction with the treatment) depended significantly on "Passive" subscale score of Back Beliefs Questionnaire ($p < 0.05$).

The patients without pain syndrome (Group 1) are characterized by predominant fears about the disease, its prognosis and treatment options to a greater degree (according to Symonds Catastrophization scores).

DISCUSSION

According to the results of the study, the effectiveness of surgical treatment of osteochondrosis does not depend on the patient's demographic parameters (sex and age), while satisfaction with the treatment does not depend on the patient's demographic and psychological characteristics. The effectiveness of surgical treatment is significantly associated with the severity of changes in a patient's psychological state, as identified by the psychological questionnaires completed before the surgery (Symonds Catastrophization scale, "Guarding" and "Resting" subscales of the Pain Coping Index, and the Oswestry questionnaire index completed before surgery).

To date, several studies have been conducted to assess the

risks of surgical treatment of patients with degenerative diseases of the spine and predict their outcomes. Great attention is given to psychological characteristics of patients as a parameter contributing to the effectiveness of surgical treatment and patient satisfaction with its outcome. Preoperative assessment of the patients' psychological characteristics, by filling out questionnaires and scales, allows us to identify factors that have predicative effect on the result of surgical treatment.

The effectiveness of surgical treatment is estimated by a change in the Oswestry index,[23,24] reduction of pain syndrome as measured by the VAS scale, and changes in the parameters of other psychological scales (Catastrophization scale, Pain Coping Index, etc.).[25-27] However, only the Oswestry index has recommendations for interpreting changes in the index, which is necessary to evaluate the effectiveness of treatment.[28,29] According to the literature, the scales determining anxiety and depression are of the greatest importance. Kaisorn L. Chaichana et al. showed that the Zung scale enables the likelihood of clinical recovery to be better predicted in patients after decompressive surgery.[30] According to Owoicho Adogwa et al., the Zung scale score is an independent predictor of the outcome of surgical treatment.[23] However, in our study, the Zung scale score did not show significant correlation with the efficacy of surgical treatment; most subjects did not have depression, only 7.69% of patients with lumbar disorders had mild depression, and there were no significant correlation with the efficacy of the surgery.

Among numerous questionnaires assessing the physical activity of patients with osteochondrosis and their adaptation to pain, our study identified the Catastrophization scale, the Pain Coping Index (PCI), and the Oswestry questionnaire as those of the greatest importance.

Many studies have demonstrated a correlation between the patient's physical and psychological state. Great attention should be paid to models describing the patient's behavior when coping with the pain. The way a person copes with pain characterizes the degree of their adaptation to unfavorable factors in general.[31,32] It has been shown that an exaggerated negative reaction to expected or actual pain, as measured by the Catastrophization scale, correlates with surgical outcomes.[33,34] We have shown that in patients with neurogenic intermittent claudication, the effectiveness of surgical treatment depends on the Catastrophization scale score. This indicates that the more worried the patient is about their current state of health, prognosis and possibilities of recovery, the less effective the treatment will be.

Models such as "Resting", "Guarding" and "Coping" are characteristic of poor adaptation to pain.[35,36] According to Misterska E et al., "Guarding" subscale of the PCI is closely correlated with the severity of radicular pain syndrome.[37] A number of researchers note the correlation between the Catastrophization Scale (PCI) and the ODI score, before the surgery and three years after surgery.[38] In our study, patients with radicular pain syndrome typically followed the "Guarding" model and a significant correlation was established between this subscale and the effectiveness of surgical treatment. Patients with low back pain typically employed the "Resting" adaptation model, and the score on this subscale was closely correlated with the effectiveness of the surgery.

According to the literature, the Oswestry questionnaire is closely correlated with the level of physical activity, severity of pain,[28,29] and treatment satisfaction.[39] According to our data, the effectiveness of the surgery in patients with severe pain syndrome depends significantly on the Oswestry index before the surgery. The effectiveness of the treatment is defined by comparing the level of restrictions of physical activity due to pain in the back or leg, both before and after the surgery.

Patient satisfaction is measured by the Likert scale, which is a simple dichotomous scale ("yes" or "no").[25,40] The Likert scale is widely used in medical practice as a universal and simple tool for measuring this indicator.[13,41] Our work shows that patients' satisfaction as measured by the Likert scale does not depend on sex and age, presence of pain, or type of surgical intervention, which is consistent with the data of other researchers.[42,43] No significant correlation has been identified between patients' satisfaction and their psychological characteristics.

Based on the results of our study, we have identified the psychological scales that can help to assess personality traits that have significant impact on the effectiveness of ongoing surgical treatment. Given that the scales used to assess a patient's physical activity have the greatest prognostic value, this aspect should be studied in more detail. It is necessary to establish threshold values for psychological questionnaires for predicting the effectiveness of ongoing surgical treatment. Future results may require adjustments to the algorithm of preoperative management of patients with degenerative diseases of the spine.

CONCLUSIONS

According to the results of our study, the results of the psychological testing demonstrate significant correlation with the effectiveness of the surgical treatment of osteochondrosis and patients' satisfaction with the procedure. It has been established that the Symonds Catastrophization scale, "Guarding" and "Resting" subscales of the Pain Coping Index, "Avoidance" subscale of the Back Beliefs Questionnaire and the Oswestry questionnaire are of the greatest significance; these psychological scales have predictive power for the effectiveness of surgical treatment. These psychological questionnaires should be included in the preoperative examination plan for patients with degenerative diseases of the spine, which will enable the results of surgical treatment to be better predicted.

All authors declare no potential conflict of interest related to this article.

CONTRIBUTION OF THE AUTHORS: Each author made significant individual contributions to this manuscript. AVK (0000-0002-2570-3066)*: drafting of the entire research project, intellectual concept, revision and performing the surgeries, statistical analysis, review the manuscript. ONL (0000-0002-9916-3947)*: intellectual concept, gathering clinical data, analysis of the statistical data, writing the manuscript, and the literature search. EAC (0000-0001-6962-1401)*: intellectual concept, drafting of the entire research project, statistical analysis, writing the manuscript. *ORCID (Open Researcher and Contributor ID).

REFERENCES

1. Kalichman L, Kim DH, Li L, Guermazi A, Hunter DJ. Computed tomography-evaluated features of spinal degeneration: prevalence, intercorrelation, and association with self-reported low back pain. Spine J. 2010. 10(3):200-8.
2. Issack PS, Cunningham ME, Pumberger M, Hughes AP, Cammisa FP Jr. Degenerative lumbar spinal stenosis: evaluation and management. J Am Acad Orthop Surg. 2012. 20(8):527-35.
3. Turner JA, Ersek M, Herron L, Haselkorn J, Kent D, Ciol MA et al. Patient outcomes after lumbar spinal fusions. JAMA. 1992. 19;268(7):907-11.
4. Adogwa O, Parker SL, Shau DN, Mendenhall SK, Aaronson OS, Cheng JS et al. Preoperative Zung Depression Scale predicts outcome after revision lumbar surgery for adjacent segment disease, recurrent stenosis, and pseudarthrosis. Spine J. 2012, Vols. 12(3):179-85.
5. Arts MP, Kols NI, Onderwater SM, Peul WC. Clinical outcome of instrumented fusion for the treatment of failed back surgery syndrome: a case series of 100 patients. Acta Neurochir (Wien). 2012. 154(7):1213-7.
6. Byvaltsev VA, Kalinin AA, Belykh EG, Sorokovikov VA, Shepelev VV. Optimization of segmental lumbar spine instability treatment using minimally invasive spinal fusion technique. Zh Vopr Neirokhir Im N N Burdenko. 2015. 79(3): 45-54.
7. Kalinin AA, Byvaltsev VA. Relationship between vertebral metric parameters and outcome of surgical treatment of degenerative spondylolisthesis with multilevel lumbar intervertebral disc lesions. Hirurgiâ pozvonočnika. 12(4) (In Russ.), 2015, 56-62.

8. Lurie JD, Tosteson TD, Tosteson A, Abdu WA, Zhao W, Morgan TS, et al. Long-term outcomes of lumbar spinal stenosis: eight-year results of the Spine Patient Outcomes Research Trial (SPORT). Spine (Phila Pa 1976). 2015, Vols. 40(2):63-76.
9. Atlas SJ, Keller RB, Wu YA, Deyo RA, Singer DE. Long-term outcomes of surgical and nonsurgical management of lumbar spinal stenosis: 8 to 10 year results from the maine lumbar spine study. Spine (Phila Pa 1976). 2005, Vols. 30(8):936-43.
10. Mannion AF, Denzler R, Dvorak J, Grob D. Five-year outcome of surgical decompression of the lumbar spine without fusion. Eur Spine J. Nov, 2010, Vols. 19(11):1883-91.
11. Weinstein JN, Tosteson TD, Lurie JD, Tosteson A, Blood E, Herkowitz H et al. Surgical versus nonoperative treatment for lumbar spinal stenosis four-year results of the Spine Patient Outcomes Research Trial. Spine (Phila Pa 1976). 2010, Vols. 35(14):1329-38.
12. Adogwa O, Carr K, Fatemi P, Verla T, Gazcon G, Gottfried O. et al. Psychosocial factors and surgical outcomes: are elderly depressed patients less satisfied with surgery? Spine (Phila Pa 1976). 2014, Vols. 39(19):1614-9.
13. Sinikallio S, Aalto T, Airaksinen O, Lehto SM, Kröger H, Viinamäki H. Depression is associated with a poorer outcome of lumbar spinal stenosis surgery: a two-year prospective follow-up study. Spine (Phila Pa 1976). 2011, Vols. 36(8):677-82.
14. D'Angelo C, Mirijello A, Ferrulli A, Leggio L, Berardi A, Icolaro N. et al. Role of trait anxiety in persistent radicular pain after surgery for lumbar disc herniation: a 1-year longitudinal study. Neurosurgery. 2010 r., T. 67(2):265-71.
15. Pakarinen M, Vanhanen S, Sinikallio S, Aalto T, Lehto SM, Airaksinen O. et al. Depressive burden is associated with a poorer surgical outcome among lumbar spinal stenosis patients: a 5-year follow-up study. Spine J. 2014, 14(10):2392-6.
16. Miller JA, Derakhshan A, Lubelski D, Alvin MD, McGirt MJ, Benzel EC et al. The impact of preoperative depression on quality of life outcomes after lumbar surgery. Spine J. 2015, 15(1):58-64.
17. Nechanicka N, Barsa P, Harsa P. Psychosocial Factors in Patients Indicated for Lumbar Spinal Stenosis Surgery. J Neurol Surg A Cent Eur Neurosurg. 2016, 77(5):432-40.
18. Maratos EC, Trivedi R, Richards H, Seeley H, Laing RJ. Psychological distress does not compromise outcome in spinal surgery. Br J Neurosurg. 2012, 26(4):466-71.
19. Archer KR, Seebach CL, Mathis SL, Riley LH 3rd, Wegener ST. Early postoperative fear of movement predicts pain, disability, and physical health six months after spinal surgery for degenerative conditions. Spine J. 2014, 14(5):759-67.
20. Mannion AF, Elfering A, Staerkle R, Junge A, Grob D, Dvorak J et al. Predictors of multidimensional outcome after spinal surgery. Eur Spine J. 2007, 16(6):777-86.
21. Seebach CL, Kirkhart M, Lating JM, Wegener ST, Song Y, Riley LH 3rd et al. Examining the role of positive and negative affect in recovery from spine surgery. Pain. 2012, 153(3):518-25.
22. Anderson JT, Haas AR, Percy R, Woods ST, Ahn UM, Ahn NU. Clinical depression is a strong predictor of poor lumbar fusion outcomes among workers' compensation subjects. Spine (Phila Pa 1976). 2015, 40(10):748-56.
23. Adogwa O, Parker SL, Shau DN, Mendenhall SK, Bydon A, Cheng JS et al. Preoperative Zung depression scale predicts patient satisfaction independent of the extent of improvement after revision lumbar surgery. Spine J. 2013, 13(5):501-6.
24. Murphy HA, Warnick E, McGintee R, Nicholson K, Hollern DA, Stawicki C et al. Which Domains of the ODI Best Predict Change in Physical Function in Patients after Surgery for Degenerative Lumbar Spondylolisthesis? Spine (Phila Pa 1976). 2017.
25. Havakeshian S, Mannion AF. Negative beliefs and psychological disturbance in spine surgery patients: a cause or consequence of a poor treatment outcome? Eur Spine J. 2013, 22(12):2827-3.
26. Roitberg BZ, Thaci B, Auffinger B, Kaplan L, Shen J, Brown FD et al. Comparison between patient and surgeon perception of degenerative spine disease outcomes--a prospective blinded database study. Acta Neurochir (Wien). 2013, 155(5):757-64.
27. Urban-Baeza A, Zárate-Kalfópulos B, Romero-Vargas S, Obil-Chavarría C, Brenes--Rojas L, Reyes-Sánchez A. Influence of depression symptoms on patient expectations and clinical outcomes in the surgical management of spinal stenosis. J Neurosurg Spine. 2015, 22(1):75-9.
28. Djurasovic M, Glassman SD, Dimar JR 2nd, Crawford CH 3rd, Bratcher KR, Carreon LY. Changes in the Oswestry Disability Index that predict improvement after lumbar fusion. J Neurosurg Spine. 2012, 17(5):486-90.
29. Adogwa O, Elsamadicy AA, Han JL, Cheng J, Karikari I, Bagley CA. Do measures of surgical effectiveness at 1 year after lumbar spine surgery accurately predict 2-year outcomes? J Neurosurg Spine. 2016, 25(6):689-696.
30. Chaichana KL, Mukherjee D, Adogwa O, Cheng JS, McGirt MJ. Correlation of preoperative depression and somatic perception scales with postoperative disability and quality of life after lumbar discectomy. J Neurosurg Spine. 2011, 14(2):261-7.
31. Misterska E, Jankowski R, Głowacki M. Psychometric properties of the Polish language version of the chronic pain coping inventory-42 for patients treated surgically due to herniated lumbar discs and spondylotic changes. Med Sci Monit. 2014, 20:789-801.
32. Benaim C, Léger B, Vuistiner P, Luthi F. Validation of the French Version of the "Patterns of Activity Measure" in Patients with Chronic Musculoskeletal Pain. Pain Res Manag. 2017, 2017:6570394.
33. Kovacs FM, Seco J, Royuela A, Peña A, Muriel A and Network., Spanish Back Pain Research. The correlation between pain, catastrophizing, and disability in subacute and chronic low back pain: a study in the routine clinical practice of the Spanish National Health Service. Spine (Phila Pa 1976). 2011, 36(4):339-45.
34. Cho S, Kim HY, Lee JH. Validation of the Korean version of the Pain Catastrophizing Scale in patients with chronic non-cancer pain. Qual Life Res. 2013 č, 22(7):1767-72.
35. Heneweer H, van Woudenberg NJ, van Genderen F, Vanhees L, Wittink H. Measuring psychosocial variables in patients with (sub) acute low back pain complaints, at risk for chronicity: a validation study of the Acute Low Back Pain Screening Questionnaire-Dutch Language Version. Spine (Phila Pa 1976). 2010, 35(4):447-52.
36. Versteegh MM, Leunis A, Uyl-de Groot CA, Stolk EA. Condition-specific preference-based measures: benefit or burden? Value Health. 2012, 15(3):504-13.
37. Misterska E, Jankowski R, Głowacki M. Chronic pain coping styles in patients with herniated lumbar discs and coexisting spondylotic changes treated surgically: Considering clinical pain characteristics, degenerative changes, disability, mood disturbances, and beliefs about pain control. Med Sci Monit. 2013, 19:1211-20.
38. Kim C, Harris JA, Muzumdar A, Khalil S, Sclafani JA, Raiszadeh K et al. The effect of anterior longitudinal ligament resection on lordosis correction during minimally invasive lateral lumbar interbody fusion: Biomechanical and radiographic feasibility of an integrated spacer/plate interbody reconstruction device. Clin Biomech (Bristol, Avon). 2017, 43:102-108.
39. Chotai S, Devin CJ, Archer KR, Bydon M, McGirt MJ, Nian H et al. Effect of patients' functional status on satisfaction with outcomes 12 months after elective spine surgery for lumbar degenerative disease. Spine J. 2017, 17(12):1783-1793.
40. Johansson AC, Linton SJ, Rosenblad A, Bergkvist L, Nilsson O. A prospective study of cognitive behavioural factors as predictors of pain, disability and quality of life one year after lumbar disc surgery. Disabil Rehabil. 2010, 32(7):521-9.
41. Archer KR, Devin CJ, Vanston SW, Koyama T, Phillips SE, George SZ et al. Cognitive-Behavioral-Based Physical Therapy for Patients With Chronic Pain Undergoing Lumbar Spine Surgery: A Randomized Controlled Trial. J Pain. 2016, 17(1):76-89.
42. Chapman JR, Norvell DC, Hermsmeyer JT, Bransford RJ, DeVine J, McGirt MJ, Lee MJ. Evaluating common outcomes for measuring treatment success for chronic low back pain. Spine (Phila Pa 1976). 2011, 36(21 Suppl):S54-68.
43. Donk RD, Verbeek ALM, Verhagen WIM, Groenewoud H, Hosman ATF, Bartels RHMA. Substantial clinical benefit for Neck Disability Index revisited: establishing the goal for treatment? Eur Spine J. 2017.

RENAL CELL CARCINOMA METASTASIS OF THE SPINE: BLEEDING CONTROL METHODS

METÁSTASE DE CARCINOMA DE CÉLULAS RENAIS DA COLUNA VERTEBRAL: MÉTODOS DE CONTROLE DE SANGRAMENTO

METÁSTASIS ESPINAL DE CARCINOMA DE CÉLULAS RENALES: MÉTODOS DE CONTROL DE SANGRADO

Nikita Zaborovskii[1], Dmitrii Ptashnikov[1], Dmitrii Mikaylov[1], Sergei Masevnin[1], Oleg Smekalenkov[1]

1. Spine Surgery and Oncology Service. R.R.Vreden Russian Research Institute of Traumatology and Orthopedics, Saint-Petersburg, Russia.

ABSTRACT

Objective: This report compares various methods of bleeding control, and their influence on outcome and survival after decompression procedures for spinal metastasis of renal cell carcinoma (MRCC). Methods: A retrospective study. All patients underwent palliative decompression procedures. We compared 3 groups of patients stratified by methods of bleeding control. The first group (EMB) included 22 patients who underwent preoperative embolization of a tumor. The second group (HEM) consisted of 20 patients, treated surgically using intraoperative local hemostatic agents. In the third group (COMBI) 15 patients were treated with a combination of methods. Results: The average intraoperative blood loss for the EMB group was slightly less than the average for the HEM and COMBI groups, but without significant differences. The postoperative drainage loss in the HEM and COMBI groups was significantly less than in EMB group. The complication rate (infections, hematomas, neurological deficit) was practically equal in all groups. No statistically significant differences in local tumor recurrence and overall survival were found between groups. Conclusions: The overall results did not show that usage of different bleeding control methods can affect early or long-term outcomes. ***Level of Evidence III; retrospective study.***

Keywords: Renal cell carcinoma; Embolization; Hemostasis; Treatment outcome.

RESUMO

Objetivo: Este artigo compara vários métodos de controle de sangramento, sua influência no resultado e sobrevida após procedimentos de descompressão para metástases espinhais de carcinoma de células renais (MRCC). Métodos: Estudo retrospectivo. Todos os pacientes foram submetidos a procedimentos de descompressão paliativa. Comparamos três grupos de pacientes estratificados por métodos de controle de sangramento. O primeiro grupo (EMB) incluiu 22 pacientes submetidos à embolização pré-operatória de um tumor. O segundo grupo (HEM) consistiu em 20 pacientes tratados cirurgicamente usando agentes hemostáticos locais intra operatórios. No terceiro grupo (COMBI), 15 pacientes foram tratados com uma combinação de métodos. Resultados: A perda de sangue intra-operatória média para o grupo EMB foi ligeiramente inferior à média nos grupos HEM e COMBI ,sem diferenças significativas. A perda de drenagem pós-operatória nos grupos HEM e COMBI foi significativamente menor do que no grupo EMB. A taxa de complicações (infecções, hematomas, déficit neurológico) foi quase igual em todos os grupos. Não houve diferença estatisticamente significativa na recorrência local do tumor e a sobrevida global foi encontrada entre os grupos. Conclusões: Os resultados globais não mostraram que o uso de diferentes métodos de controle de sangramento pode afetar os resultados precoce e de longo prazo. ***Nível de Evidência III; Estudo retrospectivo.***

Descritores: *Carcinoma de células renais; Embolização; Hemostasia; Resultado do tratamento.*

RESUMEN

Objetivo: Este estudio compara varios métodos de control de sangrado, su influencia en el resultado y la supervivencia después de los procedimientos de descompresión de metástasis espinal de carcinoma de células renales (CCR). Métodos: Estudio retrospectivo en el que todos los pacientes fueron sometidos a procedimientos de descompresión paliativa. Comparamos 3 grupos de pacientes estratificados por métodos de control de sangrado. El primer grupo (EMB) incluyó a 22 pacientes sometidos a embolización preoperatoria de un tumor. El segundo grupo (HEM) consistió en 20 pacientes, tratados quirúrgicamente con agentes hemostáticos locales intraoperatorios. En el tercer grupo (COMBI) 15 pacientes fueron tratados con una combinación de métodos. Resultados: La pérdida de sangre intraoperatoria promedio en el grupo EMB fue ligeramente menor que el promedio en los grupos HEM y COMBI, pero sin diferencias significativas. La pérdida por drenaje posoperatorio en los grupos HEM y COMBI fue significativamente menor que en el grupo EMB. La tasa de complicaciones (infecciones, hematomas, déficit neurológico) fue prácticamente igual en todos los grupos. No se encontraron diferencias estadísticamente significativas en la recurrencia local del tumor y la supervivencia general entre los grupos. Conclusiones: Los resultados generales no mostraron que el uso de diferentes métodos de control de sangrado pueda afectar los resultados a corto o largo plazo. ***Nivel de Evidencia III; Estudio retrospectivo.***

Descriptores: *Carcinoma de células renales; Embolización; Hemostasis; Resultado del tratamiento.*

Study conducted at the R.R.Vreden Russian Research Institute of Traumatology and Orthopedics, Saint-Petersburg, Russia.
Correspondence: Spine Surgery and Oncology Service, R. R. Vreden Russian Research Institute of Traumatology and Orthopedics Saint-Petersburg, st. A. Baykova, 8, Russia, 195427. +7 812 670 95 52. n.zaborovskii@yandex.ru

http://dx.doi.org/10.1590/S1808-185120181703193262

Received on 03/21/2018, accepted on 07/25/2018

INTRODUCTION

Metastatic bone tumors in the spine are painful and debilitating, challenging to treat and often require surgery. Surgical intervention aims at decompression, either by direct removal of tumor tissue or indirectly, by palliative posterior laminectomy, and is intended to preserve or regain neurological functions, restore or improve walking, and relieve pain.[1]

Spinal metastases originating from renal cell carcinoma (MRCC) are difficult to manage due to profuse intraoperative bleeding, which is difficult to control. The range of techniques, available for sparing blood in spine procedures, is very wide and the variety of concepts is large.[2,3] The benefit of preoperative embolization in spinal metastases surgery has been reported in previous studies.[4–6] On the other hand, the use of local hemostatic agents is safe and beneficial for the control of bleeding during spine surgery.[7–9]

This report describes the comparison of various MRCC bleeding control methods, and their influence on outcome and survival after decompression procedures.

METHODS

The study was approved by the research ethics committee.
All patients gave the informed consent prior to being included in the study.

A retrospective analysis was conducted of 57 cases involving patients treated during the period 2005 to 2014. The inclusion criteria were: (1) single-level tumor lesions, (2) patients with extension of tumor around the spinal cord (Wenstein-Boriani-Biagini layer D, Bilsky Epidural Spinal Cord Compression scale >1B), (3) hypervascularity of tumor, (4) posterior decompression surgery. Exclusion criteria were: previous operations, preoperative anemia (<12 g/dL), long postembolization period (>3 days), and coagulopathy. All patients received a radiological work-up with plain films, CT, MRI and additional diagnostic angiography. The tumor lesions were mainly located in the thoracic spine (n=39; 68.4%), with a smaller percentage of tumors in lumbar spine (n=18; 31.6%). All 57 patients were stratified by methods of bleeding control into 3 groups. (Table 1) Preoperative embolization was performed in 22 cases (EMB group). In the period 2005-2009 we did not have modern LHA in our practice. Twenty patients were treated surgically using intraoperative LHA for economic reasons (patients have to pay for embolization), or contraindications for embolization, or patient's refusal to undergo the embolization procedure (HEM group). A combination of methods (embolization and hemostatic agents) was used in 15 cases (COMBI group).

Surgical strategy

The indications for palliative surgical treatment of spinal metastases were neurological deficit, spinal neoplastic instability and the presence of visceral metastases. These indications were true for patients with poor life expectancy, for whom a likelihood of improving the quality of life was expected. All patients were operated by the same team of spine surgeons using standardized techniques. Palliative management included tumor excision in a piecemeal fashion (intralesional excision) by wide laminectomy and spinal instrumentation using the posterior approach. Opening of tumor lesion as late as possible is the most important point in the surgical strategy for hypervascular tumor decompression. Decompression was started via facetectomy at the levels above and below the affected vertebra. Laminectomy (same level and level above) was performed by rongeurs. After visualization of the nerve roots, pedicle was removed from less affected side than from the other side. Decompression of ventral part of neural elements (spinal cord, dural sac) was achieved by bent curettes. Circular decompression should be completed as fast as possible. After tumor tissue removal, tamponade of the cavity provided hemostasis.

Methods of bleeding control

General measures used to minimize blood loss included the assessment and correction of coagulopathy, hypotensive anesthesia, antifibrinolytic drugs, and the use of bipolar electrocautery, Cell Saver, oxidized cellulose and bone wax.

Diagnostic angiography and embolization under local anesthesia were performed using the femoral approach. Selective catheterization of tumor feeding arteries was performed, and angiographic images were obtained. Tumor vascularity was analyzed by the severity of tumor blush and venous drainage, and evaluated by the interventional radiologist in 4 grades (not hypervascular, mild, moderate, severe). Patients with moderate and severe hypervascularity of tumor were included in the study. We did not perform embolization if any anterior spinal arteries were detected. Gelatin sponge particles were used as embolic material. Embolization was evaluated as "complete" when tumor blush was decreased by more

Table 1. Patients' demographic data.

	EMB (n = 22)	HEM (n = 20)	COMBI (n = 15)	EMB vs. HEM	HEM vs. COMBI	COMBI vs. EMB
Median age, y.o. (range)	50 (20-71)	55 (36-74)	58 (48-73)	0.273	0.423	0.181
Male, n (%)	17 (77.3%)	16 (80%)	7 (46.7%)	0.629	0.071	0.082
Tumor location						
Thoracic spine, n (%)	17 (77.3%)	15 (75%)	8 (53.3%)	0.453	0.282	0.164
Lumbar spine, n (%)	5 (22.7%)	5 (25%)	7 (46.7%)	0.798	0.282	0.164
General condition						
Karnofsky performance status (10-40%), n (%)	3 (13.6%)	2 (10%)	2 (13.3%)	0.345	0.278	0.645
Presence of visceral metastases, n (%)	8 (36.4%)	12 (60%)	7 (46.7%)	0.059	0.506	0.505
Neurological deficit, n (%)	21 (95.5%)	16 (80%)	15 (100%)	0.174	0.118	0.187
Spinal instability (SINS >13 scores), n (%)	20 (90.1%)	14 (70%)	13 (86.7%)	0.122	0.419	0.754
Tumor vascularity and degree of embolization						
Grade 0-1	0	0	0	-	-	-
Grade 2 (moderate)	5	6	4	0.729	0.643	0.456
partial embolization	2	-	0	-	-	0.504
complete embolization	3	-	4	-	-	0.408
Grade 3 (severe)	17	14	11	0.729	0.267	0.425
partial embolization	7	-	5	-	-	0.289
complete embolization	10	-	6	-	-	0.356

EMB –group with embolization, HEM – group with local hemostatic agents usage, COMBI – group with embolization and local hemostatic agents usage; EMB vs. HEM, HEM vs. COMBI, COMBI vs. EMB – indicates p value between groups.

than 75%, otherwise it was evaluated as "partial". Most patients who underwent embolization were operated on the next day (n = 26), and a smaller number in 2 days (n = 6).

Local hemostatic agents were based on a gelatin-thrombin matrix. If profuse bleeding started, a hemostatic was applied to this area. After application of the hemostatic, surgery was continued on another side of the surgical field. If the profuse bleeding did not stop, the hemostatic was reapplied with tamponade. Once the bleeding was under control, it was possible to continue operating on the initial field.

Clinical data

The parameters evaluated were blood loss volume, drainage loss, possible complications, hospitalization time, and survival. Estimated intraoperative blood loss was obtained from anesthesiologists' records of the amount of blood collected and calculated in the suction container. 100/250 ml Redon-Drainage was used to collect drainage blood loss over 1 week, as standard protocol. Drainage loss volume was recorded daily in the patient's chart. All adverse events during hospitalization were recorded. After hospitalization, patients were observed by oncologists. Overall survival was counted from the end of hospitalization to death.

Statistical Analysis

Statistical analyses were provided by R version 3.3.2 (R Foundation for Statistical Computing). For categorical variables, cross-tabulations were generated and Pearson's Chi-square test with Yates' continuity correction. The Mann–Whitney U test was used to compare continuous variables between groups. The Kaplan-Meier analysis method estimated postoperative survival, and survival curves using the log-rank test. A p-value less than 0.05 was considered statistically significant.

RESULTS

Differences between 3 pairs of groups (EMB vs. HEM, HEM vs. COMBI, COMBI vs. EMB) were not found preoperatively. The mean intraoperative blood loss for embolized patients was 1129 (range 400-1700) mL, which was slightly less than the mean in groups with LHA - 1235 (range 600-2400) mL and combination of methods - 1190 (range 700-1650) mL. Nevertheless, no statistically significant differences were found in blood loss volume between groups. The postoperative drainage loss in the HEM group was 474 (range 190-970) mL, and in the COMBI group it was 469 (range 200-620) mL, which was significantly less than that of the EMB group, with 939 (range 370-1450) mL. (Table 2)

The complication rate with reoperation required was nearly equal in all groups. There were 9 hematomas and 7 wound infections, with most of the infections developing from the wound hematomas. Neurological status was evaluated based on the Frankel grade. Postoperatively (at the end of hospital stay), a majority of patients demonstrated improvement in neurological status by at least one Frankel grade (EMB 71.4% (15/21) patients, HEM 68.8% (11/16) patients, COMBI 53.3% (8/15) patients). 13.5 % (7/ 57) of patients had neurological deterioration caused by operation or the embolization procedure. For example, in the EMB group, one patient developed irreversible paraplegia after embolization. Neurological deterioration (Frankel D to A) was evaluated as rapid decompensation of tumor spinal cord compression. However, after surgery the patient did not improve neurological status. Spinal cord ischemia was diagnosed by MRI. Although preoperative embolization is a relatively safe procedure, there is still a risk of spinal cord ischemia. The mean hospitalization time was significantly shorter in groups with LHA (HEM) compared to groups with embolization (EMB, COMBI).

Secondary neurological deficit following local recurrence of spinal tumor was not associated with embolization or LHA usage, or a combination of the two. The median overall survival was 15.7 (range 4-44) months in EMB group, compared to 19 (range 9-29) months in the HEM group and 14.7 (range 2-25) months in the COMBI group. No statistically significant difference in survival was found between groups by the Log-rank test (p = 0.360).

DISCUSSION

MRCC are difficult to manage. This type of lesion tends to be large, highly destructive, and more resistant to systemic and radiation therapy than other metastases, resulting in pathological fractures and spinal cord compression that severely compromises the performance status and quality of life of patients. Profuse intraoperative bleeding, caused by metastases of MRCC, is one of the challenges of spine surgery. The majority of spine surgeons believe that embolization of tumor vessels reduces blood loss, lowers surgical risk, and enables more precise dissection and more extensive resection of the lesion.[10,11] Kobayashi et al. showed that not only embolization, but also the invasiveness of the surgery play an important role in operative blood loss in spinal tumor surgery.[12] Therefore, we evaluated patients who underwent decompression using the posterior approach.

Some studies describe intraoperative blood loss after embolization and decompression. Guzman et al. showed average blood volume in suction, for patients with embolization in a group with renal cell carcinoma, of 2400 mL.[11] Kato et al. reported that intraoperative blood loss after preoperative embolization was twice less than in group without embolization.[13] Schmidt et al. concluded that for patients with tumor reduction, who underwent preoperative embolization, the mean blood loss was 1867 ml.[14] In a recent study, Clausen et al. concluded that blood loss differences between patients who received embolization and those who did not were significant, but too small to be clinically important.[15]

We found no statistically significant association between methods of bleeding control (embolization or the application of local hemostatic agents). Therefore, we believe indications for embolization of MRCC before posterior decompression surgery could be reconsidered in the future, as modern hemostatics provide adequate control of hemorrhage in palliative management. This will result in

Table 2. Postoperative data.

	EMB	HEM	COMBI	EMB vs. HEM	HEM vs. COMBI	COMBI vs. EMB
Blood loss (mL)	1129 ± 349	1235 ± 603	1190 ± 358	0.058	0.189	0.563
Drainage loss (mL)	939 ± 354	464 ± 127	469 ± 197	0.011*	0.564	0.045*
Hematoma, n of reOp	5	2	2	0.414	0.356	0.676
Infection, n of reOp	3	2	2	0.467	0.821	0.987
Neurological deficit after embolization, n	1	0	1	0.999	0.428	0.999
Neurological deficit after operation, n	2	2	1	0.978	0.981	0.956
Improvement in neurological status after surgery, n	15	11	8	0.786	0.472	0.378
Hospital stay, days	33.4 ± 9.8	26.3 ± 6.3	31.5 ± 8.4	0.031*	0.042*	0.368
Local recurrence at outcome, n	2	1	2	0.672	0.564	0.625
Neurological deterioration at outcome, n	2	2	2	0.563	0.452	0.489

EMB –group with embolization, HEM – group with local hemostatic agents usage, COMBI – group with embolization and local hemostatic agents usage; EMB vs. HEM, HEM vs. COMBI, COMBI vs. EMB – indicates p-value between; In graph «Improvement in neurological status after surgery» values were compared with numbers of preoperative neurological deficit; * - significant difference between groups.

decreased surgical risks for oncology patients due to rejection from additional invasive procedures.

Accumulation of blood in the wound carries a risk of infectious complications.[16,17] The role of local hemostatics in drainage loss after spine tumor surgery has not yet been described. Interestingly, it was proved that drainage loss was significantly lower in the HEM group where local hemostatics were used intraoperatively. Better local hemostasis after hemostatics may be a possible explanation. However, definitive study in this area is needed. Despite hemostatic advantages, wound hematomas may develop. There were cases of revision in these series of patients. However, the number of wound hematomas was not affected by the bleeding control method. We believe that hematomas are caused by development of cavities after paravertebral tumor tissue resection.

The most recent clinical studies have not described any cases of neurological complications.[18,19] Furthermore, some experimental studies showed no complications after ligation up to 3 or 5 pairs of arteries that may supply the spinal cord arteries.[20,21] There were 2 (3.7%) cases of neurological deficit after preoperative embolization in our study; one case of irreversible paraplegia and another with temporary loss of function.

The hospitalization times of the embolized group were longer due to a longer preoperative period. This was mainly influenced by the waiting time for angiography. The length of the postoperative period was similar in all groups.

At present, the goal for every patient with metastatic renal cell carcinoma is to maximize overall therapeutic benefits, which means delaying, for as long as possible, a lethal burden of disease while maximizing the patient's quality of life and convenience.[22] Tumor cord compression significantly diminishes the quality of life of cancer patients, creating pain, medical problems such as urogenital infection, pneumonia, and thrombosis. Decompression surgery showed restoration of neurological function. Jackson et al. described survival of 14.1 months after different types of decompression in spinal metastatic renal cell tumor.[23] Prabhu et al. reported that 37% of patients survived a mean 11.5 months (range 8.7–21.4 months) after surgery.[24] Quraishi et al. also found median survival of 12.3 month.[25] Our average overall survival is slightly longer compared to the results of previous studies. The choice of bleeding control methods did not affect survival in our study.

One of the limitations to the current research is that it was a retrospective analysis of patients' records. Another restriction was the small number of patients evaluated. On the other hand, many studies with relatively small cohorts have been evaluating preoperative embolization since the 1970s. This large volume of information should be associated in meta-analyses for the evaluation of different types of MRCC management, which seems to be possible due to standardized techniques in spine surgery.

CONCLUSIONS

Our research has proven no significant difference between preoperative embolization of tumor and local hemostatic agents usage in the intraoperative or early postoperative periods, or in long-term outcome. Therefore, we do not see any reason to use expensive and relatively risky procedures of embolization in palliative management of severe hypervascularity renal cell carcinoma metastasis of spine.

ACKNOWLEDGMENTS

We are indebted to Elena Zavialova and Christopher Downey for their valuable insights and careful reviews of this manuscript.

All authors declare no potential conflict of interest related to this article.

CONTRIBUTION OF THE AUTHORS: NZ (0000-0003-4562-8160)* and DP (0000-0001-5765-3158)* - active participation in the discussion of results; DM (0000-0002-4747-0806)*, SM (0000-0003-1085-9890)* and OS (0000-0002-3586-0487)* review and approval of the final version of the work. *ORCID (Open Researcher and Contributor ID).

REFERENCES

1. Sciubba DM, Petteys RJ, Dekutoski MB, Fisher CG, Fehlings MG, Ondra SL et al. Diagnosis and management of metastatic spine disease. A review. J Neurosurg Spine. 2010;13(1):94-108.
2. Szpalski M, Gunzburg R, Sztern B. An overview of blood-sparing techniques used in spine surgery during the perioperative period. Eur Spine J. 2005;13(Suppl 1):S18-27.
3. Chivukula S, Weiner G, Engh J. The early days of hemostasis in neurosurgery. Neurosurg Focus. 2014;36(4):E5.
4. Wilson MA, Cooke DL, Ghodke B, Mirza SK. Retrospective analysis of preoperative embolization of spinal tumors. AJNR Am J Neuroradiol. 2010;31(4):656-60.
5. Thiex R, Harris MB, Sides C, Bono CM, Frerichs KU. The role of preoperative transarterial embolization in spinal tumors. A large single-center experience. Spine J. 2013;13(2):141-9.
6. Pikis S, Itshayek E, Barzilay Y, Hasharoni A, Kaplan L, Gomori M et al. Preoperative embolization of hypervascular spinal tumors: current practice and center experience. Neurol Res. 2014;36(6):502-9.
7. Renkens KL, Payner TD, Leipzig TJ, Feuer H, Morone MA, Koers JM et al. A multicenter, prospective, randomized trial evaluating a new hemostatic agent for spinal surgery. Spine (Phila Pa 1976). 2001;26(15):1645-50.
8. Schonauer C, Tessitore E, Moraci A, Barbagallo G, Albanese V. The use of local agents: bone wax, gelatin, collagen, oxidized cellulose. Eur Spine J. 2004;13(Suppl 1):S89-96.
9. Sabel M, Stummer W. The use of local agents: Surgicel and Surgifoam. Eur Spine J. 2004;13 (Suppl 1):S97-101.
10. Olerud C, Jónsson H, Löfberg AM, Lörelius LE, Sjöström L. Embolization of spinal metastases reduces peroperative blood loss. 21 patients operated on for renal cell carcinoma. Acta Orthop Scand. 1993;64(1):9-12.
11. Guzman R, Dubach-Schwizer S, Heini P, Lovblad KO, Kalbermatten D, Schroth G et al. Preoperative transarterial embolization of vertebral metastases. Eur Spine J. 2005;14(3):263-8.
12. Kobayashi K, Ozkan E, Tam A, Ensor J, Wallace MJ, Gupta S. Preoperative embolization of spinal tumors: variables affecting intraoperative blood loss after embolization. Acta radiol. 2012;53(8):935-42.
13. Kato S, Murakami H, Minami T, Demura S, Yoshioka K, Matsui O et al. Preoperative embolization significantly decreases intraoperative blood loss during palliative surgery for spinal metastasis. Orthopedics. 2012;35(9):e1389-95.
14. Schmidt R, Rupp-Heim G, Dammann F, Ulrich C, Nothwang J. Surgical therapy of vertebral metastases. Are there predictive parameters for intraoperative excessive blood loss despite preoperative embolization? Tumori. 2011;97(1):66-73.
15. Clausen C, Dahl B, Frevert SC, Hansen LV, Nielsen MB, Lönn L. Preoperative embolization in surgical treatment of spinal metastases: single-blind, randomized controlled clinical trial of efficacy in decreasing intraoperative blood loss. J Vasc Interv Radiol. 2015;26(3):402-12.
16. Perry JW, Montgomerie JZ, Swank S, Gilmore DS, Maeder K. Wound Infections Following Spinal Fusion with Posterior Segmental Spinal Instrumentation. Clin Infect Dis. 1997;24(4):558-61.
17. Xing D, Ma J-X, Ma X-L, Song DH, Wang J, Chen Y et al. A methodological, systematic review of evidence-based independent risk factors for surgical site infections after spinal surgery. Eur Spine J. 2013;22(3):605-15.
18. Kato S, Hozumi T, Takaki Y, Yamakawa K, Goto T, Kondo T. Optimal schedule of preoperative embolization for spinal metastasis surgery. Spine (Phila Pa 1976). 2013;38(22):1964-9.
19. Cernoch P, Hechelhammer L, von Hessling A, Spross C, Erhardt J, Jost B et al. Preoperative embolisation of spinal metastasis: technique, complication rate and outcome - clinical experience. Int Orthop. 2015;39(7):1399-404.
20. Fujimaki Y, Kawahara N, Tomita K, Murakami H, Ueda Y. How many ligations of bilateral segmental arteries cause ischemic spinal cord dysfunction? An experimental study using a dog model. Spine (Phila Pa 1976). 2006;31(21):E781-9.
21. Ueda Y, Kawahara N, Tomita K, Kobayashi T, Murakami H, Nambu K. Influence on spinal cord blood flow and function by interruption of bilateral segmental arteries at up to three levels: experimental study in dogs. Spine (Phila Pa 1976). 2005;30(20):2239-43.
22. Rini BI, Campbell SC, Escudier B. Renal cell carcinoma. Lancet. 2009;373(9669):1119-32.
23. Jackson RJ, Gokaslan ZL, Loh SC. Metastatic renal cell carcinoma of the spine: surgical treatment and results. J Neurosurg Spine. 2001;94(1 Suppl):18-24.
24. Prabhu VC, Bilsky MH, Jambhekar K, Panageas KS, Boland PJ, Lis E et al. Results of preoperative embolization for metastatic spinal neoplasms. J Neurosurg. 2003;98(2 Suppl):156-64.
25. Quraishi NA, Purushothamdas S, Manoharan SR, Arealis G, Lenthall R, Grevitt MP. Outcome of embolised vascular metastatic renal cell tumours causing spinal cord compression. Eur Spine J. 2013;22(Suppl 1):27-32.

ENERGY SUPPLY AND DEMAND IN THE INTERVERTEBRAL DISC

FORNECIMENTO E DEMANDA DE ENERGIA NO DISCO INTERVERTEBRAL

SUMINISTRO DE ENERGÍA Y DEMANDA EN EL DISCO INTERVERTEBRAL

Liudmila Andreevna Bardonova[1], Omar Sheikh[2], Irina Olegovna Malova[1], Vladimir Alexeevich Sorokovikov[3], Vadim Anatolyevich Byvaltsev[1]

1. Neurosurgery Department, Irkutsk State Medical University, Ministry of Health, 1 Krasnogo Vosstaniya St., Irkutsk, Russia.
2. School of Chemical, Biological, and Environmental Engineering, Oregon State University, 1500 SW Jefferson St., Corvallis, OR, 97331, USA.
3. Irkutsk Scientific Center of Surgery and Traumatology, Irkutsk, Russia.

ABSTRACT

The intervertebral disc (IVD) is one of the parts of the body most commonly affected by disease, and it is only recently that we have come closer to understanding the reasons for its degeneration, in which nutrient supply plays a crucial role. In this literature review, we discuss the basic principles and characteristics of energy supply and demand to the IVD. Specifically, we review how different metabolites influence IVD cell activity, the effects of mechanical loading on IVD cell metabolism, and differences in energy metabolism of the annulus fibrous and nucleus pulposus cell phenotypes. Determining the factors that influence nutrient supply and demand in the IVD will enhance our understanding of the IVD pathology, and help to elucidate new therapeutic targets for IVD degeneration treatment.

Keywords: Intervertebral disc; Nucleus pulposus; Annulus fibrosus; Energy metabolism; Cell therapy.

RESUMO

O disco intervertebral (IVD) é uma das partes mais comuns do corpo e apenas recentemente nos aproximamos de compreender as razões da sua degeneração, em que o suprimento de nutrientes desempenha um papel crucial. Nesta revisão da literatura, discutimos os princípios básicos e as nuances do fornecimento e da demanda de energia para o IVD. Especificamente, analisamos como os diferentes metabólitos influenciam na atividade das células IVD, os efeitos da carga mecânica no metabolismo das células IVD, a diferença no metabolismo energético dos fenótipos das células fibrosas e do núcleo do pulposus anelar. A determinação de fatores que influenciam o suprimento e a demanda de nutrientes no IVD aumentará nossa compreensão da patologia IVD e ajudará a elucidar novos alvos terapêuticos para o tratamento da degeneração IVD.

Descritores: *Disco intervertebral; Núcleo pulposo; Anel fibroso; Metabolismo energético; Terapia celular.*

RESUMEN

El disco intervertebral (IVD, por sus siglas en inglés) es una de las partes más comúnmente enfermas del cuerpo y solo recientemente nos acercamos a la comprensión de los motivos de su degeneración, de los cuales el suministro de nutrientes juega un papel crucial. En esta revisión de la literatura discutimos los principios básicos y los matices de la oferta y demanda de energía para el IVD. Específicamente, revisamos cómo los diferentes metabolitos influyen en la actividad de las células IVD, los efectos de la carga mecánica sobre el metabolismo de las células IVD y las diferencias en el metabolismo energético de los fenotipos de las células del anillo fibroso y el núcleo pulposo. La determinación de los factores que influyen en la oferta y demanda de nutrientes en el IVD mejorará nuestra comprensión de la patología IVD y ayudará a dilucidar nuevos objetivos terapéuticos para el tratamiento de la degeneración IVD.

Descriptores: *Disco intervertebral; Núcleo pulposo; Anillo fibroso; Metabolismo energético; Terapia celular.*

INTRODUCTION

The intervertebral disc (IVD) is one of the parts of the body most commonly affected by disease, and it is only recently that we have come closer to understanding the reasons for its degeneration, in which nutrient supply plays a crucial role. The IVD consists of three primary structures: the nucleus pulposus (NP), which is surrounded radially by the annulus fibrosus (AF), and the cartilaginous endplates (CEP), which attach the disc to the adjoining vertebral bodies. The healthy adult IVD is practically devoid of blood vessels; they are found only in the outer lamellae of the AF.[1] Nutrients are therefore heavily reliant on diffusive and convective means of transport through disc tissue, with diffusive mechanisms being dominant.[2-4] The endplates have been shown to be responsible for the majority of nutrient transport into the disc,[5] though there is some supply originating radially through the AF.[1] Due to normal aging, the morphology and molecular biology of the disc changes, diminishing its ability to provide critical functions.[6,7] Within the first decades of life, the disc loses most of its blood supply, resulting in nutrient deficiency. Later, calcification of the CEP leads to the loss of its permeability.[8,9] This decreases nutrient diffusion, leading to a decrease in glucose and oxygen concentrations and an increase in metabolic waste concentration. The resulting nutrient deprivation and waste product accumulation can lead to cell death and senescence.[10] Despite making up less than 1% of the volume of the entire disc, cells are critical for maintaining disc health and function.[11] Disc cells interact with each other and with the surrounding extracellular matrix, which is constantly being destroyed and rebuilt by the cells as part of the normal tissue repair process.[12] Cell death in the IVD

Study conducted at the Irkutsk State Medical University, Irkutsk, Russia.
Correspondence: PO, Russia. Box number 62. 664082. byval75vadim@yandex.ru

http://dx.doi.org/10.1590/S1808-185120181703193837

Received on 04/04/2018, accepted on 07/25/2018

leads to a degradation of the tissue without any ability to repair itself. The aim of this mini-review is to summarize the current literature on IVD nutrient supply and demand. Studying factors that influence nutrient supply and demand in the IVD will enhance our understanding of IVD pathology and elucidate new targets for IVD therapies.

Metabolite Influences on IVD Cell Activity

Regular glucose supply is critical for IVD cell viability, optimal homeostasis and matrix synthesis. There are several studies that examine the influence of glucose concentration on the proliferation and survival of IVD cells. Cell viability decreases with when glucose concentration is sustained below 0.5 mM for more than three days.[13] According to another study,[14] cells begin to die when glucose concentration is sustained below 0.2 mM for 24 hours. It has been shown that the pH of healthy human discs ranges from 7.1 to 7.4,[15] with a lower pH in the central part of the disc due to the higher lactic acid accumulation.[16] Furthermore, the pH level also harms the condition of the IVD cells: even with an adequate glucose level, the acidic environment adversely affects the viability and proliferation of the cells.[17,18] During degeneration, the pH decreases to values of 6.5 to 6.8 in mildly degenerated discs and even to 5.7 in severely degenerated discs.[19] In vivo, O2 levels are extremely variable, ranging from 1% to 5% within the IVD.[20]

It has been demonstrated that IVD cells could survive at low oxygen concentrations without a significant loss of cell viability.[17,21] However, the oxygen consumption rate of degenerated human IVD cells was three to five times higher than that of healthy cells under identical cell culture conditions.[22] Furthermore, the oxygen consumption rate of degenerated IVD cells was sensitive to glucose levels. However, this study has an important limitation: IVD cells change their phenotype during expansion,[23] and monolayer expansion induces oxidative metabolism and reactive oxygen species in chondrocytes.[24]

It is widely supported in the literature that an acidic pH level significantly decreases the rates of glycolysis and oxygen uptake, and as a result, the production of ATP. Proper biosynthesis of extracellular matrix in the IVD requires an extensive amount of ATP to be produced[25] especially proteoglycan biosynthesis, which uses ATP as an energy source and building block.[26] Extracellular ATP treatment promoted extracellular matrix accumulation by both cell types and significantly increased intracellular ATP content in NP cells in 3D culture.[27] In addition, in vitro studies have shown that the synthetic activity of disc cells, i.e. the rate of production of the extracellular matrix depends on the concentration of extracellular oxygen and pH.

The balance between the rate of diffusion of dissolved substances through the matrix and the rate of their consumption by cells determines the concentration gradient within the disc. The concentration gradient in the different regions of disc (i.e. local gradient) has a strong influence on metabolic rates, matrix production and cell survival and hence on the development of disc degeneration. In the disc model proposed by Shirazi-Adl et al.,[28] the zone with the lowest concentrations of oxygen and glucose and maximum level of lactic acid was located in the centre of NP at the disc mid-height plane, which is furthest away from the supply/uptake sources. In this zone, the cells are located 7-8 mm from the nearest blood vessel.[5] Thus, the disc central part is likely to be the first part to degenerate due to the nutrient-poor conditions.

Recent studies have demonstrated that NP cells respond to low oxygen concentration and nutrient deprivation by upregulating the synthesis of hypoxia-inducible factor (HIF) proteins, particularly HIF-1 and 2. HIF-1 is known to activate many downstream signals involved in anaerobic metabolism, control of intracellular pH, DNA damage responses and proliferation, and plays an important role in cell adaption, survival, and overcoming the stressful conditions of hypoxia.[29-31] HIF-1α has been demonstrated in the NP of both normal and degenerated human IVD[32,33] and hypoxia responsive glucose transporters GLUT-1, 3, 9 are expressed in NP cells, but not AF and CEP cells.[33] Furthermore, activation of HIF-1 in degenerated IVD increases expression hypoxia responsive glucose transporters GLUT-1, 3, 9 in NP cells. This study shows that NP and AF and CEP cells have different GLUT expression. Based on what is known, HIF-1 and HIF-2 may also serve to enhance NP cell survival in the specialized microenvironment of the IVD.[30-34]

Effects of Mechanical Loading on the Energy Metabolism of IVD Cells

Mechanical loading significantly changes water content, chemical composition and nutritional levels in the IVD. The intradiscal pressure varies during normal daily activity, but the effects of abnormal mechanical loading, such as mechanical stresses, hyperflexion and swelling pressure, may lead to injury and degeneration process in IVD. The effects of mechanical loading are dependent on level, loading frequency and permeability capacity of CEP.[35] It also has been shown that mechanical loading increases glucose and oxygen consumption rates.[36,37] In a study performed by Fernando et al.,[38] there were no differences in glucose consumption and lactate production of AF cells between the static and dynamic compression groups. Dynamic compression, static compression and vibratory loading all promote ATP release from IVD cells both cell types[38,39]. Therefore, mechanical loading influences the biological function of the IVD by regulating intra- and extra- cellular ATP metabolism. In general, physiological dynamic loading increases oxygen concentration, reduces lactate concentration, and promotes oxygen consumption and lactate production by IVD cells.

Differences in Energy Metabolism of the Annulus Fibrosus and Nucleus Pulposus Cells

Studies on the metabolism of the IVD suggest that AF and NP are metabolically and bioenergetically different tissues.[22,37,38] These differences indicate that the main pathway of energy production differs between these types of cells. NP cells consume less glucose and produce much more ATP, which suggests the likely production of ATP by aerobic respiration in addition to glycolysis.[40] It has been suggested that these differences in cell phenotypes may be attributed to differences in embryonic origins of the tissue types.[41] The nucleus pulposus is derived from the notochord, whereas AF and CEP arise from the mesenchyme.[42] The nucleus pulposus contains notochordal cells at early ages, then these cells disappear with age.[43] The higher lactate production and oxygen rate consumption of the human NP cells indicate that NP cells have a more active metabolic phenotype.

Nutrient Considerations in IVD Therapy

Currently, treatment strategies for IVD degeneration fail to address the nutrient transport problem faced by cells. The problem of nutrient deprivation can be well illustrated by the significantly higher incidence of smokers with disc degeneration disease.[44] When confronted with tobacco smoke, human disc cells undergo adverse morphologic changes that suggest a nutrient-deprived state.[45] One promising technique is that of Hoyland, which utilizes differentiated bone marrow and adipose mesenchymal stem cells to treat disc degeneration.[45] However, in a nutrient-starved environment, the transplantation of more cells will further reduce the availability of nutrients. In order for therapies to address this starvation, the nutrient transport process must be considered.[46] Motaghinasab et al. developed a computational model to predict the penetration profile of solutes. In line with the avascular nature of discs, solute concentrations fall dangerously below healthy levels far from the blood supply sources.[46] Current strategies seek to address this critical nutrient transport deficit through mechanical and biological means such as spinal traction[4,47] and enzymatic permeabilization[48] respectively. Kuo et al. explored the effect of spinal traction on molecular transportation in a simulated porcine IVD degeneration model. Though this study, they suggested that traction treatment provides enhancements for nutrition supply. Other studies have offered mixed conclusions about its effectiveness. In response to these challenges, Giers et al. created a porcine model of IVD degeneration to explore biomechanical and physiological factors guiding nutrient transport. Based on the mass transport of dyes, diffusion was determined to be the main transport mechanism. The use of mechanical loading, which includes strategies like spinal traction, was judged as having conflicting benefits for nutrient transportation.[4] Based on

these efforts, spinal traction does not appear to address nutrient deprivation, requiring innovative new therapies for degeneration.[49] Work by Fields et al. explored how changing CEP permeability would influence nutrient diffusion – though nutrient delivery was not clearly improved, this study established a clear correlation.[50] Therefore, this strategy offers a promising new direction for addressing nutrient transport deficits in IVD.

CONCLUSION

It should be emphasized that to date, there is no direct evidence of the sequence of these phenomena, evidence of the primary disruption of the IVD trophism and the secondary nature of its degeneration. Further study of the mechanisms determining homeostasis in IVD in normal and pathological tissues is still relevant, since many researchers are already considering the restoration or maintenance of adequate intradiscal metabolism as the determining curative direction for preventing degenerative changes in the IVD.

ACKNOWLEDGEMENTS

LAB acknowledges scholarship support #SP-2545.2018.4.

All authors declare no potential conflict of interest related to this article.

CONTRIBUTION OF THE AUTHORS: Each author made significant individual contributions to this manuscript. VAB (0000-0001-9340-5477)* were the main contributors in the drafting of the manuscript. LAB (0000-0001-9340-5477)*, SO (0000-0003-3352-6538)*, IOM (0000-0003-3972-8093)* and VAS (0000-0002-9008-6383)* performed the literature search and review of the manuscript and contributed to the intellectual concept of the study. *ORCID (Open Researcher and Contributor ID).

REFERENCES

1. Nerlich AG, Schaaf R, Walchli B, Boos N. Temporo-spatial distribution of blood vessels in human lumbar intervertebral discs. Eur Spine J. 2007;16(4):547-55.
2. Mauck RL, Hung CT, Ateshian GA. Modeling of neutral solute transport in a dynamically loaded porous permeable gel: implications for articular cartilage biosynthesis and tissue engineering. J Biomech Eng. 2003;125(5):602-14.
3. Gullbrand SE, Peterson J, Mastropolo R, Roberts TT, Lawrence JP, Glennon JC et al. Low rate loading-induced convection enhances net transport into the intervertebral disc in vivo. Spine J. 2015;15(5):1028-33.
4. Giers MB, Munter BT, Eyster KJ, Ide GD, Newcomb A, Lehrman JN et al. Biomechanical and Endplate Effects on Nutrient Transport in the Intervertebral Disc. World Neurosurg. 2017;99:395-402.
5. Urban JP, Smith S, Fairbank JC. Nutrition of the intervertebral disc. Spine (Phila Pa 1976). 2004;29(23):2700-9.
6. Vo NV, Hartman RA, Patil PR, Risbud MV, Kletsas D, Iatridis JC et al. Molecular mechanisms of biological aging in intervertebral discs. J Orthop Res. 2016;34(8):1289-306.
7. Li W, Wang P, Zhang Z, Wang W, Liu Y, Qi Q. MiR-184 Regulates Proliferation in Nucleus Pulposus Cells by Targeting GAS1. World Neurosurg. 2017;97:710-5.
8. Hangai M, Kaneoka K, Kuno S, Hinotsu S, Sakane M, Mamizuka N et al. Factors associated with lumbar intervertebral disc degeneration in the elderly. Spine J. 2008;8(5):732-40.
9. DeLucca JF, Cortes DH, Jacobs NT, Vresilovic EJ, Duncan RL, Elliott DM. Human cartilage endplate permeability varies with degeneration and intervertebral disc site. J Biomech. 2016;49(4):550-7.
10. Huang YC, Urban JP, Luk KD. Intervertebral disc regeneration: do nutrients lead the way? Nat Rev Rheumatol. 2014;10(9):561-6.
11. Hohaus C, Ganey TM, Minkus Y, Meisel HJ. Cell transplantation in lumbar spine disc degeneration disease. Eur Spine J. 2008;17 Suppl 4:492-503.
12. Gruber HE, Leslie K, Ingram J, Hoelscher G, Norton HJ, Hanley EN Jr. Colony formation and matrix production by human anulus cells: modulation in three-dimensional culture. Spine (Phila Pa 1976). 2004;29(13):E267-74.
13. Horner HA, Urban JP. 2001 Volvo Award Winner in Basic Science Studies: Effect of nutrient supply on the viability of cells from the nucleus pulposus of the intervertebral disc. Spine (Phila Pa 1976). 2001;26(23):2543-9.
14. Windhaber RA, Wilkins RJ, Meredith D. Functional characterisation of glucose transport in bovine articular chondrocytes. Pflugers Arch. 2003;446(5):572-7.
15. Diamant B, Karlsson J, Nachemson A. Correlation between lactate levels and pH in discs of patients with lumbar rhizopathies. Experientia. 1968;24(12):1195-6.
16. Urban JP. The role of the physicochemical environment in determining disc cell behaviour. Biochem Soc Trans. 2002;30(Pt 6):858-64.
17. Bibby SR, Jones DA, Ripley RM, Urban JP. Metabolism of the intervertebral disc: effects of low levels of oxygen, glucose, and pH on rates of energy metabolism of bovine nucleus pulposus cells. Spine (Phila Pa 1976). 2005;30(5):487-96.
18. Liang CZ, Li H, Tao YQ, Zhou XP, Yang ZR, Li FC et al. The relationship between low pH in intervertebral discs and low back pain: a systematic review. Arch Med Sci. 2012;8(6):952-6.
19. Gilbert HT, Hodson N, Baird P, Richardson SM, Hoyland JA. Acidic pH promotes intervertebral disc degeneration: Acid-sensing ion channel -3 as a potential therapeutic target. Sci Rep. 2016;6:37360.
20. Ishihara H, Urban JP. Effects of low oxygen concentrations and metabolic inhibitors on proteoglycan and protein synthesis rates in the intervertebral disc. J Orthop Res. 1999;17(6):829-35.
21. Bibby SR, Urban JP. Effect of nutrient deprivation on the viability of intervertebral disc cells. Eur Spine J. 2004;13(8):695-701.
22. Cisewski SE, Wu Y, Damon BJ, Sachs BL, Kern MJ, Yao H. Comparison of Oxygen Consumption Rates of Nondegenerate and Degenerate Human Intervertebral Disc Cells. Spine (Phila Pa 1976). 2018;43(2):E60-7.
23. Tang X, Richardson WJ, Fitch RD, Brown CR, Isaacs RE, Chen J. A new non-enzymatic method for isolating human intervertebral disc cells preserves the phenotype of nucleus pulposus cells. Cytotechnology. 2014;66(6):979-86.
24. Heywood HK, Lee DA. Monolayer expansion induces an oxidative metabolism and ROS in chondrocytes. Biochem Biophys Res Commun. 2008;373(2):224-9.
25. Wang C, Huang CY, Lin WC. Optical ATP biosensor for extracellular ATP measurement. Biosens Bioelectron. 2013;43:355-61.
26. Croucher LJ, Crawford A, Hatton PV, Russell RG, Buttle DJ. Extracellular ATP and UTP stimulate cartilage proteoglycan and collagen accumulation in bovine articular chondrocyte pellet cultures. Biochim Biophys Acta. 2000;1502(2):297-306.
27. Gonzales S, Wang C, Levene H, Cheung HS, Huang CC. ATP promotes extracellular matrix biosynthesis of intervertebral disc cells. Cell Tissue Res. 2015;359(2):635-42.
28. Shirazi-Adl A, Taheri M, Urban JP. Analysis of cell viability in intervertebral disc: Effect of endplate permeability on cell population. J Biomech. 2010;43(7):1330-6.
29. Culver C, Melvin A, Mudie S, Rocha S. HIF-1alpha depletion results in SP1-mediated cell cycle disruption and alters the cellular response to chemotherapeutic drugs. Cell Cycle. 2011;10(8):1249-60.
30. Li H, Liang CZ, Chen QX. Regulatory role of hypoxia inducible factor in the biological behavior of nucleus pulposus cells. Yonsei Med J. 2013;54(4):807-12.
31. Agrawal A, Guttapalli A, Narayan S, Albert TJ, Shapiro IM, Risbud MV. Normoxic stabilization of HIF-1alpha drives glycolytic metabolism and regulates aggrecan gene expression in nucleus pulposus cells of the rat intervertebral disk. Am J Physiol Cell Physiol. 2007;293(2):C621-31.
32. Ha KY, Koh IJ, Kirpalani PA, Kim YY, Cho YK, Khang GS et al. The expression of hypoxia inducible factor-1alpha and apoptosis in herniated discs. Spine (Phila Pa 1976). 2006;31(12):1309-13.
33. Richardson SM, Knowles R, Tyler J, Mobasheri A, Hoyland JA. Expression of glucose transporters GLUT-1, GLUT-3, GLUT-9 and HIF-1alpha in normal and degenerate human intervertebral disc. Histochem Cell Biol. 2008;129(4):503-11.
34. Risbud MV, Schipani E, Shapiro IM. Hypoxic regulation of nucleus pulposus cell survival: from niche to notch. Am J Pathol. 2010;176(4):1577-83.
35. Wu Y, Cisewski SE, Wegner N, Zhao S, Pellegrini VD Jr., Slate EH et al. Region and strain-dependent diffusivities of glucose and lactate in healthy human cartilage endplate. J Biomech. 2016;49(13):2756-62.
36. Huang CY, Gu WY. Effects of mechanical compression on metabolism and distribution of oxygen and lactate in intervertebral disc. J Biomech. 2008;41(6):1184-96.
37. Salvatierra JC, Yuan TY, Fernando H, Castillo A, Gu WY, Cheung HS et al. Difference in Energy Metabolism of Annulus Fibrosus and Nucleus Pulposus Cells of the Intervertebral Disc. Cell Mol Bioeng. 2011;4(2):302-10.
38. Fernando HN, Czamanski J, Yuan TY, Gu W, Salahadin A, Huang CY. Mechanical loading affects the energy metabolism of intervertebral disc cells. J Orthop Res. 2011;29(11):1634-41.
39. Yamazaki S, Weinhold PS, Graff RD, Tsuzaki M, Kawakami M, Minchew JT et al. Annulus cells release ATP in response to vibratory loading in vitro. J Cell Biochem. 2003;90(4):812-8.
40. Wang C, Gonzales S, Levene H, Gu W, Huang CY. Energy metabolism of intervertebral disc under mechanical loading. J Orthop Res. 2013;31(11):1733-8.
41. Pattappa G, Li Z, Peroglio M, Wismer N, Alini M, Grad S. Diversity of intervertebral disc cells: phenotype and function. J Anat. 2012;221(6):480-96.
42. Zhao CQ, Wang LM, Jiang LS, Dai LY. The cell biology of intervertebral disc aging and degeneration. Ageing Res Rev. 2007;6(3):247-61.
43. Guehring T, Wilde G, Sumner M, Grunhagen T, Karney GB, Tirlapur UK et al. Notochordal intervertebral disc cells: sensitivity to nutrient deprivation. Arthritis Rheum. 2009;60(4):1026-34.
44. Jakoi AM, Pannu G, D'Oro A, Buser Z, Pham MH, Patel NN et al. The Clinical Correlations between Diabetes, Cigarette Smoking and Obesity on Intervertebral Degenerative Disc Disease of the Lumbar Spine. Asian Spine J. 2017;11(3):337-47.
45. Hoyland JA, Clarke L, Hodgkinson T, Richardson SM. Mesenchymal Stem Cell Based Therapies for Disc Repair/Regeneration. Global Spine Journal. 2016;6(1_suppl):s-0036-1582585.
46. Motaghinasab S, Shirazi-Adl A, Urban JP, Parnianpour M. Computational pharmacokinetics of solute penetration into human intervertebral discs - effects of endplate permeability, solute molecular weight and disc size. J Biomech. 2012;45(13):2195-202.
47. Kuo YW, Hsu YC, Chuang IT, Chao PH, Wang JL. Spinal traction promotes molecular transportation in a simulated degenerative intervertebral disc model. Spine (Phila Pa 1976). 2014;39(9):E550-6.
48. Fields AJ, Ouyang A, Tang X, Lotz JC. Influence of Cartilage Endplate Permeability on Intervertebral Disc Nutrition. ORS 2016 Annual Meeting Paper No 0308;2016.
49. Byvaltsev VA, Kolesnikov SI, Belykh EG, Stepanov IA, Kalinin AA, Bardonova LA et al. Complex Analysis of Diffusion Transport and Microstructure of an Intervertebral Disk. Bull Exp Biol Med. 2017;164(2):223-8.
50. Belykh EG, Kalinin AA, Patel AA, Miller EJ, Bohl MA, Stepanov IA et al. Apparent diffusion coefficient maps in the assessment of surgical patients with lumbar spine degeneration. PLoS One. 2017;12(8):e0183697.

SURGICAL TREATMENT OF LUMBAR DISC HERNIATION IN PREGNANT WOMEN: REPORT OF TWO CASES AND A SYSTEMATIC REVIEW

TRATAMENTO CIRÚRGICO DA HÉRNIA DE DISCO LOMBAR EM GESTANTES: RELATO DE DOIS CASOS E REVISÃO SISTEMÁTICA

TRATAMIENTO QUIRÚRGICO DE LA HERNIA DISCAL LUMBAR EN EMBARAZADAS: INFORME DE DOIS CASOS Y REVISIÓN SISTEMÁTICA

Aleksandr Vladimirovich Krutko[1], Abdugafur Jabborovich Sanginov[1], Aleksey Vladimirovich Peleganchuk[1], Alina Anatolevna Alshevskaya[2], Andrei Vladimirovich Moskalev[2], Vadim Anatolevich Byvaltsev[3]

1. Novosibirsk Research Institute of Traumatology and Orthopaedics, Novosibirsk, Russia.
2. Biostatistics and Clinical Trials Center, Novosibirsk, Russia.
3. Irkutsk State Medical University, Irkutsk, Russia.

ABSTRACT

Objective: To review the surgical treatment of lumbar disc herniation in pregnancy. Methods: We systematically reviewed cases of surgical treatment of pregnant patients with lumbar IVD herniations in accordance with the Cochrane Handbook for Systematic Reviews of Interventions. We searched on electronic databases, including PubMed, Scopus, and Google Scholar, to find relevant articles by keywords. Results: A literature review of 42 cases is presented. Conclusions: The authors' own data and the literature data demonstrate that decompression surgery in pregnancy is effective and safe for both mother and fetus; however, radical surgery (fusion) can lead to very adverse sequelae for the fetus**. *Level of Evidence III; Systematic review[b] of Level III studies.***

Keywords: Pregnancy; Hernia; Diskectomy; Cauda equina; Polyradiculopathy.

RESUMO

Objetivo: Nosso objetivo foi rever o tratamento cirúrgico da hérnia de disco lombar na gravidez. Métodos: Revimos sistematicamente os casos de tratamento cirúrgico de pacientes grávidas com hérnia lombar por DIV, de acordo com o Manual Cochrane para Revisões Sistemáticas de Intervenções. Procuramos, através de bases de dados eletrônicas, incluindo PubMed, Scopus e Google Scholar, encontrar artigos relevantes por palavras-chave. Resultados: Revisão da literatura de 42 casos foi apresentada. Conclusões: Os dados dos próprios autores e os dados da literatura demonstram que a cirurgia de descompressão na gravidez é eficaz e segura tanto para a mãe como para o feto. Entretanto, a cirurgia radical (fusão) pode levar à sequelas muito adversas para o feto. ***Nível de Evidência III; Revisão sistemática[b] de Estudos de Nível III.***

Descritores: *Gravidez; Hérnia; Discotomia; Cauda equina; Polirradiculopatia.*

RESUMEN

Objetivo: Nuestro objetivo fue revisar el tratamiento quirúrgico de la hernia de disco lumbar en el embarazo. Métodos: Revisamos sistemáticamente los casos de tratamiento quirúrgico de pacientes embarazadas con hernias de DIV lumbar de acuerdo con el Manual Cochrane para Revisiones Sistemáticas de Intervenciones. Realizamos búsquedas en bases de datos electrónicas, incluidas PubMed, Scopus y Google Scholar, para encontrar artículos relevantes por palabras clave. Resultados: Se presentó la revisión de la literatura de 42 casos. Conclusiones: Los propios datos de los autores y los datos de la literatura demuestran que la cirugía de descompresión en el embarazo es efectiva y segura tanto para la madre como para el feto; sin embargo, la cirugía radical (fusión) puede conducir a secuelas muy adversas para el feto. ***Nivel de Evidencia III; Revisión sistemática[b] de Estudios de Nivel III.***

Descriptores: *Embarazo; Hernia; Discectomía; Cauda equina; Polirradiculopatía.*

INTRODUCTION

Low back pain in combination with radicular syndromes occurs in more than 50% of pregnant females at more than 20 weeks of gestation.[1] The development of lumbodynia is largely promoted by the biomechanical and hormonal changes typical of pregnancy. The biomechanical mechanism of back pain during pregnancy is associated with an increase in uterus size, an anterior shift of the center of gravity with a compensatory increase in lumbar lordosis, and an increased load on the lower lumbar spine.[2] The hormonal mechanism is associated with the hormone relaxin, which reduces the tone and strength of the musculoskeletal apparatus of the pelvic region. However, the data on this relationship are controversial: although earlier studies have revealed high serum relaxin levels in pregnant females with low back pain,[3] recent publications in this area have indicated an inadequate relationship between the serum relaxin level and the rate of lumbar and pelvic pain.[4,5] Symptomatic lumbar intervertebral disc (IVD) herniation is far less common, approximately one case per 10,000 pregnant females.[6] The risk

Study conducted at the Novosibirsk Research Institute of Traumatology and Orthopaedics (NRITO) n.a. Ya.L. Tsivyan, Novosibirsk, Russia.
Correspondence: Neurosurgery Department of NRITO, Frunze str., 17, Novosibirsk, 630091, Russia. ortho-ped@mail.ru

CC BY

http://dx.doi.org/10.1590/S1808-185120181703193835

Coluna/*Columna.* 2018;17(3):240-8

Received on 04/04/2018 accepted on 07/25/2018

factors for IVD herniation in pregnancy include age, obesity, physical activity, positive history, lumbodynia during menstruation, traumatic injuries, stress factors, male fetus, etc.[1,7,8] In most cases, conservative treatment is sufficient to stop lumbar spine and lower limb pain caused by degenerative changes and herniation of the IVD. In the case of failed conservative treatment or a severe neurological deficit, surgical treatment is used. Publications in recent years have demonstrated the safety of spine surgery during pregnancy in the presence of a well-coordinated team consisting of a neurosurgeon, anesthesiologist, neurologist, and obstetrician-gynecologist,[8-17] which is also confirmed by our experience. During preparation of this manuscript, two reviews of surgical treatment of herniated IVD in pregnant females were published. In an article by Ardaillon et al., 17 articles and 27 cases of microdiscectomy are analyzed.[18] An article by Di Martino et al. reviewed 20 articles and 32 cases of microdiscectomy.[19] However, a number of questions on the choice of optimal approach, time of surgery, and position during surgery are not fully resolved. The purpose of our study was to conduct a systematic review of surgical treatment for herniated IVD in pregnant females to summarize the existing opinions on controversial issues. This paper reviews 30 articles and 46 cases of microdiscectomy, including two cases of our own.

METHODS

This study obtained ethical approval from the Ethics Committee of Irkutsk State Medical University (118/2). All participants gave informed consent before taking part.

We systematically reviewed cases of surgical treatment of pregnant patients with lumbar IVD herniations in accordance with the Cochrane Handbook for Systematic Reviews of Interventions.

We also searched on electronic databases, including PubMed, Scopus, and Google Scholar to find relevant articles. The keywords used were 'pregnant', 'gravid', 'parturient', and 'parous' for pregnancy and 'disk'/'disc' and 'hernia' or 'discectomy'/'diskectomy' for discectomy and hernia of the IVD, as well as additional terms for concomitant conditions ('cauda equina syndrome', 'polyradiculopathy'). The search was performed on the electronic databases PubMed, Scopus, and Google Scholar. We limited the search to the English language, with a cut-off period of articles published between 1990 and 2017. The last search was done at the end of July, 2017. The searches were independently conducted by the three authors, and the list of relevant abstracts was collated. We identified additional case reports from the reference list of included studies. Unpublished and non-peer reviewed data were not considered.

The inclusion criteria were as follows: clinical cases (outcome studies, studies on adult pregnant females, case reports) describing surgical treatment of lumbar IVD herniation in pregnant females, provided that the symptoms developed during pregnancy, and the availability of full text. The exclusion criteria were as follows: studies written in a language other than English, successful therapeutic treatment, reviews, studies on animals and cadavers, *in vitro* studies, technical notes, letters to editors, and articles not specifically reporting outcomes. The three-level selection system was used for the final analysis of full-length articles.

Two authors independently extracted data using a standardized data extraction form. Disagreement was resolved by discussion or consensus with a third party. The corresponding author of a study was contacted to gather any missing information. Information was extracted using special tables designed for the study based on previous reviews. The tables contained the following variables: age, number of previous pregnancies and deliveries, gestational age of symptom onset, surgery time, complications, history of conservative treatment, anesthesia type, surgical position, lesion level, type of surgery, whether the surgery occurred after delivery (Cesarean), disappearance of symptoms during follow-up, and outcome of the pregnancy.

The data analysis focused on descriptive assessment of the extracted information. The small size of the total sample composed of individual case reports prevented statistical analysis using parametric tests and calculation of effect sizes. For this reason, the data are presented as a summary table for all patients. The general trends and patterns were revealed and analyzed.

In the period from 1st January 2005 to 1st December 2015, 67,388 patients with lumbar pains (including 38,087 patients with lumbar IVD herniations) were consulted at the Novosibirsk Research Institute of Traumatology and Orthopedics (NRITO). During the ten-year period, 9,376 patients underwent spine surgery for degenerative IVD disease. Of these, 5,174 patients underwent discectomy for IVD herniation. A total of 257 pregnant females with lumbar pain presented to the NRITO (mainly to determine the type of obstetrics). Of these, two patients underwent discectomy.

RESULTS

Case reports

Case 1. A 36-year-old patient B., second pregnancy, 20 weeks, presented with complaints of pains in the back and lower limbs, numbness in the anogenital region, legs, and feet, and decreased strength in the feet for at least three weeks. The pain intensity in the back and lower limbs was scored 9 by the Visual Analogue Scale (VAS), and 82 by the Oswestry Disability Index (ODI). Neurological status presented decreased strength in the lower limbs to three points, the absence of Achilles and plantar reflexes, hypoesthesia in the S1, S2, and S3 regions, and straight leg raise of 30°. The functions of the pelvic organs were not affected.

MRI examination revealed a L5/S1 herniated IVD on the right. (Figures 1A, 1B) Radiography was not performed due to the teratogenic effect. Because of urgent indications, the patient underwent a L5/S1 microdiscectomy on the right, being placed on her left side on the operating table. Epidural anesthesia was used. There were no intraoperative complications.

In the postoperative period, pain in the lower limbs and numbness in the anogenital area completely alleviated. The patient was discharged from the hospital on the sixth day. Strength and sensitivity in the lower limbs recovered after two weeks. Some minor pain remained in the wound area.

The patient gave birth to a girl at 39 weeks of gestation. The delivery was natural, without complications.

One year after surgery, the patient complained of moderate pain in the right gluteal region (a VAS score of 2). The disability index was 8 (ODI). Figures 2A and 2B show control MRI scans.

The patient again presented to the hospital after 1 month with worsening of pain in the lumbar spine (VAS score of 5) and left lower limb (VAS score of 9) and numbness on the outer surface of the left thigh; the ODI at the time of examination was 78. Weakness of the left foot extensors (a score of 4) and decreased sensitivity in

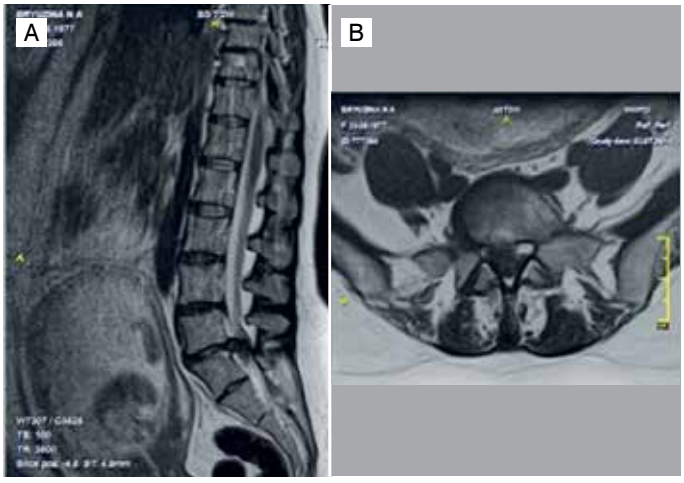

Figure 1. MRI before surgery (L5-S1 LDH). Sagittal (A) and axial (B) planes.

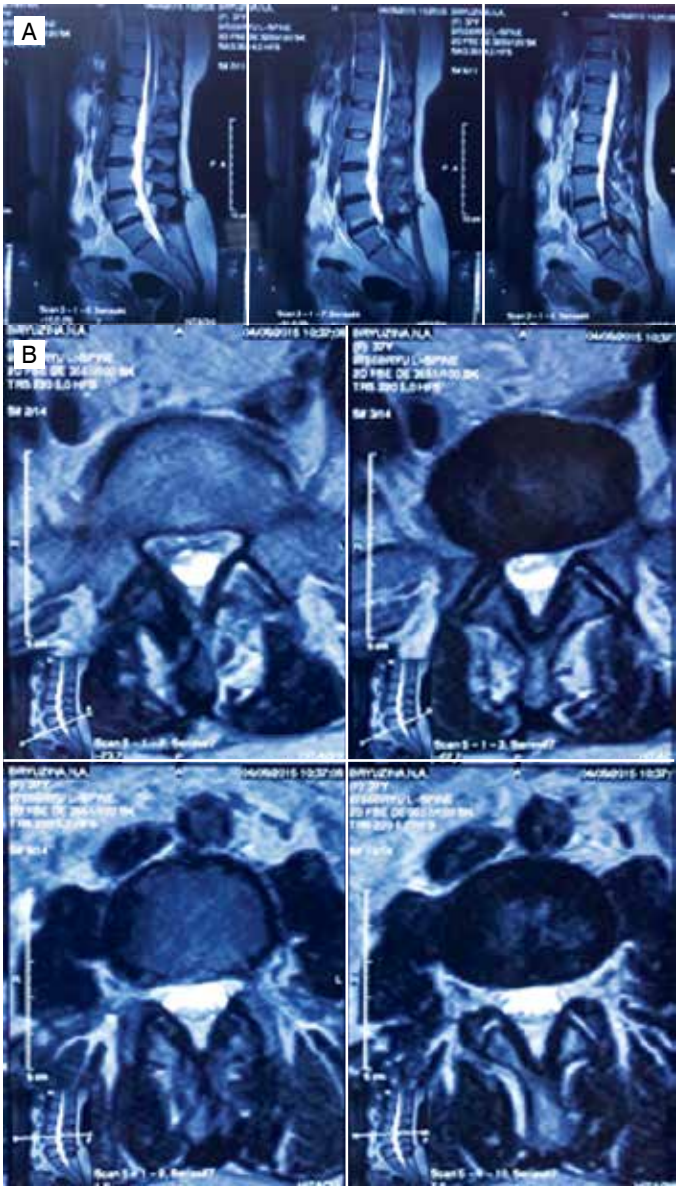

Figure 2. A. MRI, 1 year after surgery. Sagittal plane; B. MRI, 1 year after surgery. Axial plane.

the left S1 area were detected. The functions of the pelvic organs were not affected.

MRI revealed L4/L5 lumbar IVD herniation (Figures 3A, 3B); there were postoperative changes at the L5/S1 level on the right. The patient underwent elective surgery: a L4/L5 microdiscectomy on the left and dynamic interspinous fixation at the L4/L5 level using a DIAM implant.

Immediately after surgery, the lower limb pain stopped (a VAS score of 0), and the strength recovered. Sensation disorders were not detected. On the sixth day after surgery, the patient was discharged to follow-up by a local neurologist.

Case 2. A 31-year-old patient R., second pregnancy, 16 weeks. The first delivery was natural, without complications. The patient presented with intense pain in the lumbar spine and outer surface of the left lower limb. The pain led to walking problems. During the last four weeks, the patient reported worsening of lumbar pain. Severe pain in the left lower limb developed one week ago. Therapy had no effect. The lower limb pain was scored 8 (VAS), and the back pain was scored 8 (VAS). The ODI was 78.

Straight leg raise symptoms and hypoesthesia in the left S1 area were revealed.

MRI findings were as follows: a L5/S1 herniated IVD on the left, L5 retrolisthesis, and a median protrusion of the L4/L5 IVD (Figures 4A, 4B). Radiography was not performed due to the teratogenic effect.

The patient underwent an elective microdiscectomy at the L5/S1 level on the left. The patient was in the right lateral position on the operating table. Epidural anesthesia was used. There were no complications to the fetus.

After surgery, the lower limb pain completely alleviated, and the area of hypoesthesia decreased.

The patient was discharged from the hospital on the seventh day after surgery. The patient gave birth to a girl at 38 weeks of gestation. The baby was delivered by Cesarean section.

A follow-up examination 10 months after surgery revealed moderate discomfort in the lumbar region (a VAS score of 2 for the spine and a VAS score of 1 for the lower limb). The ODI was 12. According to the patient, her spine did not interfere with her care of the child (hold the baby in her arms, walk, etc.).

Control MRI of the lumbar spine (Figures 5A, 5B) showed the condition after removal of the L5/S1 IVD herniation; recurrent median L5/S1 IVD herniation with left-sided lateralization, which caused stenosis of the lateral recess of the spinal canal; L5 retrolisthesis; median protrusion of the L4/L5 IVD; and Modic type I degenerative changes in adjacent parts of the L5 and S1 bodies.

Given the minimal clinical manifestations of recurrent IVD herniation, it was decided to postpone surgical treatment. Potential future surgery for this patient would include 360° circular fusion (screw and interbody fusion of the segment).

Systematic review

A combined search of the databases and an analysis of references yielded 2,542 articles in the databases. We excluded 343 articles published before 1990, and 2,042 papers regarded as irrelevant, i.e. those that described other conditions of the mother/fetus,

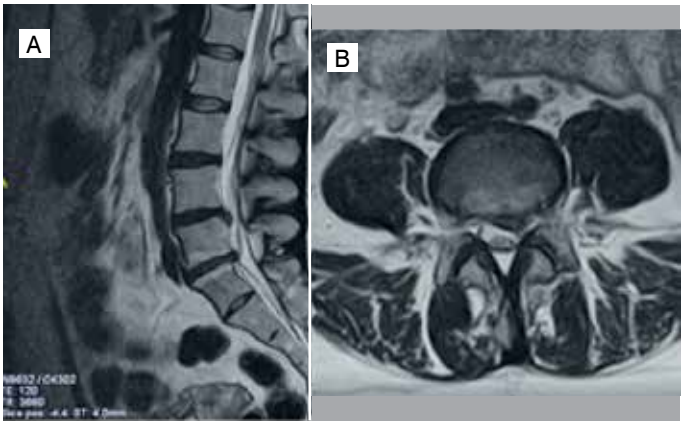

Figure 3. MRI, 13 months after surgery (L4-L5 LDH). Sagittal (A) and axial (B) planes.

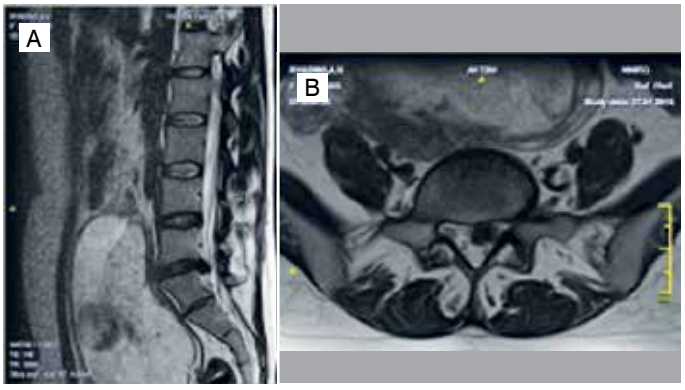

Figure 4. MRI before surgery (L5-S1 LDH). Sagittal (A) and axial (B) planes.

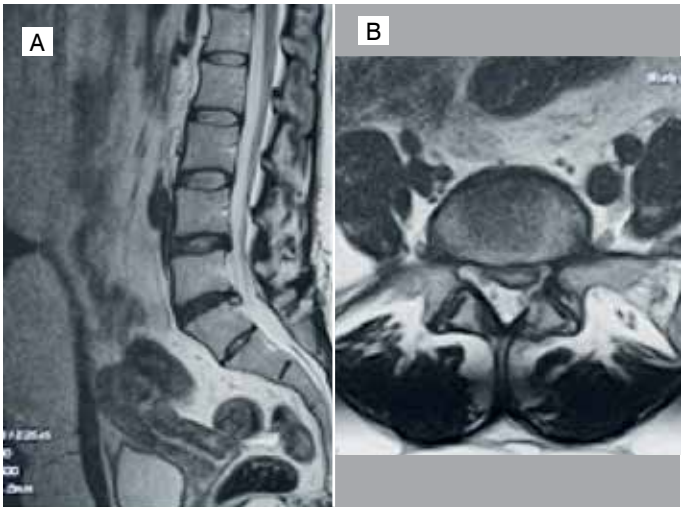

Figure 5. MRI, 10 months after surgery (L5-S1 recurrence LDH). Sagittal (A) and axial (B) planes.

other type of treatment, articles that did not relate to clinical studies, animal studies, articles not original, and duplicate studies. Among 157 potentially relevant articles, 125 were excluded based on the analysis of abstracts: 19 papers did not describe surgical treatment; 8 papers described only anesthesia; in 96 articles, either the patient was not pregnant, or the pregnant patient had no IVD herniation; and two articles did not describe the author's own clinical cases. After a full-text analysis of the remaining 42 articles, 12 articles were excluded as they were inconsistent with the purpose of the study.

Of four articles excluded after the full-text analysis, one described the effect of a previous discectomy on the course of back pain in pregnant females [2012 Beckmann]; in two papers, the need for surgery arose during delivery [2015 Jones and 2008 Chow]; in one paper, the need for surgery arose after delivery [1999 Timothy]. Thus, of the articles identified, 30 were eligible for inclusion; the data of 44 patients were extracted from the articles; along with the author's cases, the total number of patients was 46.

The characteristics of all the identified patients are shown below Table 1.[20-35]

The median age of the females was 32.8 (IQR, 30−36) years. At least, twenty-three (50%) females had a history of at least one pregnancy.

Lumbar IVD herniation at L4/L5, L3/L4, and L5/S1 levels was present in 20, 1, and 25 patients, respectively. IVD herniation at the L3/L4 level developed only in one (2.2%) case. The L5/S1 (25 cases, 54.3%) and L4/L5 (20 cases, 43.5%) levels were more typical. In this case, L4/L5 lumbar IVD herniation was more typical of the 3rd trimester, while L5/S1 lumbar IVD herniation was more typical of the 2nd trimester.

Conservative treatment for a period of one day to five weeks failed to stop the symptoms in at least 29 cases.

Seven (15.2%) patients underwent surgery in the first trimester of pregnancy; 25 (54.3%) patients underwent surgery in the second trimester; and 14 (30.4%) patients underwent surgery in the third trimester; in one (2.2%) case, the authors did not specify the gestational age of surgery. Twenty-two (47.8%) patients underwent surgery in the prone position; 8 (17.4%) patients underwent surgery in the left lateral position; 4 (8.7%) patients underwent surgery in the right lateral position; in 12 (26.1%) patients, the position was not specified. In this case, the prone position was most typical of the second trimester; the left lateral position was equally used in both the second and third trimesters. In three (6.5%) females, delivery was by Cesarean section, followed by a discectomy in the prone position. Among the cases in which anesthesia was specified, general and epidural anesthesias were distributed almost equally (19 and 14 cases, respectively). In 13 cases, the method of anesthesia was not described.

Among the reported cases, we found 4 unfavorable outcomes: one case of abortion due to the use of X-rays during examination and surgery;[36] one case of miscarriage of one fetus in a biparous female after surgery;[37] one case of postoperative wound infection;[18] and one case of deep vein thrombosis of a lower limb in the postoperative period.[38]

In 19 cases (42.2%), the authors noted persistent neurological symptoms at the end of the follow-up period, which manifested as both surgical complications and residual effects of the lesion.

DISCUSSION

Treatment of pregnant females with lumbar IVD herniation requires a multidisciplinary approach. The general principles of conservative treatment are similar to the management of the general population and include bed rest, physiotherapeutic procedures, administration of central analgesics and muscle relaxants, and epidural blockades.[2,39] Restricted physical activity, a reduced vertical load, and a horizontal position with the lower limbs bent at the knee and hip joints helps to reduce pain as it decreases muscle spasms and lumbar lordosis.[40] The capabilities of pharmacological therapy are limited during pregnancy because of toxic effects on the fetus. FDA category A and B drugs are recommended for use.[41] NSAIDs are not advisable during pregnancy because of their side effects. Paracetamol (non-narcotic analgesic, category B) and cyclobenzaprine (muscle relaxant, category B) are primarily used.[42] Opioids may be used in the case of severe pain and failure of non-opioid analgesics. There are reports in the literature of the efficacy of epidural blockades with corticosteroids, but their prolonged use is associated with side effects on the fetus.[43] In most cases, conservative treatment is effective; pain is relieved and has no adverse effect on the course of pregnancy.

Failure of conservative therapy for 6 weeks is an indication for routine examination to identify a substrate of the radicular symptoms. The scope of examination during pregnancy, as well as that of therapy, is somewhat limited due to a potential impact on the developing fetus. Radiographic examination in patients with degenerative IVD disease enables identification of the number and location of vertebrae, range of segment movement of the spinal motion segment, IVD height index, central angle of lordosis, etc. MSCT (CT) scans reveal the condition of bone tissue, anatomical location of the spinal structures, the presence of marginal osteophytes, bone defects, and the shape and condition of the facet joints and joint space. Currently, this is an integral part of preoperative examination. However, X-ray examination and intraoperative control are contraindicated during pregnancy due to the teratogenic effects on the fetus,[44] which limits the choice of surgical treatment for pregnant patients.

MRI of the lumbar spine is the main technique for diagnosis of IVD herniation. Based on an MRI study, the type of herniation, Modic changes in adjacent parts of the vertebral bodies, Pfirrmann IVD degeneration grade, and Pathria and Grogan facet joint degeneration grade are determined. This diagnostic technique has no teratogenic properties, and it is not contraindicated for pregnant females; therefore, MRI is the only technique for objective diagnosis of a morphological substrate of pain in pregnant females.[45]

It should be noted that MRI findings play an important role in predicting the results of surgical treatment of lumbar IVD herniation patients[39] and recurrent IVD herniation.[46] In our 2 cases, the first patient had L5 retrolisthesis and Modic I type changes; the second patient also had L5 retrolisthesis. These signs implied instability of the spinal motion segment. In our opinion, in the case of significant IVD bulging, the presence of direct and indirect signs of instability of the spinal motion segment, tendency of the adjacent vertebra to displacement, Pathria grade IV degeneration of the articular pair, and other factors, decompression-stabilization surgery (360° interbody fusion) is advisable. We believe that this procedure is impossible in pregnant females because of limitations in the preoperative examination and intraoperative radiological monitoring

Table 1. Summarized data of surgical treatment of lumbar disc herniation in pregnancy.

	Age	Pregnancy/ delivery	Gestation age when symptoms developed	Surgery time	Cauda equina syndrome	Conservative treatment	Anesthesia type	Surgical position	Level, surgery	If surgery was after delivery (cesarean)?	Residual symptoms within follow-up
1997 Garmel	34	G4 P2	9 weeks	N/A	Yes	bed rest, ice packs, lumbosacral support, physical therapy, and pain medication	N/A	N/A	L5-S1, LE and DE	No	No
1995 LaBan	**29**	G1 P0	6 weeks	11 weeks	No	5 weeks	N/A	N/A	L5-S1, LE, DE	No	N/A
2008 Han	30	N/A	N/A	11 weeks	No	N/A	Epidural	Prone	L4–L5 and L5–S1, posterior lumbar interbody fusion	No	No
2008 Han	32	N/A	N/A	11 weeks	No	N/A	Epidural	Prone	L4–L5, partial hemiLE, DE	No	No
2007 Curtin	37	G3 P2	<1 week	11 weeks	Yes	Yes	N/A	N/A	L4-L5, lumbar DE and nerve root decompression	No	18 months - persistent paraesthesia down the back of both legs and anesthesia in the saddle area
2014 Speirs	24	G2 P2	15 weeks	15 weeks	Yes	No	General	Prone	L5-S1, DE	No	No
2008 Han	30	N/A	N/A	15 weeks	No	N/A	Epidural	Right lateral decubitus	L5–S1, partial hemiLE, DE	No	No
Author's data	31	G1 P1	4 weeks	16 weeks	No	Yes	Epidural anesthesia	Right lateral	InterLE of L5-S1 on the left, DE	No	10 months – reherniation without need for urgent reoperation
2001 Brown	32	G0 P0	13 weeks	16 weeks	No	Bed rest, analgesics, epidural steroid injection	Epidural	Prone	L5, right LE, partial facetectomy, nerve root decompression; L5–S1, DE	No	10 months - a trace of weakness in the left peroneal muscle group
2004 Vougioukas	36	N/A	N/A	18 weeks	No	N/A	N/A	N/A	L5-S1, nucleotomy	No	No
2006 Abou-Shameh	34	G2 P1	14 weeks	19 weeks	No	4 days - bed rest, routine analgesia	General	Knee/ elbow, with simple side supports	L4-5, right-sided DE	No	No
2003 Reihani-Kermani	26	G0 P0	<16 weeks	20 weeks	Yes	4 weeks - pain medication, exercise plan	N/A	N/A	L4, LE; L3-L4, partial DE	No	3 months - foot drop
2008 Mohapatra	30	G1 P1	<17 weeks	20 weeks	Yes	Yes	General	Prone	L5 and S1, LE; L5-S1, DE	No	7 month – persistent weakness in the feet; incontinent bladder and bowel
2003 Iyilikçi	31	G0 P0	<16 weeks	20 weeks	No	N/A	General (tracheal intubation)	Left lateral	L5-S1, DE	No	No
2001 Brown	31	G0 P0	16 weeks	20 weeks	No	3 weeks - bed rest, two epidural steroid injections, oral steroids, oxycodone, acetaminophen	Epidural	Prone	L5–S1, hemiLE, partial facetectomy, DE	No	15 months - minimal residual hypoesthesia in the right planta
2011 Lee	32	G? P>0	12 weeks	20 weeks	No	2 months	General	Left lateral	L3, right extended medial facetectomy and adhesiolysis; L4-L5, DE	No	No
Author's experience	36	G1 P1	<17 weeks	20 weeks	Yes	Yes	Epidural	Left lateral	InterLE of L5-S1 on the right, DE	No	1 year – moderate discomfort in the right gluteal region
1995 LaBan	36	G3 P1	20 weeks	20 weeks	Yes	No	N/A	N/A	L5-S1, lumbar LE with DE	No	No
2001 Brown	41	G0 P0	14 weeks	20 weeks	Yes	Yes	Epidural	Prone	L5–S1, hemiLE, partial facetectomy, DE	No	4 years - persistent hypoesthesia on the right side of the perineum necessitating urethral dilatation at 3-month intervals; urinary stress incontinence; constipation; 50% improvement in bowel function

	Age	Pregnancy/ delivery	Gestation age when symptoms developed	Surgery time	Cauda equina syndrome	Conservative treatment	Anesthesia type	Surgical position	Level, surgery	If surgery was after delivery (cesarean)?	Residual symptoms within follow-up
1997 Garmel	29	G0 P0	23 weeks	24 weeks	Yes	2 days pain medication, range-of-motion exercises, and a walker	N/A	N/A	L5-S1, DE	No	No
2012 Hakan	34	G2 P?	25 weeks	25 weeks	Yes	No	General	Prone	L5-S1 right partial hemilaminotomy, microDE	No	6-month - bowel and bladder were nearly normal, reduced sensation in the sacral area was continuing
2008 Han	34	N/A	N/A	26 weeks	No	N/A	Epidural	Right lateral decubitus	L4–L5, partial hemiLE, DE	No	No
2015 Martel	27	G1 P0	26 weeks	28 weeks	No	6 days of - dexamethasone	General	Prone	L4-L5, left hemiLE, medial facetectomy, microDE, foraminotomy	No	No
1997 Garmel	28	G5 P1	29 weeks	30 weeks	Yes	4 days of pain medication	N/A	N/A	L5-S1, LE and DE	No	3 months - minimal foot numbness
2007 Kim	30	G0 P0	22 weeks	30 weeks	Yes	Yes	Regional	Prone	L4-L5, DE	No	3 months - persistent hypoesthesia and slightly weakened dorsiflexion on the left side
2008 Han	33	N/A	N/A	30 weeks	No	N/A	Epidural	Left lateral decubitus	L4–L5, partial hemiLE, DE	No	No
2008 Han	30	N/A	N/A	32 weeks	No	N/A	Epidural	Left lateral decubitus	L4–L5, partial hemiLE, DE	No	No
1998 Fahy	32	G3 P?	30 weeks	32 weeks	Yes	No	General	Prone	L4-L5, DE	No	7 months - slight residual weakness in the left anterior tibialis
1998 Fahy	31	N/A	29 weeks	33 weeks	No	4 weeks - analgesics, oral morphine, transcutaneous nerve stimulation	General	Prone	L4-L5, left mini-DE	No	No
2006 Kathirgamanathan	34	G0 P0	33 weeks	33 weeks	Yes	No	General	Left lateral position	L4-L5, DE; L5, nerve root decompression.	No	No
2014 Ochi	33	N/A	32 weeks	Immediately after CS at 34th week	No	Yes, 2 weeks Patient received physical therapy and acetaminophen for pain relief	Epidural	Prone	(34 weeks) L4-L5, left DE; (after 6 days) L4-L5, right DE	Yes	18 months - numbness and slightly weakened dorsiflexion in the left extremity
2004 Vougioukas	30	G0 P0	35 weeks	35 weeks	No	1 day - analgesics, immobilization	N/A	Left lateral decubitus	L4-L5, partial left DE, hemiLE	No	No
2008 Gupta	37	G2 P1	35 weeks	Immediately after CS at 35th week	Yes	No	General	Prone	L5-S1, DE	Yes	No
2015 Geftler	33	Gmulti Pmulti	36 weeks	Immediately after CS at 36th week	Yes	No	General	Prone	L4-L5 partial laminoforaminotomy, DE	Yes	No
1999 Timothy	37	G0 P0	33 weeks	4 weeks after 38 weeks uncomplicated ventouse delivery	Yes	Yes	N\A	N\A	L5-S1, DE	Yes	2 years - gained some anal sphincter control; still uses intermittent catheterization to void urine; absent sensation in the perineal area with associated sexual dysfunction

CS – cesarean section; DE – discectomy; LE – laminectomy.

of the implant position in the spine.[36] Therefore, in the case of conservative therapy failure in pregnant females with IVD herniations, the only method of choice is decompression surgery without X-ray assistance (e.g., transforaminal sequestrectomy), which was used in our patients.

Surgery is not contraindicated in any period of pregnancy,[20] but it requires maximum concentration of the surgical team. The patient's position on the operating table and the method of anesthesia used are of particular importance. In relation to the first, a review article by H. Ardaillon et al. analyzed data from 17 authors from 27 cases of microdiscectomy in pregnant females, and demonstrated that the characteristics of patient position on the operating table depended on the gestational age. In patients with a gestational age of up to 25 weeks, the position on the operating table did not differ from that in the general population. At more than 34 weeks, they recommend Cesarean section followed by microdiscectomy during a single anesthesia. Difficulties may arise at a gestational age of 25–34 weeks. In this period, the left side position is recommended, to prevent damage to the fetus and low blood pressure due to compression of the inferior vena cava.[18]

The indications for elective or urgent surgery of pregnant lumbar IVD herniation patients do not differ from those for other patients. In the case of intractable radicular symptoms, routine surgical procedures are used; urgent surgery is indicated for neurological deficit progression and cauda equina syndrome.

Some authors suggest surgical treatment of spine pathology after childbirth. For example, Timothy et al. described surgery for a herniated IVD, which was performed 4 weeks after childbirth. However, untimely treatment of cauda equina syndrome (which occurred in one patient in our case) leads to severe neurological complications and disability of the patient. In a review of the literature, we found two cases describing untimely diagnosis of cauda equina syndrome in pregnant females. A neurological deficit persisted in the patients for a follow-up period of up to 24 months.[10,47] Chow et al. presented a case of cauda equina syndrome in a pregnant patient after Cesarean section. The pregnant patient at a gestational age of 36 weeks presented with pain and numbness in the right lower limb and slight incontinence. The patient also suffered from diabetes and obesity. Given the neurological deficit and concomitant diseases, Cesarean section was performed. The patient developed persistent dysfunction of the pelvic organs in the form of bladder and bowel incontinence 36 h after surgery. Also, numbness in the perineum was present in the neurological status. MRI of the lumbar spine showed a sequestered L5–S1 IVD with caudal displacement. The patient underwent urgent surgery, including S1 laminectomy and removal of IVD herniation. Bladder incontinence persisted three weeks after surgery.[13] In our opinion, MRI of the lumbar spine and further treatment, with allowance for the results of the examination at admission, when the radicular syndrome first developed, might prevent the development of a persistent neurological deficit in the described cases. This publication demonstrates the importance of timely diagnosis and surgical treatment, and we agree with the authors that cauda equina syndrome requires urgent surgery, and its diagnosis in pregnant females requires a thorough examination, including the patient's history, and differential diagnosis because of potential urogenital disorders. In the present review, an approach combining Cesarean section and removal of IVD herniation during a single anesthesia is used in three cases[8,19,48] which, according to the authors, is an optimal treatment for pregnant IVD herniation patients. It should also be noted that Cesarean section can only be used in late pregnancy, while the waiting until natural delivery can lead to severe neurological deficit and (or) pain syndrome.

One of the main components of intraoperative management of pregnant patients is monitoring of the cardiac fetal activity. According to some authors, intraoperative monitoring of fetal heartbeat at a gestational age of up to 20 weeks is not indicated; starting with the 23rd week, this procedure is mandatory; monitoring between 20 and 23 weeks is controversial.[49] Given the influence of general anesthesia on fetal heart activity, as well as inadequate development of the fetal cardiovascular system, the data obtained at up to 28 weeks of gestation are insufficient and unreliable. We operated on pregnant females at a gestation of less than 20 weeks, and we considered it unreasonable to intraoperatively monitor fetal heartbeats.[49-51] Many physiological parameters are disturbed during pregnancy, particularly by the end of the second trimester. The stressful condition before surgery also negatively affects the functional state of the pregnant patient. During pregnancy, there is an increase in the volume of circulating blood, an acceleration of glomerular filtration, and an increase in the tissue oxygen demand with a simultaneous reduction in the functional residual capacity of the lungs. These changes require competent management of anesthesia to avoid potential episodes of hypoxemia, hypotension, acidosis, hypo- or hyperventilation, and other changes in metabolism and pharmacodynamics.[52] A significant change in minute ventilation of the lungs and functional residual capacity in the last two trimesters of pregnancy will lead to an increase in the pregnant female's sensitivity to anesthetics.[53]

Epidural and general anesthesias are not contraindicated in any period of pregnancy.[9] In the literature, there is no evidence of the effect of anesthesia during pregnancy on congenital anomalies, premature birth, and perinatal mortality.[53,54] The main goals of anesthetic care during pregnancy are to ensure adequate blood pressure, carefully monitor respiratory function, and prevent hypertonia of the sympathetic nervous system, fetal asphyxia, and premature birth. Epidural anesthesia may be more preferable than general anesthesia for reducing the risk of pulmonary aspiration and unsuccessful intubation, and may also minimize the effect of medications on the fetus. Some authors prefer general anesthesia because of its minimal hypotensive action and rapid, and reliable effect.[9,54]

In the literature analyzed, intraoperative complications were not documented. In two cases, abortion was reported. Han et al. operated on a 30-year-old pregnant female at 11 weeks gestation. Due to the large size of the IVD herniation, the patient underwent transpedicular fixation with posterior interbody fusion. During examination and surgery, X-ray was used; for this reason, the patient underwent termination of pregnancy after surgery because of a high risk of fetal anomalies.[36] Speirs et al. operated on a pregnant patient at 15 weeks of gestation for lumbar IVD herniations; decompression surgery was performed, with good clinical results. According to the postoperative ultrasound, there were no fetal abnormalities. But later, it turned out that the pregnant patient was carrying twins, and a spontaneous miscarriage of one fetus occurred. The second fetus developed normally, and the patient gave birth to a healthy child at 39 weeks.[37] In this case, it is difficult to establish the degree of influence of the surgery on the course of the pregnancy because according to the ultrasound, the pregnancy was preserved immediately after surgery. In pregnant females, as in the general population, complications can develop in the postoperative period. The rate of complications in pregnant patients is no different from that of the general population. Ardaillon et al. detected infection of a postoperative wound after microdiscectomy in a pregnant patient. A 39-year-old patient at 17 weeks of gestation underwent surgery under general anesthesia in the prone position. On the 14th day after surgery, wound dehiscence was revealed; a bacteriological study of wound fluid detected the growth of *Staphylococcus aureus*. A re-operation was performed also in the prone position, with revision, sanitation of the wound, and resuturing. Subsequent pregnancy and delivery were on time, and without complications.[18] Garmel et al. described the development of deep vein thrombosis after microdiscectomy in a 34-year-old female at 9 weeks of gestation. The patient underwent anticoagulant therapy with a positive effect; delivery was on time and without complications.[37] In pregnant females with IVD herniation, complications with persistent disabling effects arise, as indicated above, in the case of untimely diagnosis of cauda equina syndrome.

There are no data in the literature on the rate of recurrent IVD herniation after a microdiscectomy performed during pregnancy. Ochi et al. described a case of recurrent IVD herniation in the early postoperative period. A patient at 34 weeks gestation underwent a L4/L5 microdiscectomy on the left immediately after Cesarean section. Surgery was performed under epidural anesthesia, in the prone position. Radicular symptoms on the contralateral side developed in the early postoperative period. MRI of the lumbar spine revealed IVD herniation at L4/L5 on the right. Six days after surgery, the patient underwent re-operation, and the L4/L5 herniated IVD on the right was removed.[50] In our series of two patients, one had recurrence of pain caused by IVD herniation at L4/L5 on the left 13 months after surgery (surgery at L5/S1 on the right). MRI of the lumbar spine in the second patient revealed asymptomatic recurrent IVD herniation at the operated level, on the ipsilateral side, 10 months after surgery. Given the lack of clinical manifestations of IVD herniation, the patient follow-up was continued. According to the MRI findings, this patient was initially detected as having L5 retrolisthesis and, if additional data (radiography) had been available, our plan for surgical treatment

might have been changed; perhaps, we would have suggested that the patient undergo herniated IVD removal with subsequent screw and interbody fusion; however, we refused preoperative radiography of the lumbar spine and intraoperative X-ray due to potential harm to the fetus.

In our patients, a traditional microdiscectomy was performed, without any surgical care for the fetus. The patients gave birth to healthy children.

Endoscopic removal of IVD herniation in pregnant females has been reported in the literature. A paper by Eichholz et al. presented two cases of endoscopic microdiscectomy in pregnant patients. In the first case, surgery was performed at 15 weeks of gestation in the prone position on the Wilson stand. In the second case, surgery was performed at 27 weeks of gestation in the right lateral position, with intraoperative fetal monitoring. In both cases, the result of surgery was favorable. According to the authors, the advantages of this technique include minimal postoperative pain, less use of analgesics, and faster recovery.[11] Kim et al. also described a case of endoscopic microdiscectomy in a pregnant female with cauda equina syndrome. Emergency surgery was performed at 30 weeks of gestation, without complications. Intraoperative monitoring of the fetal heart activity was carried out. In the early postoperative period, pain relief was achieved in the lower limbs. A follow-up examination after 3 months revealed hypoesthesia and slight weakness of the left foot dorsiflexion.[12] However, the endoscopic surgical technique is only a method of intraoperative visualization, and the use of endoscopic transforaminal sequestrectomy requires mainly X-ray intraoperative control, which limits its use in these patients.

CONCLUSIONS

Decompression surgery in pregnant females with lumbar IVD herniation, when adhering to the multidisciplinary approach, is an effective and safe procedure for both the mother and the fetus. The diagnosis of spinal motion segment pathology and its surgical treatment in pregnant patients are characterized by a number of features and limitations and, in some cases, cannot be cured radically during pregnancy. If a neurological deficit caused by IVD herniation develops, decompression surgery should be performed as soon as possible; Cesarean section and removal of a herniated IVD can be performed under a single anesthesia. Waiting for natural delivery is inadvisable.

All authors declare no potential conflict of interest related to this article.

CONTRIBUTION OF THE AUTHORS: Each author made significant individual contributions to this manuscript. AVK (0000-0002-2570-3066)*, AJS (0000-0002-4744-4077)* and AVP (0000-0002-4588-428X)* were the main contributors in the drafting of the manuscript. AVK, AJS and AVP performed the surgery, followed up the patients and gathered clinical data. AAA (0000-0002-7307-4524)* and AVM (0000-0002-6711-3822)* evaluated the data from the statistical analysis. AJS, AVK and VAB (0000-0003-4349-7101) performed the literature search and review of the manuscript, and contributed to the intellectual concept of the study. *ORCID (Open Researcher and Contributor ID).

REFERENCES

1. Ansari NN, Hasson S, Naghdi S, Keyhani S, Jalaie S. Low back pain during pregnancy in Iranian women: prevalence and risk factors. Physiother Theory Pract. 2010;26(1):40–8.
2. Bhardwaj A, Nagandla K. Musculoskeletal symptoms and orthopaedic complications in pregnancy: pathophysiology, diagnostic approaches and modern management. Postgrad Med J. 2014;90(1066):450-60.
3. Ritchie JR. Orthopedic considerations during pregnancy. Clin Obstet Gynecol. 2003;46(2):456–66.
4. MacLennan AH, Nicolson R, Green RC, Bath M. Serum relaxin and pelvic pain of pregnancy. Lancet. 1986;2(8501):243–5.
5. Marnach ML, Ramin KD, Ramsey PS, Song SW, Stensland JJ, An KN. Characterization of the relationship between joint laxity and maternal hormones in pregnancy. Obstet Gynecol. 2003;101(2):331–5.
6. Ostgaard HC, Anderson GB, Karlson K. Prevalence of back pain in pregnancy. Spine (Phila Pa 1976). 1991;16(5):549-52.
7. LaBan MM, Viola S, Williams DA, Wang AM. Magnetic resonance imaging of the lumbar herniated disc in pregnancy. Am J Phys Med Rehabil. 1995;74(1):59-61.
8. Aldabe D, Ribeiro D, Milosavljevic S, Dawn Bussey M. Pregnancy-related pelvic girdle pain and its relationship with relaxin levels during pregnancy: a systematic review. Eur Spine J. 2012;21(9):1769–76.
9. Iyilikc IL, Erbayraktar S, Tural AN, Celik M, Sannav S. Anesthetic management of lumbar discectomy in a pregnant patient. J Anesth. 2004;18(1):45–7.
10. Mohapatra RN, Patra RK. Cauda Equina Syndrome in Pregnancy Due to Disc Prolapse. JIACM. 2008;9(2):140-2.
11. Eichholz MK, O´Toole J, Eichholz AC, Fessler R. Minimally invasive lumbar microendoscopic discectomy in the pregnant patient: Report of two cases. Pan Arab Journal of Neurosurgery. 2010;14(1).
12. Kim HS, Kim SW, Lee SM, Shin H. Endoscopic discectomy for the cauda equina syndrome during third trimester of pregnancy. J Korean Neurosurg Soc. 2007;42(5):419–20.
13. Chow J, Chen K, Sen R, Stanford R, Lowe S. Cauda equina syndrome post-caesarean section. Aust N Z J Obstet Gynaecol. 2008;48(2):218–20.
14. Gupta P, Gurumurthy M, Gangineni K, Anarabasu A, Keay SD. Acute presentation of cauda equina syndrome in the third trimester of pregnancy. Eur J Obstet Gynecol Reprod Biol. 2008;140(2):279-81.
15. Abou-Shameh MA, Dosani D, Gopal S, McLaren AG. Lumbar discectomy in pregnancy. Int J Gynaecol Obstet. 2006;92(2):167–9.
16. Hayakawa K, Mizutani J, Suzuki N, Haas C, Kondo A, Otsuka S et al. Surgical Management of the Pregnant Patient With Lumbar Disc Herniation in the Latter Stage of the Second Trimester. Spine (Phila Pa 1976). 2017;42(3):E186-9.
17. Reihani-Kermani H. Cauda equina syndrome in pregnancy. Archives of Iranian medicine. 2003;6(2):146-8.
18. Ardaillon H, Laviv Y, Arle JE, Kasper EM. Lumbar disk herniation during pregnancy: a review on general management and timing of surgery. Acta Neurochir (Wien). 2017.
19. Di Martino A, Russo F, Denaro L, DenaroV. How to treat lumbar disc herniation in pregnancy? A systematic review on current standards. Eur Spine J. 2017;26(Suppl 4):496-504.
20. Brown MD, Levi AD. Surgery for lumbar disc herniation during pregnancy. Spine (Phila Pa 1976).2001;26(4):440–3.
21. Speirs E, Wiles M, Bacon A, Radley S. Positioning a proned patient with cauda equina syndrome who presents at 15 weeks gestation: a case report. F1000Res. 2014;3:117.
22. Al-areibi A, Coveney L, Singh S, Katsiris S. Case report: anesthetic management for sequential Cesarean delivery and laminectomy. Can J Anaesth. 2007;54(6):471–4.

23. Kathirgamanathan A, Jardine AD, Levy DM, Grevitt MP. Lumbar disc surgery in the third trimester – with the fetus in utero. Int J Obstet Anesth 2006;15(2):181–2.
24. Vougioukas VI, Kyroussis G, Gläsker S, Tatagiba M, Scheufler KM. Neurosurgical interventions during pregnancy and the puerperium: clinical considerations and management. Acta Neurochir (Wien). 2004;146(12):1287–91.
25. Hakan T. Lumbar disk herniation presented with cauda equina syndrome in a pregnant woman. J Neurosci Rural Pract. 2012;3(2):197–9.
26. Martel CG, Volpi-Abadie J, Ural K. Anesthetic management of the parturient for lumbar disc surgery in the prone position. Ochsner J. 2015;15(3):259–61.
27. Fahy UM, Oni M, Findlay D, Sell P. Surgical management of herniated lumbar disc in pregnancy. J Obstet Gynaecol. 1998;18(6):544–5.
28. O'Laughlin SJ, Kokosinski E. Cauda equina syndrome in a pregnant woman referred to physical therapy for low back pain. J Orthop Sports Phys Ther. 2008;38(11):721.
29. Brown MD, Brookfield KF. Lumbar disc excision and cesarean delivery during the same anesthesia. A case report. J Bone Joint Surg Am. 2004;86-A(9):2030–2.
30. Kanas M, Kunzle H, Martins DE, Kirsch LA, Puertas EB, Wajchenberg M. Diskectomy during Pregnancy: Case Report and Review of the Literature. Global Spine J. 2015;5(2):130-4.
31. Ashkan K, Casey AT, Powell M, Crockard HA. Back pain during pregnancy and after childbirth: an unusual cause not to miss. J R Soc Med. 1998;91(2):88–90.
32. Lee JM, Han IH, Moon SH, Choi BK. Surgery for Recurrent Lumbar Disc Herniation During Pregnancy: A Case Report. Korean J Spine. 2011;8(4):304–6.
33. Anton Capitan B, Malillos Tóran M. The cauda equina syndrome in pregnant woman with a massive disc herniation. Rev Esp Cir Ortop Traumatol. 2017;61(1):63-5.
34. Jones CS, Patel S, Griffthis-Jones W, Stokes OM. Presentation of cauda equina syndrome during labour. BMJ Case Rep. 2015;18;2015.
35. Naimer SA, Carni A. [Safe quadruplet gestation following peripartum discectomy for massive disc prolapse]. Harefuah. 2014;153(1):6-7.
36. Ray JG, Vermeulen MJ, Bharatha A, Montanera WJ, Park AL. Association Between MRI Exposure During Pregnancy and Fetal and Childhood Outcomes. JAMA. 2016;316(9):952–61.
37. Garmel SH, Guzelian GA, D'Alton JG, D'Alton ME. Lumbar disk disease in pregnancy. Obstet Gynecol. 1997;89(5 Pt 2):821–2.
38. Han IH, Kuh SU, Kim JH, Chin DK, Kim KS, Yoon YS et al. Clinical approach and surgical strategy for spinal diseases in pregnant women: a report of ten cases. Spine (Phila Pa 1976). 2008;33(17):E614–9.
39. Alaeldin A, Darwich, MD, Sudhir A. Diwan, MD. Management of back pain in pregnancy. Techniques in Regional Anesthesia and Pain Management. 2009;13:251-4.
40. Jacobson H. Protecting the back during pregnancy. AAOHN J. 1991;39:286–91.
41. Briggs GC, Freeman RK, Yaffe SJ. A Reference Guide to Fetal and Neonatal Risk: Drugs in Pregnancy and Lactation (ed 7). Philadelphia: Lippincott Williams & Wilkins, 1990.
42. Borg-Stein J, Dugan S, Gruber J. Musculoskeletal aspects of pregnancy. Am J Phys Med Rehabil. 2005;84(3):180-92.
43. Mariotti V, Marconi AM, Pardi G. Undesired effects of steroids during pregnancy. J Matern Fetal Neonatal Med. 2004;16 (Suppl 2):5–7.
44. De Santis M, Di Gianantonio E, Straface G, Cavaliere AF, Caruso A, Schiavon F et al. Ionizing radiations in pregnancy and teratogenesis: a review of literature. Reprod Toxicol. 2005;20(3):323–9.
45. Goodman S. Anesthesia for nonobstetric surgery in the pregnant patient. Semin Perinatol. 2002;26(2):136-45.
46. Belykh E, Krutko AV, Baykov ES, Giers MB, Preul MC, Byvaltsev VA. Preoperative estimation of disc herniation recurrence after microdiscectomy: predictive value of a multivariate model based on radiographic parameters. Spine J. 2016;17(3):390-400.
47. Timothy J, Anthony R, Tyagi A, Porter D, van Hille PT. A case of delayed diagnosis of the cauda equina syndrome in pregnancy. Aust N Z J Obstet Gynaecol. 1999;39(2):260–1.
48. Geftler A, Sasson A, Shelef I, Perry ZH, Atar D. Cauda equina syndrome in a 36 week gravida patient. Isr Med Assoc J. 2015;17(8):522–3.
49. Katz JD, Hook R, Barash PG. Fetal heart rate monitoring in pregnant patients undergoing surgery. Am J Obstet Gynecol. 1976;125(2):267–9.
50. Ochi H, Ohno R, Kubota M, Hanyu R, Sakai K, Sugawara Y et al. Case report: The operation for the lumbar disk herniation just after cesarean delivery in the third trimester of pregnancy. Int J Surg Case Rep. 2014;5(12):1178–82.
51. Biehl DR. Foetal monitoring during surgery unrelated to pregnancy. Can Anaesth Soc J. 1985;32(5):455-9.
52. Chestnut DH. Nonobstetric Surgery During Pregnancy. Yearb Anesthesiol Pain Manag. 2012:335–6.
53. Glosten B. Anesthesia for obstetrics. In: Miller RD (ed) Anesthesia. New York: Churchill Livingstone; 2000. p. 2025 68.
54. Morgan GE, Mikhail SM, Murray JM. Clinical anesthesiology. New York: McGraw-Hill; 2002. p. 819–846.